

Abnormal uterine bleeding induced by glucocorticoid treatment for pemphigus

Case series and proposed treatment algorithm

Xiaobo Luo, DDS, PhD, Hui Feng, DDS, MD, Lu Jiang, DDS, PhD, Qianming Chen, DDS, PhD.

ABSTRACT

إن هرمون القشرية السكرية هو الخيار الأول لعلاج الفقاع، يعد نزيف الرحم غير الطبيعي أحد الآثار النادرة لعلاج القشرانيات السكرية الذي عادة ما يظهر على شكل نزيف رحم مفرط وغير طبيعي وهو ما يحفز استخدام النظامي أو الموضعي للقشرانيات السكرية، وصنفا 3 حالات لمرضى مصابين بالفقاع عند استخدام هرمون القشرية السكرية مما أدى إلى نزيف رحم غير الطبيعي ومن المهم التنويه عن اختلاف وضع العلاج بهرمون القشرية السكرية وبدايته ومدته بين المرضى. اقترحنا العلاج الآتي لنزيف الرحم المفرط الذي يلي العلاج بهرمون القشرية السكرية: (1) إجراء فحص بدني وفحص أمراض النساء لاستبعاد الأمراض الأمراض العضوية الأخرى، (2) العلاج بهرمون القشرية السكرية، (3) في حال استمرار نزيف الرحم غير الطبيعي فيجب تغيير طريقة أخذ هرمون القشرية السكرية، (4) إذا استمر نزيف الرحم غير الطبيعي فيجب إيقاف هرمون القشرية السكرية تماما مع تغيير طريقة العلاجات.

Glucocorticoids are the first-line treatment option for pemphigus. Moreover, abnormal uterine bleeding (AUB) is a rarely reported side effect of glucocorticoid treatment that usually manifests as abnormal and excessive endometrial bleeding; in fact, AUB can be induced by the systemic or topical application of glucocorticoids. In the present report, we describe the cases of 3 patients with pemphigus who developed AUB following glucocorticoid administration. It is important to note that the administration mode of glucocorticoids, and the onset time and duration of AUB differed among these patients. Thus, we propose the following treatment algorithm for AUB following glucocorticoid administration: 1. perform a gynecological and physical examination to exclude organic diseases. 2. continue glucocorticoid treatment. 3. if AUB persists, change the mode of administration of glucocorticoids. 4. if AUB still persists, despite these measures, completely withdraw treatment with glucocorticoids and use non-glucocorticoid treatments.

Saudi Med J 2016; Vol. 37 (9): 1025-1028

doi: 10.15537/smj.2016.9.14929

From the Department of Oral Medicine, State Key Laboratory of Oral Diseases, West China Hospital of Stomatology, Sichuan University, Chengdu, China.

Received 9th March 2016. Accepted 10th June 2016.

Address correspondence and reprint request to: Dr. Lu Jiang, Department of Oral Medicine, State Key Laboratory of Oral Diseases, West China Hospital of Stomatology, Sichuan University, Chengdu, China. E-mail: jianglu@scu.edu.cn

Glucocorticoids are recognized as the first-line treatment option for pemphigus.^{1,2} Although the efficacy of glucocorticoids is significant for this condition, their long-term use may lead to side effects, such as gastrointestinal ulcers, diabetes, and hypertension.³ In addition to these common side effects, abnormal uterine bleeding (AUB) may also rarely develop. Abnormal uterine bleeding is defined as the disturbance of the regularity, frequency, duration, or volume of menstrual flow. It may have physiological, pathological, or pharmacological causes.⁴⁻⁷ Thus far, only few cases of AUB following glucocorticoid treatment have been reported; moreover, information on the treatment modality for pemphigus after the development of AUB is scarce.⁴⁻⁶ Over the past 3 years, we have treated approximately 3000 pemphigus and 800 pemphigoid patients with glucocorticoids, and

Disclosure. Authors have no conflict of interests, and the work was not supported or funded by any drug company. This case report was supported by the National Natural Science Foundation of China (No. 81270040), and New Century Talents Support Program of Ministry of Education (NCET-12-0378), Beijing, China.

only 3 patients with *pemphigus vulgaris* (PV) developed AUB. At our clinic, the incidence of AUB following glucocorticoid treatment among pemphigus and pemphigoid patients is approximately 0.1% per year. In the present report, we describe the cases of 3 patients with AUB and propose an algorithm for treating AUB induced by glucocorticoid application.

Case Report. Patient 1. A 40-year-old woman with a 3-month history of red, peeling, and painful gingival erosions was referred to our clinic. On the basis of results of intraoral examinations, laboratory tests, and histopathological and direct immunofluorescence assays, a definitive diagnosis of oral PV was made (Figure 1 A, C-E). According to the Japanese guidelines for pemphigus management, an initial dose of 0.5 mg/kg of glucocorticoids is recommended for pemphigus merely involving the oral mucosa, and the dose could be upregulated from 0.5 to 1 mg/kg depending on the lesion extent and disease severity.⁸ Therefore, the patient (body weight: 50 kg) was treated with oral glucocorticoids

(prednisone acetate tablets, 25 mg, once daily), combined with immunosuppressants (thalidomide, 75 mg, once daily) and topical glucocorticoid application (dexamethasone paste, 0.05 mg/mL, 3 times daily). After 3 weeks, all the original lesions began to heal without the appearance of any new lesions. However, the patient complained of prolonged (>10 days compared with her average) and heavy menstrual flow during the treatment. These symptoms disappeared immediately after she discontinued prednisone. The patient took only medications that we had prescribed and had previously experienced regular menstrual cycles and volume. This was her first experience of abnormally excessive uterine bleeding. A gynecologist and physician were consulted to exclude organic diseases that may cause uterine bleeding. No related gynecological diseases, bleeding disorders, or systemic diseases were detected. Hence, a diagnosis of AUB was made. As the oral PV could not be well controlled without the use of oral glucocorticoid treatment, the administration of oral prednisone was reattempted (prednisone acetate

Table 1 - Detailed information of patients who developed AUB following oral or topical application of glucocorticoids.

Patient history	Patient 1	Patient 2	Patient 3
<i>Variables</i>			
Age, years/gender	40/Female	30/Female	36/Female
Menopause status	Premenopausal	Premenopausal	Premenopausal
Menstruation before treatment	Normal	Normal	Normal
Diagnosis	PV	PV	PV
PMHx/PSHx	Chronic gastritis	No	No
Medications	Prednisone Thalidomide (75 mg/d) Dexamethasone paste (0.05 mg/ml)	Prednisone	Thalidomide (75 mg/d)
Dosage of glucocorticoids	Prednisone (25 mg/d, first time) Prednisone (40 mg/d, second time)	Prednisone (40 mg/d)	-
Procedure	-	-	Intralesional injection
Procedural medications	-	-	Betamethasone (0.7 mg/w)
<i>Follow Up</i>			
1. Timing of AUB occurrence after glucocorticoid use	Overlapping with the menstrual period (first time) On the seventh day (second time)	On the tenth day	On the fifth day
2. Duration of AUB	Menstrual flow lasted for 10 more days (first time) One week (second time)	One week	5 days
3. When did AUB disappear?	After withdrawal of oral glucocorticoid treatment	Spontaneously without withdrawal of oral glucocorticoid treatments	After withdrawal of glucocorticoid treatment
4. Treatment strategy	Immunosuppressant and topical application of glucocorticoids	Oral glucocorticoids	Immunosuppressant
5. Outcome of AUB	Remission and no recurrence	Remission and no recurrence	Remission and no recurrence
PV - <i>pemphigus vulgaris</i> , PMHx - past medical history, PSHx - past surgical history, AUB - abnormal uterine bleeding			

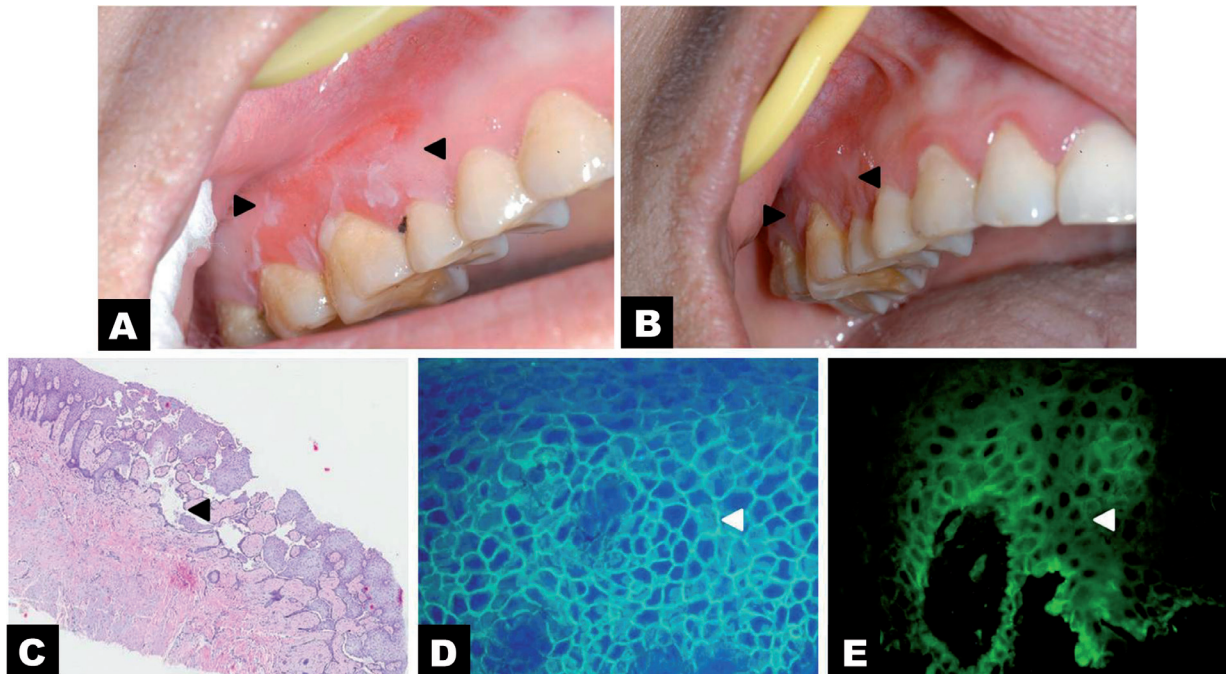


Figure 1 - Clinical manifestation, hematoxylin and eosin (H&E) staining assay, and direct immunofluorescence (DIF) assay in a patient with *pemphigus vulgaris* (PV): A) Gingival lesion (black arrows) of the PV patient before treatment, B) The gingival lesion healed (black arrows) after treatment, C) H&E staining (40 \times) showed acantholysis in the spinous layer and intraepithelial blister formation (black arrow), D) DIF showed fishnet-like deposition of immunoglobulin G between epithelial spinous cells (white arrow), and E) DIF also displayed fishnet-like deposition of complement C3 between epithelial spinous cells (white arrow).

tablets, 40 mg, once daily) during the non-menstrual period. However, AUB recurred and persisted until oral prednisone treatment was withdrawn. To control the oral PV, the treatment was changed to the intralesional injection of glucocorticoids (betamethasone) in combination with immunosuppressants and topical glucocorticoid application. After 2 weeks, all the lesions began to heal. Most importantly, the AUB did not recur. The treatment was again changed to a combination of oral thalidomide, biweekly intralesional betamethasone injection, and topical application of dexamethasone paste. After 4 months, all the lesions had healed without any evidence of AUB (Figure 1B).

In addition to the above-mentioned case, we also treated 2 other PV patients who experienced AUB during the non-menstrual period following glucocorticoid administration (Table 1). Both patients had normal menstruation and were definitively diagnosed with AUB following glucocorticoid administration via gynecological and physical examinations after the exclusion of organic diseases.

Patient 2. Her case involved relatively diffuse bullous erosions in the gingiva at the bilateral posterior mandibular area and bilateral abdomen of the tongue, and the initial dose of prednisone acetate used was

40 mg, once daily. The symptoms were well controlled at 2 weeks after treatment. Nevertheless, AUB developed 10 days after oral prednisone application, and spontaneously disappeared after one week, without any change in the treatment.

Patient 3. She exhibited localized lesions in the oral cavity, which was initially treated with a combination of thalidomide (75 mg, once daily) and intralesional injection of betamethasone (0.7 mg per week). The lesions were well-controlled following treatment. Nevertheless, AUB developed 5 days after the intralesional glucocorticoid injection. Although the administration mode was immediately changed to topical glucocorticoid application (dexamethasone paste), the AUB persisted without any sign of remission. Therefore, glucocorticoid treatment was withdrawn and the AUB resolved. Thereafter, treatment was switched to non-glucocorticoid medications (thalidomide, 75 mg, once daily). In these 2 patients, disease remission, without any recurrence of AUB, was noted at follow-up.

Discussion. Abnormal uterine bleeding is an underreported side effect of glucocorticoids. Only few cases of AUB following glucocorticoid application have been reported so far. Among them, 6 cases were pre-

and postmenopausal women who developed AUB after lumbar and sacral epidural injection of glucocorticoids to control neurological pain.^{4,5} The other cases included allergic patients who developed AUB following the application of triamcinolone acetonide.⁶

The potential mechanisms underlying the induction of AUB by glucocorticoids have been described. In particular, exogenous glucocorticoid treatment can inhibit the secretion of pituitary hormones, including follicle stimulating hormone (FSH) and luteinizing hormone (LH), and reduce the reactivity of the ovary to these 2 pituitary hormones. Such changes could lead to the decreased secretion of ovarian estrogen and progesterone, and consequently to AUB. Conversely, the accumulation of glucocorticoids as a result of high-dose glucocorticoid treatment could suppress the hypothalamic-pituitary-adrenal axis and lead to a decrease in the secreting function of the adrenal cortex. A reduction in the adrenocortical hormone, which mediates negative feedback regulation and is responsible for stimulating the secretion of the adrenocorticotropic hormone, could further lead to a decrease in the gonadotropin-releasing hormone, and subsequently to reduced secretion of FSH and LH. Finally, as a result of decreased secretion of ovarian estrogen and progesterone, AUB would occur.^{4,5,7,9}

Over the past 3 years, we have treated 3 PV patients who developed AUB following glucocorticoid administration. In these cases, AUB was induced by the systemic or topical administration of glucocorticoids; however, the AUB stopped spontaneously during glucocorticoid treatment, when the mode of glucocorticoid administration was changed, or when glucocorticoid treatment was completely withdrawn. Based on our experience with the treatment of these 3 patients, we propose the following treatment algorithm. First, a gynecological and physical examination is required to exclude organic diseases. Thereafter, treatment with glucocorticoids is continued. At this point, the AUB may disappear without the withdrawal of glucocorticoid treatment, which could be explained by the body's adaption to exogenous glucocorticoids. However, if AUB persists, we recommend a change in the administration mode of glucocorticoids. The mode of glucocorticoid administration may represent a critical factor in the development of AUB in such cases, because the systemic administration of glucocorticoids

may cause AUB, whereas topical application may not. Hence, changing the mode of administration of glucocorticoids is one method for resolving AUB. However, if AUB still persists, we suggest the complete withdrawal of glucocorticoid treatment and the use of non-glucocorticoid treatments.

In conclusion, AUB is a rarely reported side effect of glucocorticoid treatment for pemphigus, and should be carefully considered in routine clinical practice. Our proposed therapeutic algorithm can be appropriately used to manage this condition. Further prospective investigations regarding the management of AUB induced by glucocorticoids are necessary to support this treatment algorithm.

Acknowledgment. *The authors gratefully acknowledge the support from the National Natural Science Foundation of China, and New Century Talents Support Program of Ministry of Education, Beijing, China.*

References

1. Bystryn JC, Rudolph JL. Pemphigus. *Lancet* 2005; 366: 61-73.
2. Ben Lagha N, Poulesquen V, Roujeau JC, Alantar A, Maman L. *Pemphigus vulgaris*: a case-based update. *J Can Dent Assoc* 2005; 71: 667-672.
3. Poetker DM, Reh DD. A comprehensive review of the adverse effects of systemic corticosteroids. *Otolaryngol Clin North Am* 2010; 43: 753-768.
4. Çok OY, Eker HE, Çok T, Akin Ş, Ariboğan A, Arslan G. Abnormal uterine bleeding: is it an under-reported side effect after epidural steroid injection for the management of low back pain? *Pain Med* 2011; 12: 986.
5. Hirsch JG, Hsu ES. Abnormal uterine bleeding following lumbar epidural corticosteroid injections and facet medial branch blocks in both pre- and postmenopausal women: a case series. *Pain Med* 2012; 13: 1137-1140.
6. Mathov E, Grad P, Scaglia H. [Provocation of uterine hemorrhages and subcutaneous hematomas by the use of triamcinolone acetonide in allergic patients]. *Alergia* 1971; 18: 193-200. Spanish
7. Livingstone M, Fraser IS. Mechanisms of abnormal uterine bleeding. *Hum Reprod Update* 2002; 8: 60-67.
8. Committee for Guidelines for the Management of Pemphigus Disease, Amagai M, Tanikawa A, Shimizu T, Hashimoto T, Ikeda S, et al. Japanese guidelines for the management of pemphigus. *J Dermatol* 2014; 41: 471-486.
9. Suh-Burgmann E, Hung YY, Mura J. Abnormal vaginal bleeding after epidural steroid injection: a paired observation cohort study. *Am J Obstet Gynecol* 2013; 209: 206.