

# Infected pulmonary hydatid cyst

## A challenging diagnosis

Fahad M. AlRashed, MD, Dayel A. AlShabrani, MD.

### ABSTRACT

داء المشوكات هو داء طفيلي ذو تفشي حول العالم، طبيعة الأعراض السريرية تعتمد على موقع وحجم التكييس في الجسد. مريض في السابعة من عمره سُخِّص مبدئياً بالتهاب ذات الرئة البكتيري ليتضح لاحقا أن التشخيص الصحيح هو داء المشوكات الرئوي. هذه الحالة تشدد على صعوبة تشخيص داء المشوكات لقدرة هذا المرض على محاكاة عديد من الأمراض.

Echinococcosis is a parasitic infection that is distributed worldwide. Its clinical presentation depends on the size and location of the cyst. A 7-year-old was found with a superimposed infected pulmonary hydatid cyst that was initially misdiagnosed as complicated pneumonia. Our case underscores the challenges of diagnosing and managing echinococcosis, emphasizes the need for a high index of suspicion, and describes the disease's ability to mimic other clinical entities.

**Keywords:** echinococcosis, hydatid cyst, albendazole, praziquantel, parasite

*Saudi Med J* 2024; Vol. 45 (4): 433-436  
doi: 10.15537/smj.2024.45.4.20230078

From the Pediatric Infectious Diseases Department, Children's Specialized Hospital, King Fahad Medical City, Riyadh, Kingdom of Saudi Arabia.

Received 24th January 2024. Accepted 24th March 2024.

Address correspondence and reprint request to: Dr. Fahad AlRashed, Pediatric Infectious Diseases Department, Children's Specialized Hospital, King Fahad Medical City, Riyadh, Kingdom of Saudi Arabia. E-mail: fmalrashed@hotmail.com  
ORCID ID: <https://orcid.org/0009-0006-4272-5685>

Echinococcosis is a parasitic infection caused by Ectoparasitoids of the genus *Echinococcus*. It encompasses 2 distinct entities, cystic echinococcosis and alveolar echinococcosis, which are differentiated by the causative species *Echinococcus granulosus* and *Echinococcus multicularis*.<sup>1</sup> The World Health Organization (WHO) has listed echinococcosis as a neglected disease and aims to control or eliminate it by 2050.<sup>2</sup> It presents unique challenges due to the complexities associated with its diagnosis and management; in addition, it has the potential for metastasis akin to malignancy in nature given its high rate of recurrence post-treatment.<sup>1</sup> We report a case in which the patient's initial presentation was labeled as complicated pneumonia. Thus, the patient received a long course of antimicrobial therapy until a diagnosis of pulmonary echinococcosis (hydatid cyst) was obtained, which highlights the need for a high index of suspicion in echinococcosis diagnosis.

**Case Report.** A 7-year-old male with an unremarkable medical and surgical history presented initially with a week-long fever coupled with nocturnal cough and increased work of breathing. Other systemic reviews of the patient yielded unremarkable results. He was admitted to a local hospital in Al-Qurayyat, Saudi Arabia, where he received a 10-day course of ceftriaxone and vancomycin after being diagnosed with pneumonia. While the fever resolved, the patient's persistent cough led to enhanced chest computed tomography (CT), which revealed complicated pneumonia. Given the CT findings, he was referred to King Fahad Medical City, Riyadh, Saudi Arabia. The patient continued to undergo antibiotic therapy for 2 more weeks.

**Clinical findings.** He remained afebrile but showed no improvement in his cough.

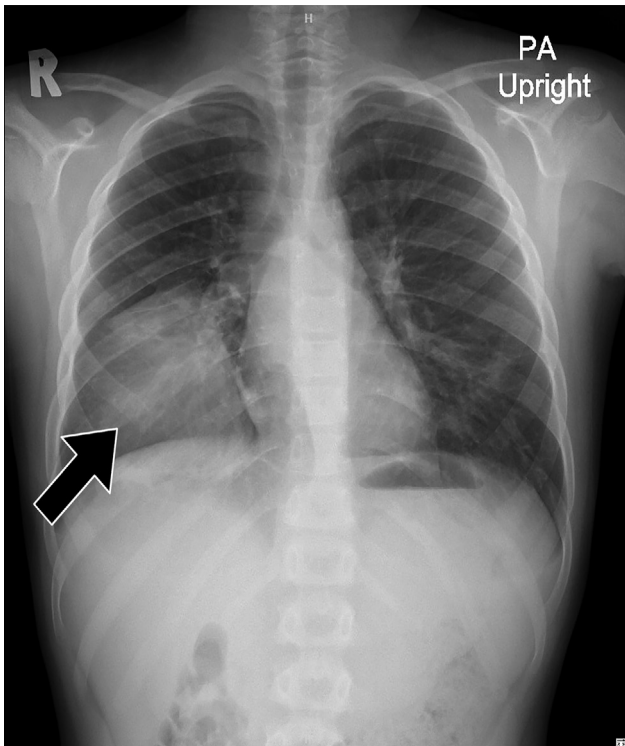
**Diagnostic assessment.** Laboratory results indicated white blood cell count within normal limits: 7.7

**Disclosure.** Authors have no conflict of interests, and the work was not supported or funded by any drug company.

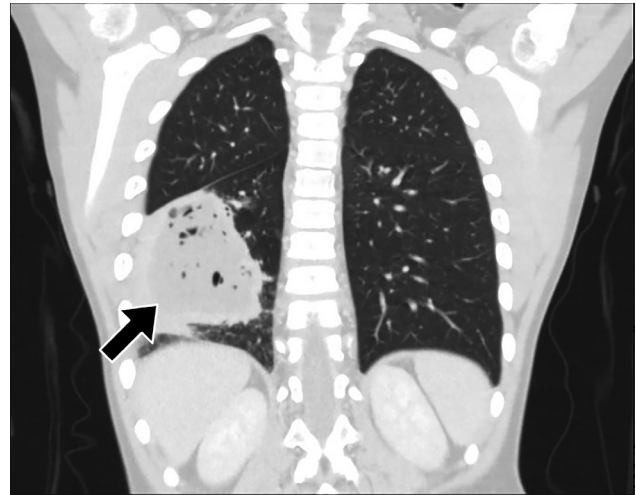
10<sup>3</sup>/uL (4.3-11.3 <sup>3</sup>/uL) of the white blood cells (34%) were neutrophils, 50% were lymphocytes, and 4% were eosinophils. A chest X-ray revealed well-defined rounded consolidation on the lower lobe (Figure 1). He was discharged on trial of bronchial asthma management with no noted benefit; and a repeat CT in an outpatient continued to suggest a diagnosis of complicated pneumonia with liquefied necrosis (Figure 2). A second opinion was sought, considering the positive exposure history to sheep and dogs, chest X-ray findings, and eosinophilia. Suspicion of hydatid disease was raised, and serology for *Echinococcus* antibody tests returned positive results - 7.2 (index blew 0.9 is considered negative) to support the diagnosis.

**Therapeutic intervention.** The patient was administered albendazole, followed by open thoracotomy and lobectomy. Histopathology confirmed the diagnosis of pulmonary echinococcosis, by demonstrating the cysts' outer acellular laminated membrane (Figure 3). After resection, the patient continued with albendazole therapy.

**Follow-up and outcomes.** He was followed in the clinic, and after 2 months, all his symptoms completely resolved.



**Figure 1** - Postero-anterior chest x-ray demonstrating the right lower lobe opacity.



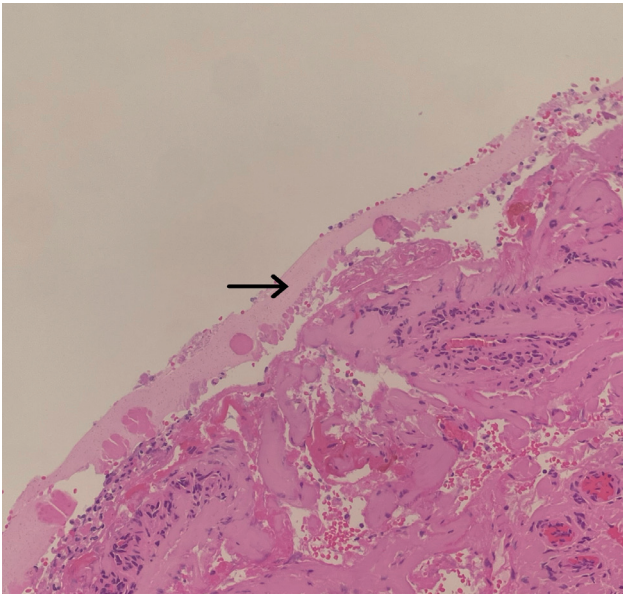
**Figure 2** - Enhanced chest computed tomography by intravenous contrast illustrate a Lower lung lobe cavitary lesion with central necrosis filled with fluid and pocket of air surrounded by a thick enhanced wall.

The key clinical findings and follow up for this patient are summarized in Figure 4.

**Discussion.** Echinococcosis remains a significant public health obstacle around the world despite preventive efforts.<sup>2</sup> The parasitic life cycle involves predator - prey interactions; the predator (such as dogs) act as definitive host to an adult worm, which produces eggs in the host's intestine, which is passed into the feces. When the eggs are ingested by the intermediate host (such as sheep), they hatch and pass into the bloodstream through the portal and lymphatic vessels, where they settle into the body organs. Humans acquire the cestode through the consumption of infected animal meat, or (rarely) by direct ingestion of the eggs.<sup>1</sup>

Echinococcosis is an endemic disease in Western Saudi Arabia and its surrounding countries.<sup>3</sup> Meat screenings revealed a disturbingly high rate of echinococcosis in slaughtered animals. Fawzia et al,<sup>4</sup> who hail from the western region of Saudi Arabia, reported a prevalence of 69% for hydatidosis in slaughtered sheep and 19% in goats. Another study carried out in Al Baha, Southwest Saudi Arabia, revealed a rate of 32% for echinococcosis in camels and 12% in sheep.<sup>5</sup> These rates combined with the prevailing herding lifestyle and socio-cultural shifts in pet ownership, particularly dogs likely contribute to significant epidemiological changes in Saudi Arabia.

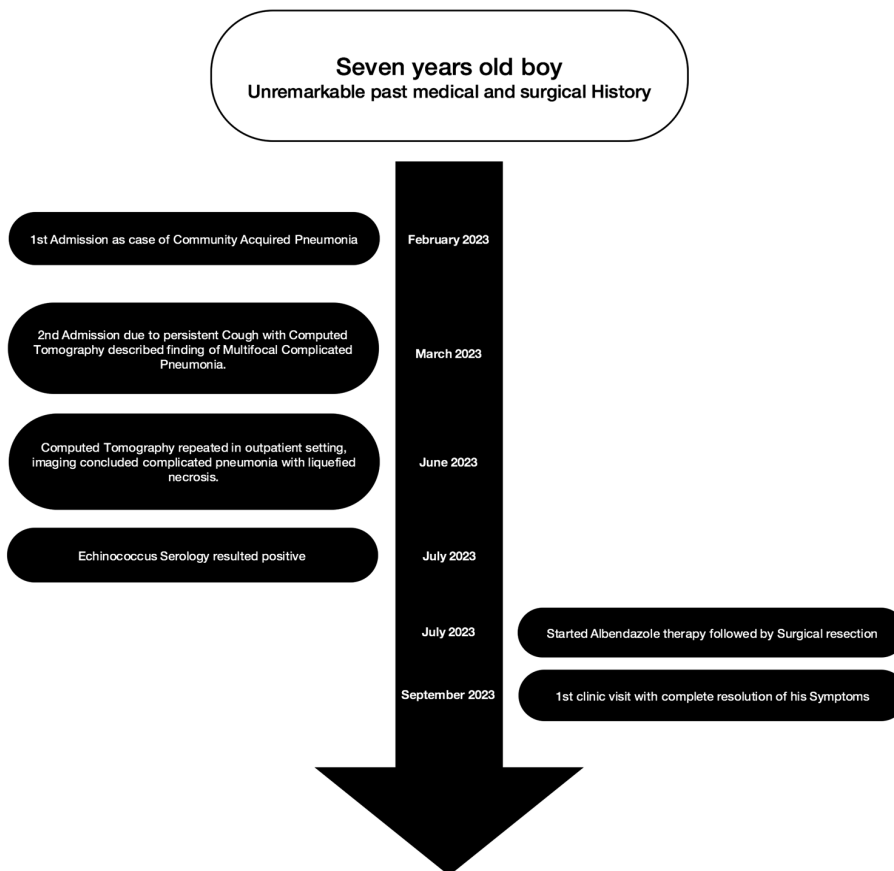
The disease often remains asymptomatic for extended periods. Its symptoms are the result of space occupation, and clinical presentation varies depending on the site affected, making diagnosis challenging.<sup>1</sup> Various cases



**Figure 3** - Grocott methamine silver stained histopathology section shows the characteristic Laminated membrane of the hydatid cyst (black arrow).

in the literature highlight delayed or misdiagnosed cases due to unusual cyst locations or superimposed infections, complicating the clinical picture. One of the earliest recorded cases of echinococcosis occurred in 1987 and depicted an adult female with an echinococcal hepatic cyst communicating with a similar cyst in the lung, presenting as pulmonary consolidation and pleural effusion. Cultures of both pleural fluid and cyst content yielded substantial growth of *Streptococcus milleri* and *Haemophilus parainfluenza*.<sup>6</sup> Lawandi et al<sup>7</sup> reported a case involving a 9-year-old female initially diagnosed with a bacterial lung abscess. However, an elevation in eosinophil count led to CT imaging, which led to the diagnosis of ruptured hydatid cysts. Bhat et al<sup>8</sup> described a 4-year-old female whose abdominal CT scan revealed a cystic mass related to the head and body of the pancreas. Initially labeled a choledochal cyst, the diagnosis of echinococcosis was only confirmed following surgical resection.

Current guidance in management is an effort endorsed by the WHO's Informal Working Group



**Figure 4** - Flowchart visualizing patient timeline.

on echinococcosis with the latest update published in 2009. The total surgical resection of the cyst is the recommended approach, but medical management is accepted in select cases. Benzimidazole remains the only anti-infective medication that halts the growth of the cestode; as such, it is used to reduce cyst size, decrease infectivity, and prevent relapse. The choice of treatment strategy should be based on a case-by-case approach guided by multidisciplinary teams.<sup>9</sup> Efforts are in progress to update and develop existing guidance in management as part of the WHO's plan to control or eliminate echinococcosis by 2050.<sup>2</sup>

Recent literature proposes a combination of benzimidazole plus praziquantel, Velasco-Tirado et al<sup>10</sup> published a meta-analysis in 2018 in which they concluded that there is a potential benefit in combined treatment with albendazole plus praziquantel compared to albendazole monotherapy in reducing the risk of disease recurrence, seeding of infection in case of cyst rupture, and the formation of secondary cysts. However, further studies are needed to solidify these recommendations.

There is a beacon of hope in that disease elimination is endorsed by WHO, whose plans to control or eliminate echinococcosis by 2050 include ongoing efforts to develop vaccines targeting intermediate hosts, aiming to interrupt the chain of transmission and halt the spread of the cestode to humans.<sup>2</sup>

In conclusion, this case emphasizes the ability of echinococcosis to mimic other clinical entities, including common diseases such as pneumonia, which highlights the need to consider echinococcosis in pediatric patients presenting with respiratory symptoms, particularly in endemic regions. Early diagnosis and a multidisciplinary approach to management are crucial, given the disease's potential for recurrence. Literature on echinococcosis is still lacking, which highlights the need for continued research and collaboration in the field of parasitology.

**Acknowledgment.** *The authors would like to thank Scribendi Inc. (<https://www.scribendi.com/>) for the English language editing.*

## References

1. Wen H, Vuitton L, Tuxun T, Li J, Vuitton DA, Zhang W, McManus DP. Echinococcosis: advances in the 21st century. *Clin Microbiol Rev* 2019; 32: e00075-18.
2. World Health Organization. Ending the Neglect to Attain the Sustainable Development Goals: A Road Map for Neglected Tropical Diseases 2021–2030. [Updated 2020; 2023 Dec 3]. Available from: <https://www.who.int/publications/item/9789240010352>
3. Borhani M, Fathi S, Lahmar S, Ahmed H, Abdulhameed MF, Fasihi Harandi M. Cystic echinococcosis in the Eastern Mediterranean region: neglected and prevailing! *PLoS Negl Trop Dis* 2020; 14: e0008114.
4. Toulah FH, El Shafei AA, Alsolami MN. Prevalence of hydatidosis among slaughtered animals in Jeddah, Kingdom of Saudi Arabia. *J Egypt Soc Parasitol* 2012 ;42: 563-672.
5. Ibrahim MM. Study of cystic echinococcosis in slaughtered animals in Al Baha region, Saudi Arabia: interaction between some biotic and abiotic factors. *Acta Trop*. 2010; 113: 26-33.
6. Masterton RG, O'Doherty MJ, Eykyn SJ. Streptococcus milleri infection of a hepatopulmonary hydatid cyst. *Eur J Clin Microbiol* 1987; 6: 414-415.
7. Lawandi A, Yansouni CP, Libman M, Rubin E, Emil S, Bernard C, Ndao M, Barkati S. A 9-year-old female with a cough and cavitary lung lesion. *Clin Infect Dis* 2019; 69: 705-708.
8. Bhat NA, Rashid KA, Wani I, Wani S, Syeed A. Hydatid cyst of the pancreas mimicking choledochal cyst. *Ann Saudi Med*. 2011; 31: 536-538.
9. Brunetti E, Kern P, Vuitton DA; Writing Panel for the WHO-IWGE. Expert consensus for the diagnosis and treatment of cystic and alveolar echinococcosis in humans. *Acta Trop* 2010; 114: 1-16.
10. Velasco-Tirado V, Alonso-Sardón M, Lopez-Bernus A, Romero-Alegria Á, Burguillo FJ, Muro A, Carpio-Pérez A, Muñoz Bellido JL, Pardo-Lledias J, Cordero M, Belhassen-García M. Medical treatment of cystic echinococcosis: systematic review and meta-analysis. *BMC Infect Dis* 2018; 18: 306.