

Bronchiolitis obliterans organizing pneumonia associated with pseudomonas aeruginosa infection

Daad H. Akbar, FRCP(UK), Arab Board, Omer S. Alamoudi, MRCP(UK), FCCP.

ABSTRACT

Bronchiolitis obliterans organizing pneumonia is a rare disease characterized by the presence of granulation tissue within alveolar ducts and alveoli. Most cases are idiopathic, but it may also be seen during resolution of viral or bacterial pneumonia (mycoplasma, legionella and chlamydia). It may present as a community acquired pneumonia which does not respond to antibiotics, which make the diagnosis very difficult. We described a 53-year old patient who presented with Bronchiolitis obliterans organizing pneumonia during the resolution of pseudomonas aeruginosa pneumonia. Initially there was slight improvement on antibiotics but later he became severely hypoxic and placed on mechanical ventilator. Diagnosis of Bronchiolitis obliterans organizing pneumonia was obtained with bronchoscopic lung biopsy. He showed an excellent response to steroid treatment. To our knowledge this is the first case of Bronchiolitis obliterans organizing pneumonia secondary to Pseudomonas aeruginosa pneumonia.

Keywords: Broncheolitis Obliterans Organizing Pneumonia, pseudomonas aeruginosa pneumonia.

Saudi Medical Journal 2000; Vol. 21 (11): 1081-1084

Bronchiolitis Oblitans Organizing Pneumonia (BOOP) is a rare lung disease characterized by the presence of excessive proliferation of granulation tissue within small airways, alveolar ducts and associated with chronic inflammation in the surrounding alveoli. It is a distinct clinical entity with features of a pneumonia rather than a primary airway disorder.^{1,2} It is generally idiopathic, but it may occur during the resolution of viral (adenovirus, cytomegalovirus, and HIV) or bacterial (mycoplasma, legionella and chlamydia) pneumonia.^{2,4} It is also associated with a variety of connective tissue disorders, drugs reaction, as well as bone marrow and lung transplantation.³⁻⁵ Extensive midline search since 1960 showed no previous report of BOOP that had occurred secondary to pseudomonas aeruginosa pneumonia. We describe

the first case of BOOP that occurred during the resolution of Pseudomonas aeruginosa to the best of our knowledge.

Case Report. A 53-year old Indian gentleman presented to King Abdulaziz University Hospital, with 2-days history of dyspnea, productive cough, yellow sputum, malaise, and fever. Systemic review was unremarkable. He had no history of tuberculosis (TB) or recently contacted patients with TB. He is known diabetic for 5-years on oral hypoglycemic agents. He is an electric-engineer, non-smoker, living in Saudi Arabia for the last 35-years. On examination, the patient looks ill, dyspneic, febrile (temperature 39.8°C), tachycardic (pulse rate of 110 beats/min), tachypnic (respiratory rate of 29 breaths/

From the Department of Medicine, King Abdulaziz University Hospital, Jeddah, Kingdom of Saudi Arabia.

Received 27th May 2000. Accepted for publication in final form 29th July 2000.

Address correspondence and reprint request to: Dr. Daad H. Akbar, PO Box 18298, Jeddah 21415, Kingdom of Saudi Arabia. Tel. +966 (2) 655 7043 Fax. +966 (2) 654 1626. Email: daadakb@yahoo.com

min), and blood pressure was 120/80mmHg. There was no clubbing of fingers or palpable lymphadenopathy. Chest examination revealed normal chest expansion and percussion. Breath sounds were decreased. There was mid and late inspiratory crackles on the right lower zone. Cardiovascular and abdominal examination were unremarkable. Central nervous system examination revealed signs of peripheral neuropathy. Initial investigations showed neutrophil leukocytosis of $14 \times 10^9/L$, raised erythrocyte sedimentation rate (ESR) of 50 mm/hr. Blood glucose was 21 mmol/l, urea, creatinine and electrolytes were normal. HIV, cold

agglutinin and mycoplasma culture were negative. Chest x-ray showed consolidation with air bronchogram in the right lower lobe and areas of calcification in the left upper lung (Figure 1). The patient was diagnosed as having community acquired pneumonia for which erythromycin and cefuroxim intravenously were given. Two-days later, pseudomonas aeruginosa was isolated from the sputum and then antibiotics were changed to ceftazidme and gentamycin. Initially patient's condition showed slight improvement as fever and cough subsided and the inspiratory crackles

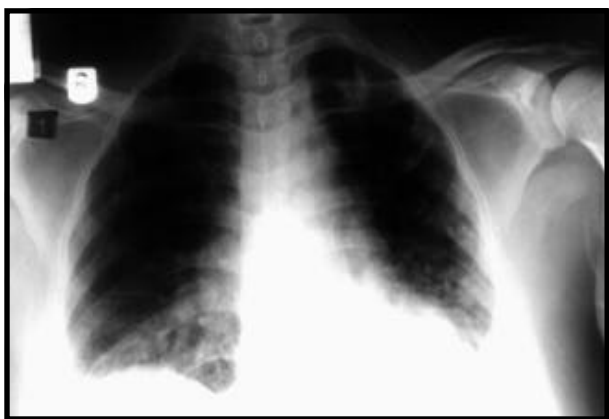

Figure 1 - CXR on admission showing right lung consolidation with air bronchogram.

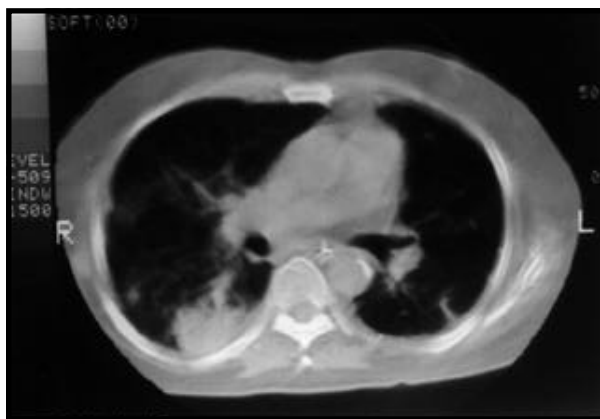

Figure 3 - Chest CT scan showing infiltration of the right and left lung.

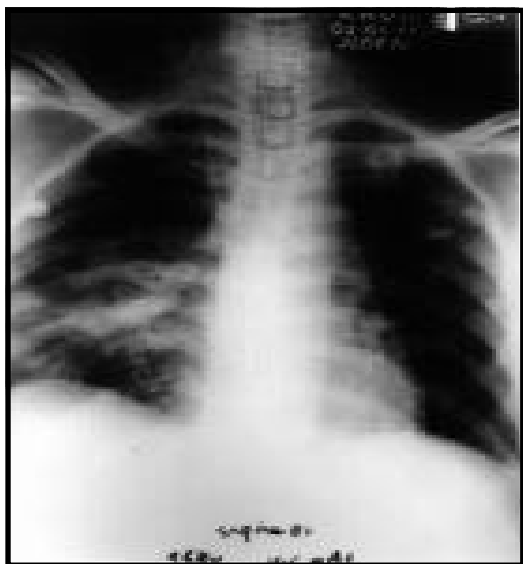

Figure 2 - CXR showing worsening of the pulmonary consolidation.

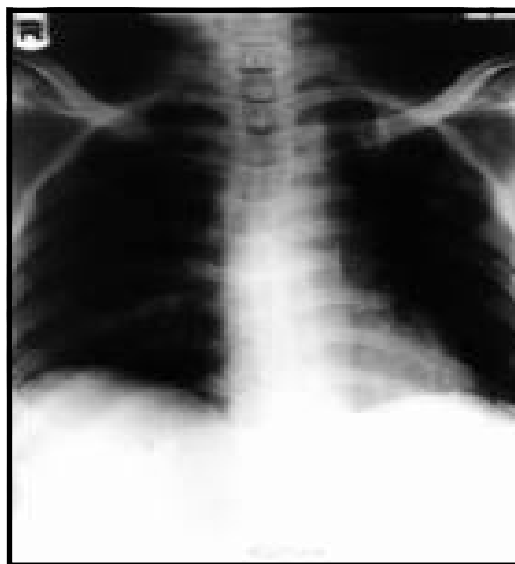


Figure 4 - CXR showing resolution of pulmonary infiltrate.

decreased. Chest x-ray showed slight resolution of the right lung opacity. Three-weeks later the patient's condition deteriorated, he started to have high-grade fever of 39°C with progressive dyspnea and severe dry cough. Chest x-ray showed worsening of the right lung opacity (Figure 2). White blood cell counts were normal while ESR raised to 128mm/hr. Sputum on 3-occasions was negative for AFB and PPD skin test was also negative. Bronchoscopy could not be carried out at that time due to technical problems. Although the patient had received several courses of antibiotics for the possibility of hospital acquired pneumonia, there was no much improvement. He became severely hypoxic and placed on mechanical ventilation. In view of the ethnic origin, the lack of radiological resolution, high ESR and the progressive deterioration of his condition, he was started empirically on anti-TB drugs in the form of rifampicin, isoniazide, ethambutol and pyrazinamide. After 4-weeks the patient's condition didn't show much improvement, neither clinically nor radiologically, and he lost over 10 kg during hospitalization. Computed tomography (CT) of the chest was carried out (Figure 3), which showed multiple areas of consolidation in the right lower lung and to a lesser extent on the left lung peripherally. Bronchoscopy with BLP was obtained from the right basal segment. BAL showed mixed inflammatory cells, and biopsy showed acute and chronic inflammatory infiltrate with fibrin consistent with BOOP. Rheumatoid factor, anti-nuclear and double stranded DNA antibodies, CPK (creatinine phosphokinase), C-reactive protein were negative. He was treated with pulsed methylprednisolone intravenously (1 gm/day for 3-days) and oral prednisolone 60 mg/day. The patient showed a remarkable improvement clinically and radiologically (Figure 4). He was extubated on the fifth day of steroid therapy. Patient's condition remained stable on tapered dose of steroid, his ESR dropped to 34mm/hr, and he is currently on regular follow up in the out patient clinic.

Discussion. BOOP is a rare disease. Its incidence and prevalence is unknown. A cumulative prevalence of 6 to 7 per 100,000 hospital admissions was found at a major teaching hospital.³ In our institute we see one to two cases per year. The typical onset of BOOP is usually in the fifth or sixth decades of life, similar to our patient. Males and females are affected equally.⁶ The clinical presentation often mimics that of community-acquired pneumonia. However, in 50% of cases the onset is preceded by a flu-like illness with fever, malaise, fatigue, and cough. Almost 75% of the patients were symptomatic for 2-3 months before diagnosis.^{1,5} Our patient was symptomatic for almost two months before the diagnosis could be reached.

In the severe forms of BOOP the requirement of mechanical ventilation for acute respiratory failure had been reported.⁷ Routine laboratory tests are non-specific. Leukocytosis is present in about 50% of patients while, ESR (>100 mm/hr.), and positive C-reactive protein are observed in 70-80%.^{4,8,9} In our patient, WBC was normal, ESR was 128mm/hr and C-reactive protein was negative. In BOOP the chest x-ray usually shows bilateral diffuse alveolar opacities predominantly in the lower lobe.² In our patient, chest x-ray showed a unilateral opacity, while chest CT scan showed bilateral consolidation and this is in agreement with previously reported cases.¹⁰ Open lung biopsy has been the preferred method for a definitive diagnosis, but transbronchial biopsy has also been found to be a useful if sufficient tissues were obtained.^{3,4,11} Spontaneous improvement is rare. Response to steroid therapy is excellent, especially in the idiopathic form where complete resolution may occur in 65-85% of patients.²⁻⁵ Rapidly fatal BOOP is uncommon.¹² Mortality may occur in 5%.² Although BOOP has been reported following adeno virus, cytomegalo virus, influenza, legionella, mycoplasma, and chlamydial pneumonia.^{2,4,13} There was no previous report of BOOP with pseudomonas aeruginosa pneumonia. We believe this is the first case of BOOP that occur following pseudomonas aeruginosa pneumonia reported in the English literatures.

In conclusion, BOOP is an uncommon condition but, should be considered seriously in patients with slow resolving pneumonia, especially those who fail to respond to repeated courses of antibiotics. Pseudomonas aeruginosa should be considered as one of the causes of BOOP.

References

1. King TE JR, Mortenson RL. Cryptogenic organizing pneumonia. The North American Experience. Chest 1992 Jul; 102 (1 Suppl): 8S-13S.
2. Epler-GR. Bronchiolitis obliterans organizing pneumonia. Semin Respir Infect 1995; 10: 65-77.
3. Alasaly K, Muller N, Ostrow DN, Chamion P, Fitz-Gerald JM. Cryptogenic organizing pneumonia. A report of 25 cases and a review of the literature. Medicine (Baltimore) 1995; 74: 201-211.
4. Garay JB, Zurdo MR, Lopez OA, Gaviria AZ, Medina LV, Delgado EG et al. Bronchiolitis obliterans organizing pneumonia. Review of six cases. Rev Clin Esp 1996; 196: 103-106.
5. Lamont J, Verbeken E, Verschakelen J, Demedts M. Bronchiolitis obliterans organizing pneumonia. A report of 11 cases and a review of the literature. Acta Clin Belg 1998; 53: 328-336.
6. Cordier-JF, Loire R, Brune J. Idiopathic bronchiolitis obliterans organizing pneumonia definition of characteristic clinical profile in a series of 16 patients. Chest 1989; 96: 999.
7. Kiyama T, Fujino N, Yoshinaga Eton Y, Kinuwaki E, Otsuka Y, Izumi K. A case of bronchiolitis obliterans organizing pneumonia showing acute respiratory failure treated with a mechanical ventilator. Nihon Kyobu Shikkan Zasshi 1990; 28: 1608-1610.

8. King TE Jr. Bronchiolitis obliterans. In: Interstitial lung disease, Schwarz MI, King TE Jr (Eds), Mosby-Year Book, Philadelphia, 1993. p.463.
9. Cordier JF. Cryptogenic organizing pneumonitis. Clin Chest Med 1993; 14: 677.
10. Preidler KW, Szolar DM, Moelleken S, Tripp R, Schreyer H. Distribution pattern of computed tomography findings in patients with bronchiolitis obliterans organizing pneumonia. Invest Radiol 1996; 31: 251-255.
11. Azzam ZS, Bentur L, Rubin AH, Ben Izhak O, Alroy G. Bronchiolitis obliterans organizing pneumonia. Diagnosis by transbroncheal biopsy. Chest 1993; 104: 1899-1901.
12. Cohen AJ, King TE, Downey GP. Rapidly progressive bronchiolitis obliterans with organizing pneumonia. Am J Respir Crit Care Med 1994; 149: 1670.
13. Diehl JL, Gisselbrecht M, Meyer G, Israel Biet D, Sors H. Bronchiolitis obliterans organizing pneumonia associated with chlamydial infection. Eur Respir J 1996; 9: 1320-1322.