Case Reports

Successful separation of thoracopagus conjoined twins

Abdullatif A. Al-Arfaj, MD, AFChir, Dilip K. Mitra, MS, MCh, Hussam S. Kadeeb, MCh, FRCS, Abdulmohsen A. Al-Ghamdi, DA (Eng), MD, Mohammad E. Abdulghaffar, MD, Bassam H. Al-Awary, CABP.

ABSTRACT

The first successful separation of thoracopagus conjoined twins in Eastern Saudi Arabia with 2-year follow up is presented. Physical examination and radiographic studies revealed a conjunction that extended from midsternum to a common umbilicus. The shared internal organs included liver and pericardium. The separation was performed at the age of 4 months. The resulting chest wall defects in both twins were covered by dacron-reinforced silastic prosthesis. The abdominal wall defect was primarily closed in the "left twin," and covered with a dacron reinforced silastic sheet in the "right". Primary skin closure was achieved in both, following extensive mobilization of the skin. The musculoskeletal deformities in the neck, chest and vertebral column showed marked improvement 20 months after separation.

Saudi Med J 2002; Vol. 23 (12): 1522-1526

Conjoined twinning is a rare occurrence. The incidence ranges from 1 in 100,000 to 1 in 200,000 live births.[1,2] Besides emotional and psychosocial involvement of the relatives and treating team, this condition raises interest for its rarity and the unique manifestation in each set. Thoracopagus twinning is defined as the ventral union between 2 twins extending from the upper thorax down to the umbilicus, including the heart in any form of conjunction. The term omphalopagus, although it can have an identical appearance with thoracopagus, is reserved for conjoined twins without heart involvement.[3] The term ventral is employed to designate the frontal, and dorsal to designate the posterior aspect of the individual twin. The broader united ventral aspect, usually recognizable at broader distance of the nipples, is referred to as "anterior"; the opposite side is "posterior" (**Figure 1**). These terms in inverted commas are reserved to identify the conjoined areas, and they are in no way identical to the usual terms anterior and posterior or ventral and dorsal. With the twins exposing the "anterior" aspect, the twin-on-their-right is called the "right twin" and the twin-on-their-left is called the "left twin."[3]

Case Report. The male twins were born at 35 weeks gestation by cesarean section to a 24-year-old prima gravida mother with uneventful antenatal care in Hofuf, a town located 150-km southwest of Al-Khobar City, Kingdom of Saudi Arabia (KSA). Their combined body weight was 3550g. The conjunction extended from midsternums to a common umbilicus measuring around 13 x 7 cm (**Figure 2**). The diagnosis of twinning was made at the 20th gestational week, but the union was discovered during obstructed labor. Despite emergency cesarean section, both suffered birth asphyxia; the Apgar scores for the "right twin" were 5, 6 and 7, and for the "left" 4, 5 and 7 at 1, 5 and 10 minutes. They developed bradycardia, irregular breathing and cyanosis and were intubated soon after birth and ventilated with 100% oxygen. They were

From the Division of Pediatric Surgery (Al-Arfaj, Mitra, Kadeeb), Department of Anesthesia (Al-Ghamdi, Abdulghaffar) and Department of Pediatrics (Al-Awary), College of Medicine, King Faisal University, Dammam, *Kingdom of Saudi Arabia*.

Received 27th May 2002. Accepted for publication in final form 31st July 2002.

Address correspondence and reprint request to: Prof. A. Al-Arfaj, Division of Pediatric Surgery, College of Medicine, King Faisal University, Dammam, *Kingdom of Saudi Arabia*. Tel. +966 55826898. Fax. +966 (3) 8825660. E-mail: aalarfajsa@yahoo.co.uk

extubated the next day, and transferred to King Fahd Hospital of the University in Al-Khobar, KSA. They were in good general condition and were grossly normal except left undescended testes in the "left twin".

Extensive studies performed during the first weeks of admission included plain radiography (**Figure 3**), contrast upper gastrointestinal series, echocardiography and hippuric imino-diacetic acid (HIDA) scan. Two separate hearts and 2 independent gastrointestinal tracts were identified. The diaphragms, the lower costal cartilages and the livers were united, but the integrity of 2 separate biliary systems was established. Both twins thrived well but their cervical hyperlordosis, chest and vertebral deformities increased. Their combined body weight at the time of operation was 9200g, an increase of 5650g in 4 months.

A medical team consisting of 2 surgeons, 2 anesthesiologists, one neonatologist and one nurse was formed to plan the separation. Meetings were held to discuss the preparation and the procedure: anesthesia induction, intubation, draping, intra-operative monitoring, the timing of procedure, the operative approach, the tables and the way of transferring one infant after separation.

The operative team consisted of 4 surgeons, 4 anesthesiologists, 2 surgical interns, 2 anesthetic technicians and 4 surgical nurses. After simultaneous mask induction, the twins were intubated successively, each twin obtained one peripheral and one central venous line. After painting the "anterior" aspect with povidone iodine, the twins were lifted to allow painting the "posterior" aspect and to drape the table. The twins were placed on an adult operating table after removal of its foot end. A folded towel was kept underneath the isthmus of fusion and without any frame to facilitate accessibility to the united structures. A vertical skin incision in the deepest point of union was made starting from the umbilicus to the chest. A well developed abdominal wall was incised initially near the umbilicus to enter 2 communicating peritoneal cavities. The incision was extended under finger guidance to the chest, where the "anterior" fused lower costal cartilages were divided with bone cutting forceps. Sternal fusion was divided as well. There were no xyphoid processes and the lower sternums were congenitally split in the midline. The communicating peritoneal cavities were explored. The livers were end-to-side united (**Figure 1**). The fused area approximated 9 x 7 cm. The presence of 2 independent biliary systems, segregated blood supply to each liver and 2 inferior venae cavae were confirmed. The individual integrity of both gastrointestinal tracts was verified. The peritoneal attachment between the fused livers and the fused diaphragms (fused left triangular ligaments) were perforated and 2 Penrose drains were threaded around the liver bridge on either side of the midline to act as a provisional tourniquet.

The separation of the liver was accomplished by finger fracture technique. Blood vessels and biliary channels were either electrocoagulated or suture-ligated. The procedure was not attended with much bleeding; the tourniquet was not tightened; the cut margins were approximated by interrupted overlapping mattress sutures using 2-0 chromic catgut on round needles and surgical. A communicating pericardium, discovered at the separation of the fused diaphragms, was opened "anteriorly" to find the apex of the "right twin's" heart overlapping the apex of the "left twin's" heart almost completely (**Figure 1**). The apex of the "right twin's" heart had a disc-like appendage, possibly a remnant connection between both hearts. This appendage was left in situ. Each apex was pushed back to its corresponding pericardium. The "posterior" wall was divided. A defect of roughly 2-cm diameter was closed by continuous 3-0 vicryl. Next, the "posterior" fused lower costal cartilages were separated; they had been left undivided to avoid shearing forces on the liver tissue during the separation process. The "posterior" abdominal wall musculature and skin were split immediately at the top point of union. The "left twin" was transferred to another table. The resulting anterior triangular chest wall defects in each twin measuring around 4 x 4 x 3 cm were closed using dacron reinforced silastic sheet and 3 – 0 vicryl after the parietal pleura was dissected away from chest wall and diaphragm to avoid pneumothorax (**Figure 4**). The abdominal wall musculature was primarily closed in both twins. However, the "right twin" developed high airway pressure with CO_2 accumulation and O_2 desaturation. This called for revision and the use of dacron-reinforced silastic sheet to close the abdominal defect more safely (**Figure 4**).

A primary skin closure in both infants was achieved following extensive mobilization of the skin. Both infants needed ventilatory support for 4 days and were weaned rapidly thereafter. They were under antibiotic cover with ceftazidine, cloxacillin and flagyl for 11 days. The ceftazidine was continued for another 6 days as a prophylactic measure against infection. The subcutaneous vacuum drains were removed on the 3rd postoperative day. Wounds healed primarily and patients were discharged home 27 days post surgery.

Both twins are now doing well at the age of 2 years (**Figure 5**). The cervical hyperlordosis in both twins is nearly resolved. The degree of pectus carinatum in both apparently decreased. The scoliosis and rib distortion in the "right twin" showed marked improvement. The left-undescended testis in the left twin is awaiting orchidopexy.

Discussion. The first successful separation of conjoined twins was performed in 450 A.D. in

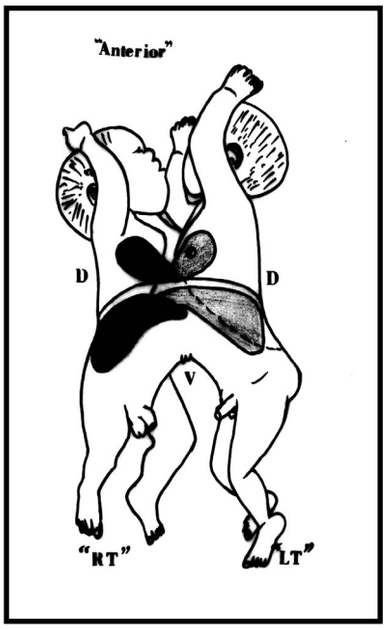

Figure 1 - Diagram depicting the "anterior" divergent aspect of conjoined area after separation of the "anterior" dermo-musculoskeletal conjunction. D - dorsal, V - ventral, "RT" - right twin, "LT" - left twin. The heart and the liver of the "RT" are symoblized in black, and "LT" in grey.

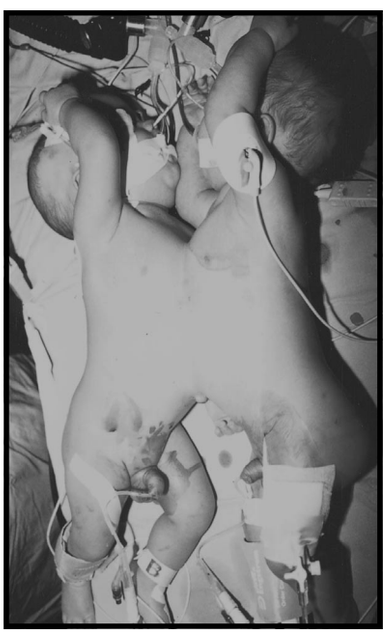

Figure 2 - Photograph showing the "anterior" aspect of conjoined area of the male twins after intubation, insertion of urinary catheters and peripheral and central venous lines. Notice the nipple distance.

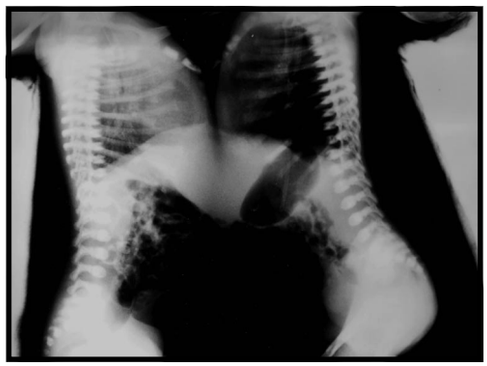

Figure 3 - Plain radiograph illustrating rotated thoracic vertebrae of the "right twin" and the shadow of fused livers.

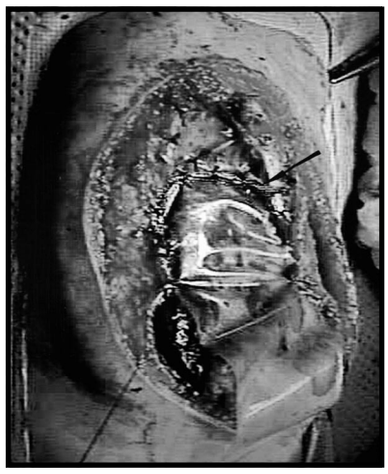

Figure 4 - Photograph showing the triangular chest defect (4 x 4 x 3 cm) post coverage with dacron reinforced silastic prosthesis in the "right twin". The abdominal wall defect (7 x 14 cm) is repaired with the same material. Arrow pointing to the diaphragm.



Figure 5 - Both twins at their 2nd birthday. Marked improvement in cervical hyperlordosis and pectus carinatum is noted.

Arabia. The twins were united in their lower backs, most likely of pygopagus type and were separated soon after birth by the attending midwife.[4] The first successful separation of conjoined twins with shared internal organs in recent times was reported from India in 1971 by Upadhyaya.[5]

Conjoined twinning results from incomplete partition of the zygote between the 13th and 15th day following fertilization. The partially fused zygotes are monoamniotic, monochorionic and represent an aberration of the twinning process.[6] In contrast, Spencer suggests that conjoined twins begin as a set of separate identical twins that fuse together in 8 specific areas of the embryo where the ectoderm is still gaping resulting in fusion at these points. The fusion occurs only between anatomically and tissue related areas for example, head to head, chest to chest, liver to liver and not liver to heart.[7] Considering the irreparable and complex nature of some types of conjoined twins, a diagnosis before 14 weeks' gestation is desirable to give the parents a realistic option for terminating the pregnancy. An accurate diagnosis can be achieved as early as 8 weeks' gestation.[8] A late diagnosis, as seen in this report, can jeopardize the life of mother and both infants alike.

Eight basic types of conjoined twins were recently proposed. All types can be identified by simple physical examination with the exception of the omphalopagus and thoracopagus type which may possess similar musculoskeletal union, but different involvement of internal organs, particularly the heart;[3] the distinction between these 2 types has significant impact on operability and survival. These classifications do not consider the anatomical details of shared internal organs. Each set of conjoined twins is a unique event and requires individual delineation of joint anatomical structures to prepare and arrange the separation procedure. The discrimination of these shared organs may represent a challenge for the experts and remain obscured.[9] Indeed, the surgeon has to rely in some instances entirely on the intraoperative findings to make the final decision. Unexpected anatomical abnormalities encountered during surgery have often resulted in the demise of one or both twins.[10] This fact demonstrates the extreme necessity to obtain as exact a knowledge as possible about the anatomy and physiology of the shared structures. This knowledge was obtained in our case by plane radiography, contrast upper gastrointestinal series, HIDA scan and echocardiography. There was no need for more sophisticated or invasive procedures. The missed common pericardium in our case, is likely to be the result of human and not of technical error. Richardson et al[10] were enthusiastic about the efficacy of magnetic resonance imaging techniques in demonstrating the anatomical perspectives in such details, that makes the use of conventional studies such as echocardiography, barium meal, abdominal sonogram and radionuclide imaging redundant. However, in complex cases, invasive diagnostic procedures such as angiography, pyelography, cystography and heart catheterization, to name but a few, are needed to define the anatomy.[9,11]

The separation in our case was delayed for approximately 4 months to allow the premature infants to grow and to improve their chances of survival. O'Neill et al[12] reported significant improvement of survival in those operated on beyond the age of 4 months. In the separation of thoracopagus conjoined twins, 2 specific problems are encountered: separation of the cardiovascular system, and coverage of the major defect in the anterior chest wall. Complex anomalies of the cardiovascular system are combined with high mortality of one or both twins. Indeed, there are no reports of successful separation of both twins with conjoined ventricles.[9] The separation of the common pericardium was simply achieved in our case.

Primary closure of a large chest wall defect inevitably results in cardiac decompensation caused by pressure on the heart. Therefore, a variety of techniques was proposed to achieve closure without inviting cardiac or pulmonary crisis. Flaps of chest wall and artificial implants such as a silastic prosthesis or absorbable material were suggested.[11,12] The use of the chest wall or other tissue from the non-surviving twin, when deceased, on the table was designed.[13] Canty et al[14] used syngeneic cryo-preserved tissue for secondary reconstruction of a large chest wall defect.[14] But, implantation of artificial material is frequently subject to infection, necessitating prolonged antibiotic cover as carried out in our case.

In the most recent literature, generous use of a tissue expander has been suggested.[11,15] The expanders are placed either in the subcutaneous or in the intraperitoneal position. These are useful in all cases where primary closure cannot be expected, but potential side effects on skin, internal organs, or both, should be recognized in time. Based on our limited experience, we recommend the use of absorbable material to cover a chest wall defect, although we used dacron-reinforced silastic prosthesis. It was noted that the chest wall defect in our case was covered rapidly by bony hard connective tissue, so that it was impossible to remove the implant – a potential source for delayed infection. The musculoskeletal deformities, which were more pronounced in the "right twin" showed marked improvement in both after 20 months of follow-up. However, longer observation is required to estimate the ultimate outcome.

References

1. Edmunds LD, Layde PM. Conjoined twins in the United States 1970-1977. *Teratology* 1982; 25: 301-308.
2. Viljoen DL, Nelson MM, Beighton P. The epidemiology of conjoined twinning in Southern Africa. *Clin Genet* 1983; 24: 15-21.
3. Spencer R. Anatomic description of conjoined twins: A plea for standardized terminology. *J Pediatr Surg* 1996; 31: 941-944.
4. El-Hussaini HM. A briography of the life of Mohammad, a new look. Beirut (LB): Dar El-Kalam; 1971. p. 35.
5. Upadhyaya P. Surgical Separation of Xiphoomphalopagus conjoined twins. *J Pediatr Surg* 1971; 6: 462-465.
6. Rejjal AL, Nazer HM, Abu-osba YK, Rifai A, Ahmad S. Conjointed twins: medical surgical and ethical challenges. *Aust N Z J Surg* 1992; 62: 287-291.
7. Zimmerman AA. Embryologic and anatomic considerations of conjoined twins. *Birth Defects Orig Artic Ser* 1967; 3: 18-27.
8. Spencer R. Conjoined twins: Theoretical embryologic basis. *Teratology* 1992; 45: 591-602.
9. Lam YH, Sin SY, Lam C, Lee CP, Tang MHY, Tse HY. Prenatal sonographic diagnosis of Conjoined twins in the first trimester: two case reports. *Ultrasound Obstet Gynecol* 1998; 11: 289-291.
10. Cywes S. Challgenges and dilemmas for a pediatric surgeon. *J Pediatr Surg* 1994; 8: 957-965.
11. Richardson RJ, Applebaum H, Taber P, Woolley MM, Chwals WF, Warden MJ et al. Use of magnetic resonance imaging in planning the separation of omphalopagus conjoined twins. *J Pediatr Surg* 1989; 7: 683-685.
12. O'Neill JA, Halcomb GW, Schnaufer L, Templeton JM, Bishop HC, Ross AJ et al. Surgical experience with thirteen conjoined twins. *Ann Surg* 1988; 208: 299-312.
13. Hisano K, Nakamura K, Okada M, Iwai S. Separation of conjoined twins using chest wall prosthesis. *J Pediatr Surg* 1989; 24: 928-929.
14. Canty TG Sr, Mainwaring R, Vecchione T, Lamberti J, Collins D, Lynch F et al. Separation of Omphalopagus twins: unique reconstruction using syngeneic cryopreserved tissue. *J Pediatr Surg* 1998; 33: 750-753.
15. Hilfiker ML, Hart M, Holmes R, Cooper M, Kriett J, Collins D et al. Expansion and division of conjoined twins. *J Pediatr Surg* 1998; 33: 768-770.