

# Salt losing nephropathy simulating congenital adrenal hyperplasia in an infant

*Jameela A. Kari, MD, FRCPC, Hussain A. Bamashmous, DCH, CABP,  
Abdulmoein E. Al-Agha, MRCP (UK), CABP Hisham A. Mosli, FRCSC, FACS.*

---

## ABSTRACT

Pseudo-hypoaldosteronism occurring predominately in male infants has been reported in association with a spectrum of urologic diseases including obstructive uropathy. This is thought to reflect tubule unresponsiveness to aldosterone. We report a case, which was misdiagnosed as a case of congenital adrenal hyperplasia and treated inappropriately with hydrocortisone and fludrocortisone for 12-months before he had a urinary tract infection and was discovered to have obstructive uropathy on ultrasound. He presented with vomiting, dehydration, hyperkalemia, hyponatremia and metabolic acidosis. His initial 17 hydroxyprogesterone was high. His electrolytes improved to normal after relieving the obstruction by vesicostomy and his treatment weaned slowly without complications. This case demonstrates the importance of urine culture and ultrasound examination in suspected cases of pseudo-hypoaldosteronism.

**Keywords:** Pseudo-hypoaldosteronism, congenital adrenal hyperplasia.

**Saudi Med J 2002; Vol. 22 (7): 863-865**

---

**P**seudo-hypoaldosteronism (PHA) was described as a case of salt losing condition seen in infants with vomiting, dehydration, hyponatremia, hyperkalemia failure to thrive, metabolic acidosis, elevated peripheral renin activity, and increased plasma aldosterone concentration with normal adrenal function and normal renal anatomy.<sup>1-2</sup> In addition to sporadic cases, familial, recessive and dominant inheritance has been described.<sup>3-5</sup> Transient pseudo-hypoaldosteronism (TPHA) and renal tubular resistance to aldosterone, secondary to renal disease has been described previously.<sup>6-10</sup> Sixty-three cases have been reported.<sup>11</sup> Treatment of the urological abnormalities often leads to resolution of the salt wasting syndrome. The clinical presentation of these infants is confusing and may lead to incorrect diagnosis of congenital adrenal hyperplasia (CAH). We report a case of salt losing obstructive uropathy misdiagnosed as CAH, treated with hydrocortisone and fludrocortisone acetate for 12-months with

developed steroid side effects. This reflects the rarity of the condition and the unawareness of the general pediatricians regarding the possibility of salt losing nephropathy-simulating CAH. This case illustrates the importance of performing urine culture and the screening for renal anomalies by ultrasound examination to exclude the possibility of obstructive uropathy in any child presenting with PHA, which might be confused with CAH.

**Case Report.** Baby boy born by cesarean section at 35 weeks due to prolonged premature membrane rupture. His birth weight was 2.2 kg and his length was 47cm. At the age of 3 weeks, he was admitted with diarrhea and vomiting and found in severe dehydration with high potassium, low sodium (NA) and metabolic acidosis. At 3 weeks of age, his basal 17 hydroxyprogesterone (17-OHP) was 21 nmol/l (normal <15.3). renin, aldosterone or

---

From the Department of Pediatrics (Kari, Bamashmous, Al-Agha) and Department of Urology (Mosli), King Abdul-Aziz University Hospital, Jeddah, Kingdom of Saudi Arabia.

Received 20th October 2001. Accepted for publication in final form 10th February 2002.

Address correspondence and reprint request to: Dr. Jameela A. Kari, Associate Professor, Pediatrics Department, King Abdul-Aziz University Hospital, PO Box 80215, Jeddah, 21589, Kingdom of Saudi Arabia. Tel. +966 55677904. Fax. +966 (2) 6743781. E-mail: jkari@doctors.org.uk

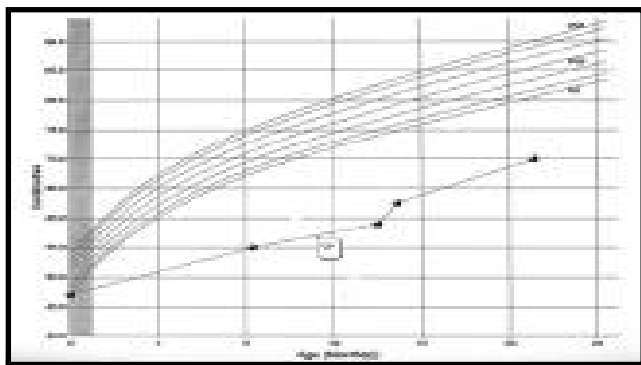


Figure 1 - Length for age.

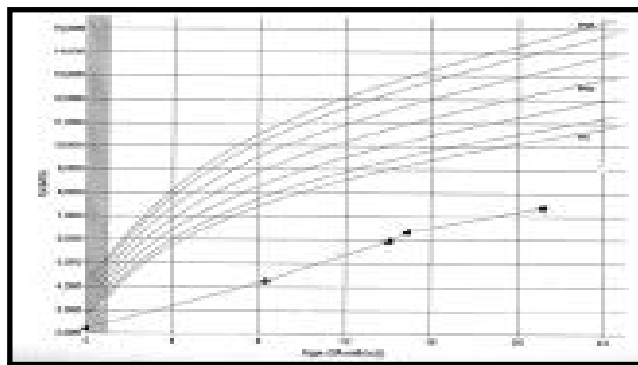


Figure 2 - Body mass index for age.

adrenocorticotrophin (ACTH) levels were not carried out. He was diagnosed as CAH and was commenced on hydrocortisone 5 mg 3 times a day (88mg/m<sup>2</sup>/day), Fludrocortisone 150 microgram a day and sodium bicarbonate 4 mmols twice a day. He improved partially but he continued to have recurrent episodes of diarrhea and vomiting requiring hospital admission and intravenous hydration once or twice per month. At the age of 9 months, he was referred to King Abdul-Aziz University Hospital for further evaluation. He had cushingoid features and he had mature cataract in his right eye. His length was 55cm with Z score of -7.22, his weight was 4.27 with Z score of -5.92 and body mass index (BMI) 14.1 and head circumference 37 cm (below 5th%) (Figures 1 & 2). He was found to be hyponatremic with Na of 124 mmol/l and normal potassium of 4 mmol/l. His bone age was less than 3 months. He had normal thyroid function test, toxoplasma, rubella virus, cytomegalovirus, herpes simplex virus (TORCH) screen was negative and magnetic resonance image of brain showed communicating hydrocephalus. A repeat of his 17-OHP was low at 1.8 nmol/l despite the hyponatremia and therefore the diagnosis was changed to CAH. He had an extraction of his cataract and his hydrocortisone dose was reduced to 5mg 2 times a day (39.2 mg/m<sup>2</sup>/day), sodium chloride solution was added to his medications and he continued on the previous dose of fludrocortisone acetate. However his Na was always in the low side. Three months later, at the age of 12 months he was discovered to have a urinary tract infection after a febrile episode. Ultrasound of his renal tract showed bilateral hydroureters, hydronephrosis and bladder diverticulae. His <sup>99m</sup> technetium-diethylentriamine pentacetic acid scan showed bilateral hydroureters, hydronephrosis and impaired renal function suggesting obstructive uropathy. Voiding cystogram showed posterior urethral valve (PUV). Intravenous urography demonstrated, non-functioning right kidney. He was diagnosed as a case of salt losing nephropathy-simulating CAH. He had a vesicostomy

at the age of 14 months and his medications were weaned off over 3 months. His Na and potassium continued to be normal after stopping his medications.

**DISCUSSION.** This case illustrates the importance of performing urine culture and renal ultrasonography in any infant with electrolyte disturbances to exclude infection or obstructive uropathy. The presentation of TPHA associated with renal diseases is similar to CAH, with the same electrolyte disturbances of hyperkalemia, hyponatremia and metabolic acidosis. However the universal incidence of CAH is higher as it is variable between 1:10000 and 1:17000, with 50%-75% frequency of the salt-wasting form.<sup>12</sup> In view of the rarity of TPHA caused by renal tubular resistance to aldosterone, secondary to renal disease, only 63 cases previously reported, it is sensible to think initially of CAH as a diagnosis in those cases. However before initiating hydrocortisone and fludrocortisone therapy, blood samples for 17-OHP, plasma renin, aldosterone and ACTH should be obtained. The results of those tests will differentiate between CAH and PHA therefore avoiding unnecessary and inappropriate prolonged steroid treatment. Ultrasound of the renal tract is mandatory in suspected cases of PHA to avoid serious complications as in the reported patient. Furthermore sonography of the adrenal glands could be helpful in diagnosing CAH, as adrenal glands may be enlarged<sup>13</sup> in addition to the confirmation of the presence or the absence of the uterus.

The initial 17-OHP was high in the presented case. This could be explained by the fact that 17-OHP is significantly higher in premature than in full-term infants.<sup>14</sup> The reported patient was pre-term of 35 weeks gestational age, indicating the need to interpret the initial result cautiously. 17-hydroxyprogesterone is used as a screening test for CAH in many countries,<sup>15,16</sup> but the high false

positive rate, emphasizes the need to set a screening cut-off value such that the false-positive rate does not oversaturate the follow-up system. It may soon be possible to include genotyping as a second-tier confirmation as a part of the newborn screening protocol. Genotyping is a valuable diagnostic tool and a good complement to neonatal screening, especially in confirming or discarding the diagnosis in cases with slightly elevated 17-OHP levels. An additional benefit is that it provides information on disease severity, which reduces the risk of over-treatment of mildly affected children.<sup>17</sup> The 2nd low reading of 17-OHP in the presented case could be explained by the suppression of the adrenal gland with high doses of steroid intake. The unfortunate boy, was not diagnosed prenatally and presented weeks postnatally with severe salt-losing renal dysfunction, caused by TPHA and misdiagnosed as salt losing CAH. The prolonged inappropriate treatment lead to the complication of cataract, cushingoid appearance and failure to grow. Although all his growth parameters were below 5%, when he presented to our institution, his height was the most severely affected with Z score of -7.2, indicating the effect of inappropriate steroid therapy, in addition to the affect of the disease itself as PHA is a cause of failure to thrive.

Pseudo-hypoaldosteronism is a rare salt wasting syndrome of infancy and postulated to be caused by renal tubular in-sensitivity to mineralocorticoids. It may be an isolated condition or may be associated with renal diseases,<sup>6-11</sup> prematurity<sup>18</sup> or renal transplantation.<sup>19</sup> A wide variety of urologic lesions have been reported in association with TPHA.<sup>6-11</sup> These include both obstructive<sup>6-7</sup> and non-obstructive lesions such as massive vesico-uretral reflux (VUR) usually accompanied with urinary tract infection.<sup>8</sup> It has been reported in children with acute pyelonephritis.<sup>20</sup> The most likely explanation for the development of salt wasting in these infants is the transient unresponsiveness of the distal renal tubules to aldosterone.<sup>10</sup> Increased intrarenal pressure whether due to obstruction or reflux may be in part responsible for the tubular dysfunction and therefore TPHA.

It is clear from our case and previous reported cases<sup>6-11</sup> that ultrasonography is the most useful tool in the evaluation of these infants with signs and symptoms of salt wasting. In the case discussed, ultrasound demonstrated bilateral hydronephroses and hydronephrosis indicating obstructive uropathy, which enabled the treating team to make the diagnosis of TPHA. Although similar cases have been reported, we think it is important to report this case in order to educate the pediatricians regarding the importance of urine culture and ultrasound examination in suspected cases of salt losing nephropathy. This approach could prevent avoidable complications and inappropriate medications.

## References

- Blachar Y, Kaplan BS, Griffel B, Levin S. Pseudohypoaldosteronism. *Clin Nephrol* 1979; 11: 281-288.
- Proesmans W, Muaka B, Corbeel L, Eeckels R. Pseudohypoaldosteronism, a proximal tubular sodium wasting disease. *J Pediatr* 1978; 92: 678-679.
- Roy C. [Familial pseudohypoaldosteronism (apropos of 5 cases)] Pseudohypoaldosteronisme familial (a propos de 5 cas). *Arch Fr Pédiatr* 1977; 34: 37-54.
- Limal JM, Rappaport R, Dechaux M, Morin C. Familial dominant pseudohypoaldosteronism. *Lancet* 1978; 1: 51.
- Bonnici F. [Autosomal recessive transmission of familial pseudohypoaldosteronism]. Pseudohypoaldosteronisme familial a transmission autosomique recessive. *Arch Fr Pédiatr* 1977; 34: 915-916.
- vd Heijden AJ, Versteegh FG, Wolff ED, Sukhai RN, Scholtmeijer RJ. Acute tubular dysfunction in infants with obstructive uropathy. *Acta Paediatr Scand* 1985; 74: 589-594.
- Marra G, Goj V, Appiani AC, Dell AC, Tirelli SA, Tadini B et al. Persistent tubular resistance to aldosterone in infants with congenital hydronephrosis corrected neonatally. *J Pediatr* 1987; 110: 868-872.
- Vaid YN, Lebowitz RL. Urosepsis in infants with vesicoureteral reflux masquerading as the salt-losing type of congenital adrenal hyperplasia. *Pediatr Radiol* 1989; 19: 548-550.
- Levin TL, Abramson SJ, Burbige KA, Connor JP, Ruzal-Shapiro C, Berdon WE. Salt losing nephropathy simulating congenital adrenal hyperplasia in infants with obstructive uropathy and/or vesicoureteral reflux-value of ultrasonography in diagnosis. *Pediatr Radiol* 1991; 21: 413-415.
- Rodriguez-Soriano J, Vallo A, Oliveros R, Castillo G. Transient pseudohypoaldosteronism secondary to obstructive uropathy in infancy. *J Pediatr* 1983; 103: 375-380.
- Bulchmann G, Schuster T, Heger A, Kuhnle U, Joppich I, Schmidt H. Transient pseudohypoaldosteronism secondary to posterior urethral valves - a case report and review of the literature. *Eur J Pediatr Surg* 2001; 11: 277-279.
- Pang SY, Wallace MA, Hofman L, Thuline HC, Dorche C, Lyon IC. Worldwide experience in newborn screening for classical congenital adrenal hyperplasia due to 21-hydroxylase deficiency. *Pediatrics* 1988; 81: 866-874.
- Sivit CJ, Hung W, Taylor GA, Catena LM, Brown-Jones C, Kushner DC. Sonography in neonatal congenital adrenal hyperplasia. *AJR Am J Roentgenol* 1991; 156: 141-143.
- Sulyok E, Solyom J, Fuller M, Kerekes L. Postnatal changes in blood spot 17-hydroxyprogesterone level in healthy preterm and full-term neonates. *Acta Paediatr Hung* 1988; 29: 239-243.
- Therrell BL. Newborn screening for congenital adrenal hyperplasia. *Endocrinol Metab Clin North Am* 2001; 30: 15-30.
- Mikami A, Fukushi M, Oda H, Fujita K, Fujieda K. Newborn screening for congenital adrenal hyperplasia in Sapporo City: sixteen years experience. *Southeast Asian J Trop Med Public Health* 1999; 30 Suppl 2: 100-102.
- Nordenstrom A, Thilen A, Hagenfeldt L, Larsson A, Wedell A. Genotyping is a valuable diagnostic complement to neonatal screening for congenital adrenal hyperplasia due to steroid 21-hydroxylase deficiency. *J Clin Endocrinol Metab* 1999; 84: 1505-1509.
- Abramson O, Zmora E, Mazor M, Shinwell ES. Pseudohypoaldosteronism in a preterm infant: intrauterine presentation as hydramnios. *J Pediatr* 1992; 120: 129-132.
- Uribarri J, Oh MS, Butt KM, Carroll HJ. Pseudohypoaldosteronism following kidney transplantation. *Nephron* 1982; 31: 368-370.
- Rodriguez-Soriano J, Vallo A, Quintela MJ, Oliveros R, Ubetagoyena M. Normokalaemic pseudohypoaldosteronism is present in children with acute pyelonephritis. *Acta Paediatr* 1992; 81: 402-406.