

Case Report

Transabdominal cervicoisthmic cerclage after multiple failed vaginal cerclages

Shakeel A. Faiz, MB, MFFP, Abdulaziz A. Al-Meshari, MB, FRCOG.

ABSTRACT

Cervical incompetence is a condition traditionally treated by cervical cerclage. We describe a patient who had 6 failed cervical cerclages and who was treated with transabdominal cervicoisthmic cerclage. There were no intra-operative or post-operative complications and the patient was regularly reviewed in the antenatal clinic by a senior physician and with a series of transvaginal ultrasounds. The patient went into labor at 36-weeks of gestation and had an emergency lower segment cesarean section, with a live male infant weighing 2.38 kg. Both mother and baby did well after delivery.

Keywords: Cervical incompetence, abdominal cerclage.

Saudi Med J 2002; Vol. 23 (8): 1008-1010

Cervical incompetence is a condition, which predisposes to mid-trimester pregnancy loss or premature delivery. Transvaginal cervical cerclage is a procedure, which is of great benefit to women with proven cervical incompetence. In some women however, the transvaginal approach repeatedly fails and these women may be suitable for a transabdominal approach.

Case Report. The patient is 35-years-old, Saudi female, gravida 11 para 4 + 6 abortions booked in the antenatal clinic at the gestation age of 14+ weeks. This patient had a history of bad obstetric outcome with 6 transvaginal cervical cerclages, 3 neonatal deaths and only one living child. Her first pregnancy ended in premature delivery at 30 weeks of gestation and neonatal death after 2 days. The 2nd pregnancy ended by lower segment cesarean section at 28 weeks of gestation due to premature labor and fetal distress, baby died after 2 days. The 3rd were twins, which were aborted at 20 weeks of gestation.

In her 4th pregnancy patient had cervical cerclage at 12 weeks of gestation and again had premature delivery at 30 weeks, and neonatal death after 5 days. In her 5th pregnancy the patient again had cervical cerclage and delivered at 34 weeks, child is well and healthy. In the 6th pregnancy no cervical cerclage was applied she had an abortion at 12 weeks. In her 7th, 8th, 9th and 10th pregnancies she had cervical cerclages but all ended with miscarriages at 18, 20, 20 and 22 weeks.

In her present (11th) pregnancy, the patient was admitted to hospital at 14 weeks gestation. An ultrasound examination corresponded to dates and demonstrated a cervical length of 2.5cm and width of less than 2cm. At admission a speculum examination was carried out which showed a very short scarred cervix with multiple scars after old lacerations. The patient was counseled regarding the possibility of abdominal cerclage to which she agreed.

Surgical procedure. Under general anesthesia the abdomen was opened through sub-umbilical

From the Department of Obstetrics & Gynecology, King Khalid University Hospital, Riyadh, Kingdom of Saudi Arabia.

Received 9th December 2001. Accepted for publication in final form 10th April 2002.

Address correspondence and reprint request to: Dr. Shakeel A. Faiz, Department of Obstetrics & Gynecology, King Khalid University Hospital, PO Box 7805, Riyadh 11472, Kingdom of Saudi Arabia. Tel. +966 (1) 4670818. Fax. +966 (1) 4679557. E-mail: shakeel@ksu.edu.sa

incision due to previous lower segment cesarean section. The vesical peritoneum overlying the lower uterine segment was divided transversely. The bladder and paravesical tissues were pushed caudally until the supra vaginal cervix could be seen and palpated in the midline with good exposure laterally. The uterine vessels were displaced laterally opening the para-cervical connective tissue space as shown in **Figure 1**. Care was taken to avoid wide dissection laterally as of the increased vascularity due to pregnancy. The lower portion of isthmus at the level of the internal cervical os was palpated between the thumb and the index finger with the uterus in the palm of the hand. Lateral to these structures the uterine artery and vein were recognized. Three anatomical features were sought to identify the site of the suture insertion: The point where the cervix widens into the soft isthmus, the uterine vessel passing longitudinally, and the point of insertion of the uterosacral ligaments into the uterus. Mersilene tape 5mm wide with round bodied needles on both ends (Ethicon Ltd) was used and the knot was tied anteriorly. The vesical peritoneum was reconstituted and the abdomen closed in layers. The estimated blood loss was less than 300ml. Analgesia was given post-operatively and the patient was put on intravenous Ritodrine for 24 hours. The patient stayed in hospital for 6-days and was discharged home in a satisfactory condition. Before discharge she had an ultrasound scan which confirmed a viable fetus. The patient was regularly reviewed in the antenatal clinic by a senior physician and a series of ultrasounds showed the supravaginal length to be seen with the cerclage easily identifiable and holding pregnancy. The patient received 2 courses of Betamethasone after 24 weeks. At 36 weeks gestation the patient came in labor. Cardiotocogram showed fetal distress, and an emergency lower uterine caesarean section was performed. A live male infant weighing 2.38 kgs was delivered. Placenta was removed completely; both mother and baby did well after delivery. At the operation the cerclage was felt to be tightly in place at the isthmus and it was left undisturbed.

Discussion. Cervical incompetence is widely acknowledged to predispose to mid-trimester miscarriage and premature delivery. The pathogenesis of the incompetent cervix may be idiopathic, result from congenital anomalies, diethylstilboestrol (DES) exposure in utero, cervical trauma or surgery, or previous cervical cerclage.

Shirodkar¹ reported the insertion of a cervical suture in pregnancy and McDonald² published the more simple purse string suture. However, as in the present case the transvaginal approach may be difficult or impossible to perform, due to a short and severely damaged cervix after several transvaginal

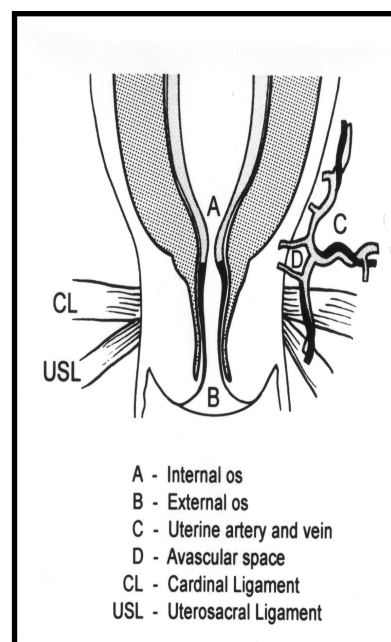


Figure 1 - Anatomy of cervicoisthmic junction showing avascular space for placement of mersilene band.

sutures. In such cases the procedure of transabdominal cervicoisthmic cerclage may be appropriate. This approach was first described by Benson and Durfee,³ and has since been confirmed as a viable alternative procedure for women with failed transvaginal sutures. The success rate is claimed to be upward of 90%.⁴ The site of placement of the knot, whether anterior or posterior may vary. We put the knot anterior in our patient but most of the authors feel that posterior knot placement is superior as it reduces the amount of bladder irritation and facilitates suture removal via posterior colpotomy should this be required.⁵

There is no study comparing transabdominal cervical suture inserted in the non-pregnant state with those inserted during pregnancy. During pregnancy the tissues are softer and more pliable. This facilitates the opening of the connective tissue window in the broad ligament lateral to the cervix and medial to the uterine vessels as well as identification of the correct point of stitch insertion in the enlarged organs. Most authors prefer to perform transabdominal cerclage during pregnancy at a gestational age of between 12 and 14 weeks.⁶ A review of literature reveal that over 80% were performed during pregnancy usually after 12 weeks.⁴ Although removal of transabdominal cerclage with posterior colpotomy and vaginal delivery has been reported, most pregnancies with transabdominal cervicoisthmic cerclage placement are delivered by cesarean section. At the time of cesarean section cerclage should be left in situ unless the woman has completed her family. We left

cerclage in situ in our patient as she desires further children. The higher success rate of transabdominal cerclage when compared with transvaginal sutures in certain women may be due to higher placement of the suture above the cardinal and uterosacral ligaments especially in patients with little intravaginal cervix.⁷ Despite the efficacy of transabdominal cervicoisthmic cerclage in a highly selected group of patients, some authors believe it has several disadvantages, such as the need for 2 intra-abdominal procedures in a highly vascular area leading to complications.⁸ The need for 2 abdominal operations during a successful pregnancy cannot be avoided but in our case there have been no major operative or post-operative complications, although heavy bleeding has been reported.⁹ Due to intra-abdominal placement of the suture there may also be less ascending infection during pregnancy after colonization of the suture which frequently occurs after transvaginal cerclage. Transabdominal cervicoisthmic cerclage is a procedure, which should not be undertaken lightly as it carries high risk of morbidity. However, it has a definite place in the obstetric management of a subgroup of women with cervical incompetence.

References

1. Shirodkar VN. A new method of operative treatment for habitual abortion in the second trimester of pregnancy. *Journal of Antiseptic* 1955; 52: 299-300.
2. McDonald IA. Suture of the cervix for inevitable miscarriage. *Journal of Obstetrics and Gynaecology British Empire* 1957; 64: 346-350.
3. Benson RC, Durfee RB. Transabdominal cervicouterine cerclage during pregnancy for the treatment of cervical incompetency. *Obstet Gynaecol* 1965; 25: 145-155.
4. Novy MJ. Transabdominal cervicoisthmic cerclage: A reappraisal 25 years after its introduction. *Am J Obstet Gynaecol* 1991; 164: 1635-1642.
5. Gibb DMF, Salaria DA. Transabdominal cervicoisthmic cerclage in the management of recurrent second trimester miscarriage and preterm delivery. *Br J Obstet Gynaecol* 1995; 102: 802-806.
6. Mahran M. Transabdominal cerclage during pregnancy: A modified technique. *Obstet Gynaecol* 1978; 52: 502-506.
7. Watkins RA. Transabdominal cervicouterine suture. *Aust N Z J Obstet Gynaecol* 1972; 12: 62-64.
8. Cousins L. Cervical incompetence: a time for reappraisal. *Clin Obstet Gynaecol* 1980; 23: 467-479.
9. Herron MA, Parer JT. Transabdominal cerclage for fetal wastage due to cervical incompetence. *Obstet Gynaecol* 1988; 71: 865-867.