Case Report

Sickle cell disease and cystic fibrosis

Hanaa H. Banjar, MD, FRCPC.

ABSTRACT

Simultaneous occurrence of both cystic fibrosis and sickle cell disease in the same patient is a rare phenomenon and has occurred only in 3 reports in the world literature. This phenomenon has never been described before in Arab population. In this report, we describe the first reported case of both diseases in one patient in the Arab population, and discuss its complications and review the literature in this aspect.

Saudi Med J 2003; Vol. 24 (1): 97-100

Sickle cell disease is an autosomal recessive disorder due to a point mutation in amino acid position 6 of beta-golbin (E6V) which results in a change from glutamic acid to valine. It occurs most commonly in blacks, but is also present in nonblack populations in the Mediterranean region, the Indian subcontinent, the Caribbean region, and Central America. It is one of the most common genetic diseases in African Americans, with an estimated incidence of one in 625 live births, corresponding to a gene frequency of 8%.[1] Cystic fibrosis (CF), also an autosomal recessive disease, is the most common hereditary disease in the caucasian population, with an incidence in the United States of America (USA) of one in 4,100 live births and an estimated gene frequency of 3%. Cystic fibrosis is less common in black American and Hispanic populations with a recorded occurrence of 1:14,000 and 1:11,000 live births, and estimated gene frequencies of 1.7% and 1.9%.[1] Cystic fibrosis has been reported before in the Kingdom of Saudi Arabia (KSA).[2-5] The incidence of CF has been estimated to be 1:4243 live birth.[5] The incidence of hemoglobulin S for all KSA neonates that were screened in one study[6] was 14.4% and ranged from 0.8% in Najran to 26.4% in Al-Qurayyat, KSA. Hemoglubin S disease was present in 1.4% and sickle cell trait in 13.1% of all infants.[6] In this report, we describe the first case of simultaneous occurrence of both diseases CF and sickle cell SS disease in the same patient and discuss the course of the disease and review the literature in this subject.

Case Report. A male patient presented at a local hospital at 2.5-year-old with a history of recurrent chest infections, vomiting, diarrhea, profuse sweating since 2-months of age and occasionally passing blood with urine with dysuria. He was diagnosed with SS disease at 2-months of age and required repeated blood transfusions (BT) due to veno-occlusive crisis. He was found to have hypochloremic, hypokalemic metabolic alkalosis. He was treated with intravenous (I.V.) hydration and antibiotics and was sent to our tertiary care center for further evaluation. He was a product of cesarean section secondary to breach presentation. Family history was significant in that both parents are first cousins. An uncle and an aunt have SS disease and required repeated BT. One niece died at 2 years of age with CF in a local hospital and another niece diagnosed at 6-month of age with CF and SS disease but refused to come for evaluation to our center. On arrival to our hospital, the patient looked mildly pale, well hydrated, and in no respiratory distress. He had a congested nose with postnasal drip. He had joint swelling of both knees with tenderness. His respiratory rate 30 per minute, heart

From the Department of Pediatrics, King Faisal Specialist Hospital and Research Centre, Riyadh, *Kingdom of Saudi Arabia*.

Received 18th June 2002. Accepted for publication in final form 2nd September 2002.

Address correspondence and reprint request to: Dr. Hanaa Banjar, Department of Pediatrics, King Faisal Specialist Hospital and Research Centre, PO Box 3354, Riyadh 11211, *Kingdom of Saudi Arabia*. Tel. +966 (1) 4427761. Fax. +966 (1) 4427784. E-mail: hanaa@kfshrc.edu.sa

rate 120/min, blood pressure 96/63, temperature 36ºC, weight 13.5 kilogram, for age and height (Ht) was 89 cm, for age. The chest examination was clear, and the rest of physical examination was normal. Investigations: initial blood count showed white blood cells 8.7 (normal 4-11 x 10^9/litre). Hemoglobin (Hb) 98 (N 132-172g/L), Hematocrit 0.27 (N 0.38-0.5 Ratio), mean corpuscular volume 77 (N 80-94 fl), Platelet 306 (N 140-350 x 10^9/L), Retic % 4.3 (N<2%), and Retic count 159 (N 25-85 x 10^9/L). A picture of hypochromic microcytic anemia with high reticulocytes counts. Hemoglobin electrophoresis: Hb A1 level 3.3 (N 96-98%), HbF 22.9 (N 0.0-1%), Hb A2 0.0 (N 2.2-3.7%), and Hb S 64.8 (N 0.0-0.0). A picture of sickle cell disease. Electrolyte and liver profiles were normal. Calcium level 2.5 (N 2.1-2.6 mmol/l), urate was elevated 369 (N 60-240Mmol/L). Magnesium and phosphate levels were normal. Immunoglobulin (Ig) levels showed a picture of high IgG and IgA due to chronic infection, IgG 15.2 (3.5-12.4g/L). IgA 2.27 (N0.4-1.2g/L. Sweat chloride test by the quantitative method (Wescor, USA) In 2 occasions were positive of 106, and 104 (N<40mmol/L). Urinalysis showed a picture of hyper calciurea and hyper uricosurea. Calcium level 0.78 mmol/L, uric acid 2.89 mmol/L, Creatinine (Cr) 6 mmol/L, and oxalate level 0.45 mmol/L. Nasopharyngeal aspirate grew staphylococcus aureus that is resistant to Penicillin, but sensitive to Augmentin, Cefzolin and Cloxacillin. A chest x-ray showed mild peribronchial wall thickening, otherwise within normal limit **(Figure 1)**. Barium swallow showed intermittent gastresophageal reflux. Computerized tomography (CT) scan of sinuses showed opacities involve right maxillary and left ethmoid sinuses **(Figure 2).** Meta iodine benzyl guanidine scan of 99m technetium dimercapto succinic acid scan showed normal function. Screening for CF transmembrane regulator gene mutations (CFTR) showed the presence of the 2 pathogenic mutations; Novel Arab mutation H139L in exon 4 in the first allele and S549R mutation in exon 11 in the other allele (compound heterozygous).[7]

The patient was treated with IV hydration, IV ceftrioxone for 10 days and was sent home with proper education for both diseases and pancreatic enzymes, multivitamins, bacterim prophylaxis, folic acid hydrochlorothiazide as diuretics to improve hyperuricosurea and inhaled salbutamol and becotide 2 times per day. Six months later the patient was admitted to hospital with a history of loud snoring. The x-ray of lateral neck showed large adenoids that are obstructing the nasal passage. The patient had tonsillectomy and adenoidectomy with marked improvement of the clinical picture. Screening for both parents with hemoglobin electrophoresis showed both of them had sickle cell trait.

Discussion. Sickle cell anemia and cystic fibrosis are diseases with autosomal recessive inheritance. Since the b-globin gene cluster is on chromosome 11 and the CFTR gene is located on chromosome 7, there is little likelihood of linked inheritance under normal circumstances. The chances of these diseases coexisting in a person of black ancestry can be estimated to be (1/625) x (1/14,000) = (1/8,750,000), or 1.14 x 10-7.[1] This calculation assumes both diseases are inherited in an autosomal recessive pattern in which both parents contribute an abnormal allele for SS disease and CF to the child. If this theory applied to our case based on the incidence of both diseases in KSA, the incidence of CF/SS in one patient would be in the range of (1/4243) x (1/137)=1/581,291 live births, for example it will be a rare disease. Another possibility to explain the coexistence of these 2 nonlinked, inherited diseases is that of uniparental disomy. In this situation, the abnormal b-globin gene would be inherited in the usual manner, for example each parent would contribute a copy of chromosome 11 containing the abnormal gene, but both abnormal chromosomes 7 would be inherited from one parent; the reverse could also occur. Conceivably, both diseases could be transmitted by uniparental disomy.[8,9] This pattern of inheritance has not been reported to occur in SS anemia, but has been reported in one patient with CF. Another consideration is that there may have been considerable inbreeding, causing an increased frequency of occurrence of otherwise, uncommon alleles. Restrictive lung disease in children with SS anemia is thought to be result of either chronic pulmonary vasoocclusion or recurrent episodes of acute chest syndrome. Acute chest syndrome is characterized by chest pain, dyspnoea, pulmonary infiltrates on chest x-ray and, often, fever and an elevated white blood cell count a constellation of symptoms that can be difficult to distinguish from pneumonia.[10] Hypoxia in patients with CF is thought to be related to mucus plugging of the small airways, causing a ventilation/perfusion (V'/Q) mismatch. Most children with sickle cell disease are not hypoxic when they are otherwise well.[10,11] Hypoxia in sickle cell anemia increases the likelihood of irreversible sickling, with minor pulmonary vasoocclusion or an acute chest syndrome.[12] In addition, patients with SS disease who have had an acute chest syndrome are more likely to become hypoxic during sleep, thus increasing their chances for another vasoocclusive even.[12,13] In a patient with both diseases, the hypoxia associated with CF could increase the likelihood for irreversible sickling and pulmonary complications. This would increase V'/Q mismatch in the lung, causing increased hypoxia and is more likely to develop hypoxia at an earlier age and may have more severe pulmonary disease than a patient with either disease alone. For these reasons, it would seem reasonable to consider a chronic transfusion regimen for patients with both disorders.[12,13] This decision should be made carefully, after due consideration of the benefits and risks involved.[1] Patients with SS disease are at increased risk for infections with encapsulated bacteria. The most common infecting organisms in cystic fibrosis are *Staphylococcus aureus (S.aureus), Pseudomonas aeruginosa*, and unencapsulated *Hemophilus species*.

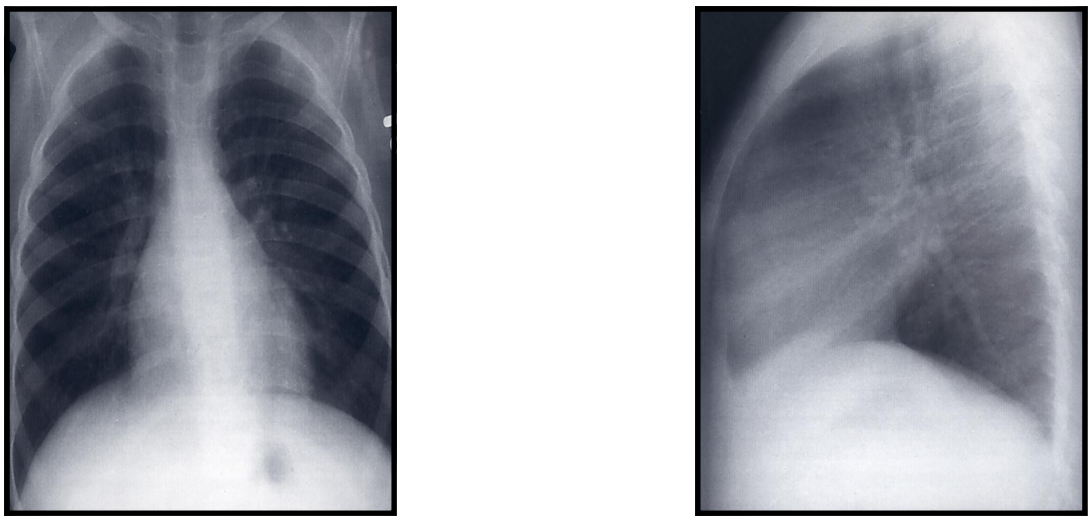

Figure 1 - Chest x-ray showing peri bronchial wall thickening.

Figure 2 - Computerized tomography of the para nasal sinuses showing complete opacification of the left ethmoid and the right maxillary sinuses.

Thus, in a patient with both disorders it is less likely that the pathogens common to one disease would significantly affect the course of the other disease.[1] Our patient has grown *S.aureus*, but not *Pseudomonas bacteria*, which is in favor of his benign lung disease. There have been 3 previous reports of patients with the combination of SS anemia and CF. Amendola et al[14] reported a 9-year-old black child with cystic fibrosis and a variant form of SS anemia, hemoglobin sickle cell hemoglobulin and hemoglobulin D-punjab disease. This child was started on a transfusion regimen at one year of age due to the rapidly progressive pulmonary disease; her pulmonary disease at time of publication was comparable to other children her age with cystic fibrosis alone. Porter et al[15] recorded the cases of 2 black children (22-months and 7-years-old) with CF and SS anemia (hemoglobin SS disease); neither seemed to have experienced an exacerbation of one disease that affected the other. In these 3 cases, as in our patient, the hematological disease did not exacerbate the course of pulmonary disease, once the hematological problem was recognized and treated. In addition, the course of cystic fibrosis pulmonary complications was not worsened by the hematological disease. The 3rd report[1] of an adolescent of black and Hispanic ancestry from the Dominican Republic with both diseases. This patient had normal pulmonary function test and was stable on cephlexin prohylaxis and inhaled albuterol with no apparent complication.[1]

The unusual co-occurrence of SS disease and CF prompts speculation regarding the pathophysiologic effects and treatment of both diseases in one child. Does the presence of SS disease ameliorate or worsen the course of CF? How does cystic fibrosis affect the course of SS disease? None of the previous 4 cases mentioned in the literature seem to have had any ill effects from this combination. Collaborative efforts between pediatric hematologists and pediatric pulmonologists will be needed to find enough patients to answer these questions.

Our patient CFTR screening showed the presence of the 2 pathogenic mutations; Novel Arab mutation H139L in exon 4 in the first allele and S549R mutation in exon 11 in the other allele (compound heterozygous). So far this is the 2nd case of our CF patients that showed

the same mutations in both alleles. The result of Hb S screening showed HbS mutation (E6V) in both alleles (homozygous state). The incidence of both diseases to be seen simultaneously in the same patient will be in the range of 1 per 0.5 million live births in KSA.

Combination CF and SS disease is a rare phenomenon in KSA. Awareness of existence of both diseases should be increased, since SS disease is seen very frequently in pediatric clinic, and screening for coexistence with CF should be raised especially inpatient with SS disease and repeated chest infection. Coexistence of both diseases may not change the course of the disease, but the patient needs multiple medications and close follow-up.

References

1. Warwick AB, Haver K, Rosoff PM. Homozygous Sickle cell disease and cystic fibrosis in an adolescent. ***Pediatr Pulmonol*** 1998; 26: 224-227.
2. Kambouris M, Banjar H, Mogarri I, Nazer H, Al-Hamed M, Meyer BF. Identification of Novel Cystic Fibrosis Mutations in Arabs with CF: Their impact on the CFTR mutation detection rate in Arab population. ***Eur J Pediatr*** 2000; 159: 303-309.
3. Banjar H. Overview of Cystic fibrosis: patients aged 1-12 years in a tertiary care center in Saudi Arabia. ***Middle East Pediatrics*** 1999; 4: 44-49.
4. Banjar H, Mogarri I, Kambouris M. Geographic Distribution of Cystic Fibrosis Transmembrane Regulator Gene in Saudi Arabia. ***Ann Trop Paediatr*** 1998; 19: 71-75.
5. Nazer H, Riff E, Sakati N, Mathew R, Majeed MA, Harfi H. Cystic fibrosis in Saudi Arabia. ***Eur J Pediatr*** 1989; 148: 330-332.
6. Abu-Osba Y, Mallouh A, Salamah M, Hann R, Thalji A, Hamdan J et al. Comprehensive newborn screening program: Aramco experience. The national need and recommendations. ***Annals of Saudi Medicine*** 1992; 12: 235-240.
7. Change JC, Kan YW. Antenatal diagnosis of sickle cell anemia by direct analysis of the sickle mutation. ***Lancet*** 1981; 8256: 1127-1129.
8. Beaudet AL, Perciaccante RG, Cutting GR. Homozygous nonsense mutation causing cystic fibrosis with uniparental disomy. ***Am J Hum Genet*** 1991; 48: 1213-1215.
9. Spence JE, Perciaccante RG, Greig GM, Willard HF, Ledbetter DH, Hejtmack JF et al. Uniparental disomy as a mechanism of human genetic disease. ***Am J Hum Genet*** 1988; 42: 217-226.
10. Piasoni P, D'Souza SJ, Charge TD, Esseltine DE, Coates AL. Pulmonary function abnormalities in childhood sickle cell disease. ***J Pediatr*** 1993; 122: 366-371.
11. Needleman JP, Franco ME, Varlotta L, Reber-Brodecki D, Bauer N, Dampier C et al. Mechanism of nocturnal Oxyhemoglobin desaturation in children and adolescent with sickle cell disease. ***Pediatr Pumonol*** 1999; 28: 418-422.
12. D'Alya N. Sleep related upper airway obstruction and hypoxemia in sickle cell disease (letter). ***Arch Dis Child*** 1993; 68: 715-716.
13. Samuals MP, Stebbens VA, Davies SC, Picton-Jones E, Southall DP. Sleep related upper airway obstruction and hypoxaemia in sickle cell disease. ***Arch Dis Child*** 1992; 67: 925-929.
14. Amendola G, Garvin J, Piomelli S. Cystic fibrosis in a black child with hemoglobin S-D disease. ***Am J pediatr Hematol Oncol*** 1990; 12: 340-342.
15. Ronald C, Porter MD, Michelle M, Cloutier MD, Dana M, Brasfield MD. Cystic fibrosis in two black children with sickle cell anemia. ***J Pediatr*** 1979; 94: 239-240.