

# Gemella morbillorum endocarditis

Hussam Al Soub, MD, CABM, Sittana S. El-Shafie, MD, FRCPath, Abdel-Latif M. Al-Khal, MD, FACP, Amar M. Salam, MBBS, MRCP(UK).

## ABSTRACT

A case of *Gemella morbillorum* (*G.morbillorum*) endocarditis of the mitral valve in a patient with previously normal heart valves is reported. The presentation was subacute, and the infection was complicated by perforation of the posterior mitral leaflet that necessitated valve repair. *Gemella morbillorum* infections are uncommon, and endocarditis is the most common presentation. *G.morbillorum* endocarditis is probably under recognized, and has not been reported from our region. The case is described, and problems in the identification of the organism are discussed.

Saudi Med J 2003; Vol. 24 (10): 1135-1137

*Gemella morbillorum*, (*G.morbillorum*) previously known as *streptococcus morbillorum*, was reclassified into the genus *Gemella* in 1988 on the basis of deoxyribonucleic acid hybridization.<sup>1</sup> This anaerobic or microaerophilic gram positive coccus is a normal inhabitant of the gastrointestinal and genitourinary tracts in humans.<sup>2</sup> Infections caused by this organism are uncommon. It has been implicated as the causative agent of a variety of infections including endocarditis, meningitis, arthritis, sinusitis, septicemia and septic shock, and intracranial and other abscesses.<sup>3</sup> Infective endocarditis has been reported as the most common infection caused by *G.morbillorum*.<sup>4</sup> We herein describes a case of infective endocarditis due to *G. morbillorum* in an adult patient with a previously normal mitral valve.

**Case Report.** A 41-year-old female Sri Lankan was admitted to Hamad General Hospital, Qatar in February 2001, with the complaints of fever, chills, headache, and vomiting of 6 weeks duration. She had no cough, shortness of breath, or chest pain. She had no previous history of cardiac disease, or recent dental work, and her past medical history was unremarkable. Physical examination revealed a temperature of 38.2°C,

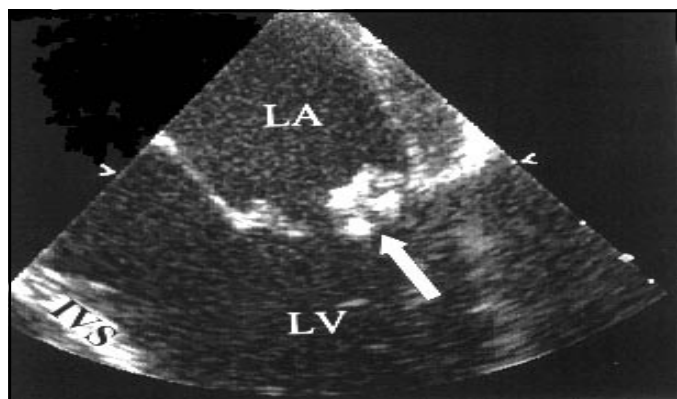
blood pressure 110/70 mm Hg, pulse rate 96/minute, respiratory rate 20/minute, and a poor dental condition evidenced as caries and periodontal disease. Examination of the heart revealed normal first, and second heart sounds, and ejection systolic murmur at the left sternal edge. Otherwise, physical examination was unremarkable. Laboratory investigations revealed, hemoglobin 12.8 gm/dL, white blood cell count 11,400/mm<sup>3</sup> (86% neutrophils, 9% lymphocytes, 4% monocytes, and 1% eosinophiles), platelets 279,000/mm<sup>3</sup>, erythrocyte sedimentation rate 50 mm/h. Liver, renal function tests, urine microscopy, and chest radiograph were normal. Human immunodeficiency virus. Enzyme linked immunosorbent assay test was negative. Electrocardiogram showed inverted T wave in V1-V3. Five sets of blood cultures grew *G.morbillorum*. The organism grew as alpha hemolytic colonies identified both by Vitek 2 machine and API Strept (bioMérieux France). Antimicrobial susceptibility testing was carried out by E test (AB Biodisk, Sweden). The results of minimum inhibitory concentrations (MIC) were as follows: Penicillin: 0.012 µg/L, ampicillin: 0.023 µg/L, ceftriaxone: 0.047 µg/L, erythromycin: 0.023 µg/L, vancomycin: 0.75 µg/L, and gentamicin=32 µg/L. Sensitivity for amikacin was not carried out.

From the Department of Internal Medicine (Al Soub, Al-Khal), Department of Pathology and Laboratory Medicine (El-Shafie), Department of Cardiology and Cardiovascular Surgery (Salam), Hamad Medical Corporation, Doha, Qatar.

Received 23rd February 2003. Accepted for publication in final form 30th June 2003.

Address correspondence and reprint request to: Dr. Hussam Al Soub, Hamad Medical Corporation, PO Box 3050, Doha, Qatar. Fax. +974 4392273. E-mail: hussamsoub@yahoo.com

According to the National Committee of Clinical Laboratory Standards (NCCLS), the organism was sensitive to all drugs except for gentamicin. Transthoracic and transesophageal (TEE) echocardiograms both revealed a 0.9 x 0.6 cm mobile vegetation attached to the atrial surface of the posterior mitral leaflet, and mild mitral regurgitation (Figure 1). A diagnosis of *G.morbillorum* endocarditis was made, and the patient was started on intravenous penicillin 3 million units every 4 hours, and gentamicin 80 mg every 8 hours. Gentamicin was added to the treatment regimen in spite of the high MIC value to provide synergy with penicillin. She became afebrile one day after starting antibiotics. Repeat blood culture 5 days after starting antibiotics was sterile. She had a smooth hospital course. Gentamicin was stopped after 2 weeks, and penicillin was given for a total of 4 weeks. Repeat transesophageal echocardiogram (TEE) before discharge did not reveal a significant change in the size of vegetation. She was discharged home in March in good condition to be followed up in the clinic. Seven months after discharge she started to complain of exertional dyspnea. Repeated TEE revealed residual vegetation on the posterior mitral leaflet, with perforated posterior mitral leaflet, severe mitral regurgitation, and left atrial enlargement. She was readmitted to the hospital, after 9 months for mitral valve repair. The perforated posterior mitral leaflet was sutured. She made an uneventful recovery and was discharged home on the 10th hospital day. During her follow up in the clinic she continued to be well with no complaints. Her last clinic visit was in January 2003.



**Figure 1** - Transesophageal echocardiography (4-chamber view with zoom in on the mitral valve) showing vegetation (arrow) to the posterior mitral valve leaflet. LA - left atrium, LV - left ventricle, IVS - interventricular septum.

resistance to aminoglycosides, and show synergy between penicillin or vancomycin and gentamicin.<sup>11</sup> Tolerance and even resistance to penicillin including high grade resistance has been occasionally reported.<sup>2</sup> A combination of penicillin and gentamicin is recommended for the treatment of *G.morbillorum* endocarditis, however if resistance to penicillin has been found then vancomycin is the recommended treatment.<sup>2</sup> Although the prognosis of *G.morbillorum* endocarditis is considered good, serious complications may occur including severe valve damage necessitating valve replacement.<sup>11</sup> Other complications that have been reported include embolization, mycotic aneurysm, arthritis, appendicitis and toxic shock syndrome.<sup>2,5</sup> Only one death occurred in the reported cases. In the present case, it caused damage of the posterior mitral leaflet that required repair later. Our case occurred in a patient without known predisposing valvular disease, demonstrating the ability of this organism to attack normal valves.

We believe that the portal of entry of *G.morbillorum* in our patient was the dental route. Other sites that served as portal of entry of *G.morbillorum*, and were reported in the literature are gastrointestinal manipulation or disease and intravenous drug abuse.<sup>5,12,13</sup> Our patient is the first case of *G.morbillorum* endocarditis seen in our hospital and to our knowledge is the first case reported from the Gulf region. This conforms to the international literature that this is a rare or under recognized condition. We report this case to alert physicians and microbiologists in our region and elsewhere of this treatable but serious condition. Due to its propensity to attack heart valves including normal valves, and since infective endocarditis has been the most frequently reported infection caused by *G. morbillorum*, we recommend cardiac evaluation including an echocardiogram in all patients with *G.morbillorum* bacteremia.

**Discussion.** *Gemella morbillorum* is a rare cause of infective endocarditis. A review of the literature revealed only 18 cases of *G.morbillorum* endocarditis.<sup>5-7</sup> Two additional cases of *G.morbillorum* endocarditis have been recorded among 52 apparent treatment failures of endocarditis,<sup>8</sup> and 8 cases have been recorded among 364 cases of streptococcal endocarditis.<sup>9</sup> *Gemella morbillorum* endocarditis is probably under reported due to problems in its identification. *Gemella* species are gram positive, however during Gram staining, cells are easily decolorized and may appear gram negative.<sup>4</sup> It is likely that Gram staining abnormality and morphological polymorphism are responsible for the misidentification of *Gemella* species and thus, perhaps for the fact that so few cases of *Gemella* infection are reported. They may also be more involved in clinical disease than presently recognized, as they can be incorrectly identified as viridans group streptococci or left unidentified.<sup>4</sup> Endocarditis due to *G.morbillorum* is usually associated with poor dental state and previous damaged cardiac valves.<sup>4</sup> Both native and prosthetic valves are affected and left-sided disease predominates.<sup>10</sup> The clinical features of *Gemella morbillorum* endocarditis resemble that of viridans streptococcal endocarditis.<sup>5</sup> Most isolates are highly susceptible to penicillin G, have low-level

## References

1. Klipper-Baltz R, Schleifer KH. Transfer of *Streptococcus morbillorum* to the genus *Gemella* as *Gemella morbillorum* comp.nov. *Int J Syst Bacteriol* 1988; 38: 442-443.
2. Vasishtha S, Isenberg HD, Sood SK. *Gemella morbillorum* as a cause of septic shock. *Clin Infect Dis* 1996; 22: 1084-1086.
3. Debast SB, Koot R, Meis CA. Infections caused by *Gemella morbillorum*. *Lancet* 1993; 342: 560.
4. La Scola B, Raoult D. Molecular identification of *Gemella* species from three patients with endocarditis. *J Clin Microbiol* 1998; 36: 866-871.
5. Farmaki E, Roilides E, Darilis E, Tsivitanidou M, Panteliadis C, Sofianou. *Gemella morbillorum* endocarditis in a child. *Pediatr Infect Dis J* 2000; 19: 751-753.
6. Akiyama K, Taniyasu N, Hirota J, Iba Y, Maisawa K. Recurrent aortic valve endocarditis caused by *Gemella morbillorum*: report of case and review of literature. *Jpn Circ J* 2001; 65: 997-1000.
7. Espinosa-Villarreal JG, Gonzalez-Reimers E, Lecuona M, Rodriguez-Gaspar M, Lopez-Lirola AM, Rodriguez-Moreno F et al. Endocarditis caused by *Gemella morbillorum*. *Enferm Infecc Microbiol Clin* 2000; 18: 293.
8. Durack DT, Kaplan EL, Bisno AL. Apparent failures of endocarditis prophylaxis. Analysis of 52 cases submitted to a national registry. *JAMA* 1983; 250: 2318-2322.
9. Facklam RR. Physiological differentiation of viridans streptococci. *J Clin Microbiol* 1977; 5: 184-201.
10. Holland J, Wilson R, Cumpston N. *Gemella morbillorum* "prosthetic" valve endocarditis. *N Z Med J* 1996; 109: 367.
11. Lopez-DuplaM, Creus C, Navarro O, Raga X. Association of *Gemella morbillorum* endocarditis with adenomatous polyps and carcinoma of the colon: case report and review. *Clin Infect Dis* 1996; 22: 379-380.
12. Bell E, McCartney AC. *Gemella morbillorum* in an intravenous drug abuser. *J Infect* 1992; 25: 110-112.
13. Maxwell S. Endocarditis due to *Streptococcus morbillorum*. *J Infect* 1989; 18: 67-72.