

# Bilateral simultaneous hip fractures secondary to an epileptic seizure

Mustafiz M. Rahman, FRCS, Adnan Awada, MD.

---

## ABSTRACT

A 30-year-old man sustained bilateral simultaneous displaced subcapital fractures of neck of femur during an epileptic tonic-clonic seizure. After admission to the hospital approximately 18 hours later, internal fixation of the fractures with dynamic hip screw was undertaken. Post operatively, he was managed by early motion and weight bearing on the second day. Despite the severity of the fractures and delayed surgery, satisfactory union of the fractures was noted at 6 months when bone densitometry was normal. At 3 years follow up, there was no sign of avascular necrosis of the femoral heads.

Saudi Med J 2003; Vol. 24 (11): 1261-1263

---

Common musculoskeletal injuries resulting from seizures include vertebral fractures and shoulder fracture-dislocations. There have been few reports on bilateral fractures of hip following convulsion, but simultaneous bilateral femoral neck fractures by such a mechanism are extremely rare. We report the case of a young man who sustained this rare injury following seizure.

**Case Report.** A 30-year-old epileptic man awakened in the early morning with severe bilateral hip pain and could not rise from his bed. He also had general muscle aches and headache similar to that, which is often experienced after a generalized tonic-clonic seizure. He lived alone and was not discovered until late in the evening and was brought to the hospital at approximately 10 p.m. On examination, there was no evidence of external trauma. Both legs were externally rotated at the hips but there was no distal neurological or vascular deficit. An x-ray of the pelvis showed Garden, type 4 subcapital fractures of both femoral necks (**Figure 1**). This man was a known epileptic since the age of 15 and his seizures consisted

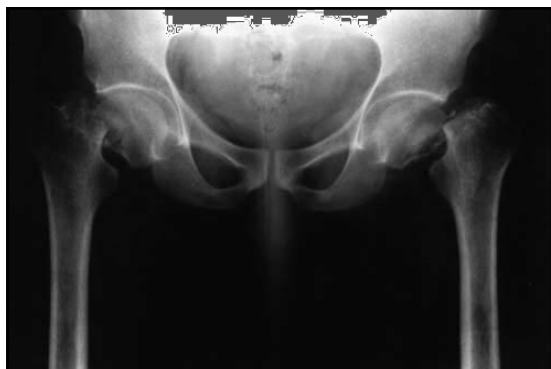of daily early morning myoclonus and occasional generalized tonic-clonic seizures. He was treated by valproic acid at 500 mg twice daily but was not compliant to his medications. He was off treatment for about 3 months when he presented. Valproic acid was not detectable in the serum at presentation. He was operated upon within 2 hours of admission. Both fractures were reduced by closed manipulation and then internally fixed by the dynamic hip screw and plate system. For maximal purchase in the femoral head, the screws were advanced right up to the subchondral bone. Postoperatively, the patient was allowed to move the legs freely in bed and after 2 days he was mobilized with frame support, weight bearing as able. On the 12th postoperative day he was discharged home walking full weight bearing with 2 elbow crutches. He walked without any aid at 3 months and at one year he was completely free of any pain and had regained full range of movements in both hips. X-rays showed that the fractures had healed by 6 months when bone densitometry was normal. At 3 years there was no sign of avascular necrosis of the femoral heads (**Figures 2a & 2b**). For prevention of

---

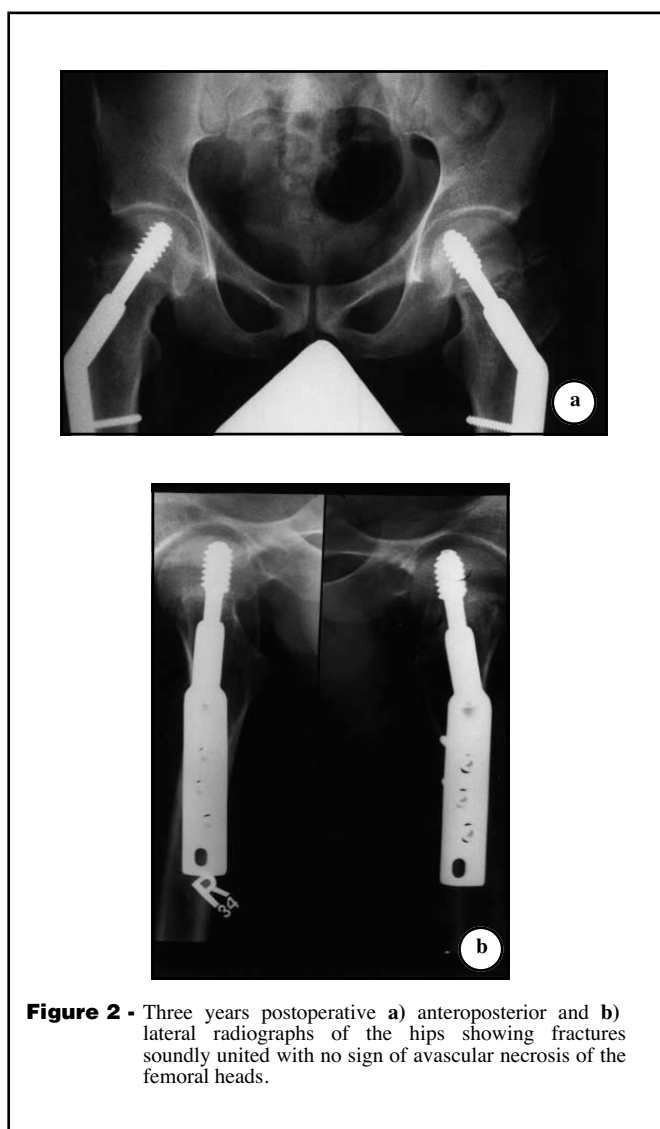
From the Sections of Orthopedics (Rahman) and Neurology (Awada), King Fahad National Guard Hospital, Riyadh, Kingdom of Saudi Arabia.

Received 5th March 2003. Accepted for publication in final form 9th August 2003.

Address correspondence and reprint request to: Dr. Mustafiz M. Rahman, Department of Surgery, King Khalid National Guard Hospital, PO Box 9515, Jeddah 21423, Kingdom of Saudi Arabia. Tel. +966 (2) 6240000. Fax. +966 (2) 6240000 Ext. 2071. E-mail: docrahman@yahoo.com



**Figure 1** - Anteroposterior radiograph of both hips showing bilateral femoral neck fractures.



**Figure 2** - Three years postoperative a) anteroposterior and b) lateral radiographs of the hips showing fractures soundly united with no sign of avascular necrosis of the femoral heads.

further attack of seizure the patient was kept on valproic acid before and after surgery and was operated under general anesthesia, which is the most powerful anti-epileptic treatment. Valproic acid is known to be the best treatment of juvenile myoclonic epilepsy, which does not disappear with time; hence, it was emphasized to the patient that to avoid similar injuries, he should take this medicine without interruption for the rest of his life.

**Discussion.** Epileptic patients are prone to a range of injuries during their tonic-clonic seizures. Bilateral simultaneous hip fractures secondary to epileptic seizures are however, rare and have been reported mainly in patients with osteoporosis and osteomalacia.<sup>1-3</sup> Our patient was a young, otherwise healthy man and his bone densitometry performed 6 months after the injury was normal. In addition, he was on valproic acid, which is less likely to provoke osteomalacia than phenytoin or carbamazepine, and he was not compliant with his medication. Juvenile myoclonic epilepsy is characterized by early morning myoclonus and occasional generalized tonic-clonic seizures.<sup>4</sup> It is likely that he had one or more generalized tonic-clonic seizures on the morning of presentation.

Bilateral femoral neck fractures occurring after seizures in patients with normal bones are rare. Two cases reported in the literature included one that occurred during lumbar myelography and the other caused by convulsions secondary to hypocalcemia.<sup>5,6</sup> These patients were not epileptic and one of them was described as athletic. Injury to the hips appears to be due to uncontrolled violent contractures of the muscles about the proximal thigh generating powerful force directed towards the groin.<sup>7</sup>

The point of interest in this case was the absence of avascular necrosis despite the displacement and long time (20 hours) between the fracture and the operation. In a meta-analysis of 106 published reports of displaced femoral neck fractures, Lu-Yao et al reported a 33% incidence of non union and 16% incidence of avascular necrosis.<sup>8</sup> Active mobilization results in rapid return of blood supply to both the bone and soft tissues and improves articular cartilage nutrition; and when combined with weight bearing, it greatly decreases post traumatic osteoporosis and enhances bone formation.<sup>9</sup> It is likely that accurate reduction and stable fixation of the fractures followed by early weight bearing have together resulted in excellent clinical and radiological outcome in our patient.

## References

1. Sakai S, David D, Shoji H, Stenzel KH, Rubin AL. Bone injuries due to tetany or convulsions during hemodialysis. *Clin Orthop* 1976; 118: 118-123.
2. Vanderhooft E, Swiontkowski M. Bilateral femoral neck fractures following a grand mal seizure. *Ann Emerg Med* 1994; 24: 1188-1191.

3. Haronian E, Silver JW, Mesa J. Simultaneous bilateral femoral neck fracture and greater tuberosity shoulder fracture resulting from seizure. *Orthopedics* 2002; 25: 757-758.
4. Obeid T, Panayiotopoulos CP. Juvenile myoclonic epilepsy. *Epilepsia* 1988; 29: 280-282.
5. Taminiau AHM, Slooff TJJH. Bilateral femoral neck fractures as a complication of myelography. *Acta Orthop Scand* 1980; 51: 621-624.
6. Ribacoba-Montero R, Salas-Puig J. Simultaneous bilateral fractures of the hip following a grand mal seizure. An unusual complication. *Seizure* 1997; 6: 403-404.
7. Rath E, Levy O, Liberman N, Atar D. Bilateral dislocation of the hip during convulsions. *J Bone Joint Surg [Br]* 1997; 79-B: 304-306.
8. Lu-Yao GL, Keller RB, Littenberg B, Wenberg JE. Outcomes after displaced fractures of the femoral neck. A meta-analysis of one hundred and six published reports. *J Bone Joint Surg* 1994; 76A: 15-25.
9. Perren SM. Basic aspects of internal fixation. In: Muller ME, Allgower M, Schneider R, Willenegger H, editors. Manual of internal fixation. 3rd ed. New York (NY): Springer-Verlag; 1991. p. 1-3.