Case Reports

Mesenteric cystic teratoma in children

Abdullatif A. Al-Arfaj, AF Chir, MD, *Mohammad A. El-Shawarby,* MD, PhD, *Fatma A. Al-Mulhim,* MBBS, KFUF, *Amer A. Lardhi.* CABP, MD.

ABSTRACT

Mesenteric teratoma is an extremely rare tumor, arising, akin all other teratomas, from totipotent primordial cells and displays a mixture of tissues of tridermal or bidermal origin. Two cases of mature mesenteric teratoma in a 5-month-old girl and a 4-month-old boy, the youngest reported in the literature, excluding a case recently diagnosed prenatally, are described. Diagnostic tools, differential diagnosis and management are also discussed.

Saudi Med J 2003; Vol. 24 (12): 1388-1390

Teratomas are neoplasms, displaying a mixture of tissues of tridermal origin (ectoderm, endoderm and mesoderm), foreign to the anatomic site, in which they arise. This definition newly became less restrictive, and tissues of bidermal origin are also accepted.[1,2] Teratomas are usually found in the sacrococcygeal area (47.2%), in the gonads (31.6%) and less frequently in other sites such as neck, mediastinum, retroperitoneum, cranial cavity, nasopharynx and upper jaw.[1] Teratomas in the gastrointestinal tract and associated organs like stomach and pancreas are very rare, and there are only occasional case reports on mesenteric teratoma.[3-5]

We report 2 cases of mesenteric cystic teratomas in a 5-month-old girl and a 4-month-old boy. These are the youngest patients reported in the literature to have mesenteric teratoma, excluding a case with a prenatal ultrasonographic diagnosis recently reported.[4]

Case Report. ***Patient One.*** A 5-month-old Saudi girl was admitted to our service as a case of progressive abdominal distension, noticed initially at the age of 2.5 month. She was, otherwise, asymptomatic. On examination, the abdomen was massively distended with shiny skin, engorged dilated superficial veins and everted umbilicus. A huge cystic mass could be felt occupying the entire left abdomen and crossing the midline to the right. There were positive fluid thrill, and normal bowel sound. Computer tomography scan (CT) confirmed the presence of a cyst with solid components, displacing stomach and intestine to the right and extending down to the pelvis **(Figure 1)**. Intravenous pyelography revealed normal urinary system.

Exploration revealed a cystic mass, of roughly 16 centimeter (cm) diameter. The mass was surrounded by a thick fibrous capsule and was adherent to transverse mesocolon, gastrocolic ligament and mesenteric root, but the most devious adhesions were those, to the pancreatic capsule. The dissection ended up with a narrow pedicle originating at the upper margin of the pancreas, left to the portal vein, and measuring nearly one cm. The pedicle contained a moderate caliber artery, a vein and dense connective tissue; the artery was apparently arising from the superior mesenteric artery. The pedicle was double ligated by 3-0 silk and transected. The pathology showed a complex of cystic masses with solid components composed of mixtures of mature tissues, derived from all 3 embryonic layers **(Figure 2)**. She had a smooth postoperative recovery. However, she was readmitted, 6 months later, with adhesive

From the Division of Pediatric Surgery (Al-Arfaj), Department of Pathology (El-Shawarby), Department of Radiology (Al-Mulhim), Department of Pediatrics (Lardhi), College of Medicine, King Faisal University, Dammam, *Kingdom of Saudi Arabia*.

Received 18th May 2003. Accepted for publication in final form 9th August 2003.

Address correspondence and reprint request to: Prof. Abdullatif A. Al-Arfaj, PO Box 20325, Al-Khober 31952, *Kingdom of Saudi Arabia*. Tel. +966 (3) 8829180. Fax. +966 (3) 8877758. E-mail: aalarfajsa@yahoo.co.uk

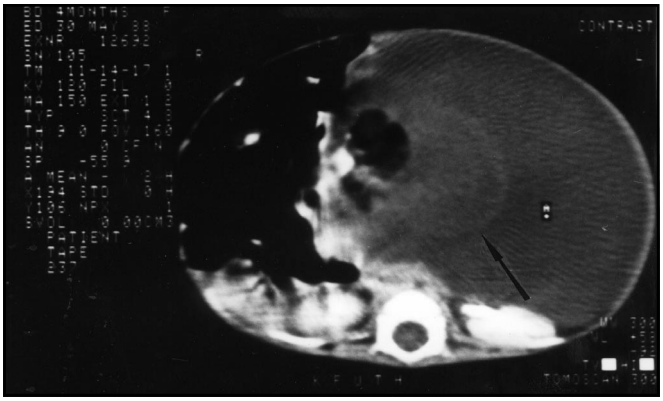

Figure 1 - Computer tomogram depicting a huge cyst with a solid component (arrow), occupying the entire left side of the abdomen. Stomach and intestine are displaced to the right.

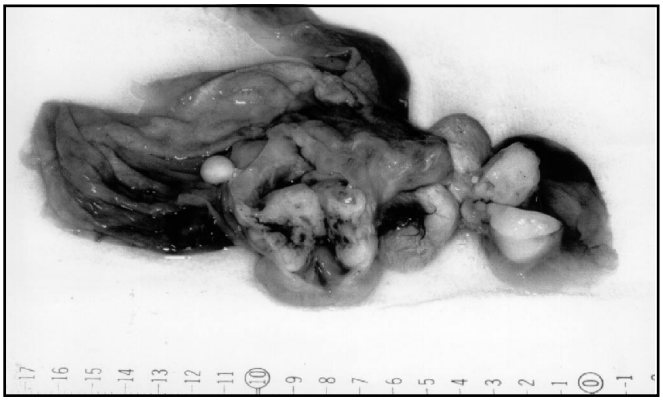

Figure 2 - Photograph of first case specimen, demonstrating the gross pathology after opening all the cystic and solid structures.

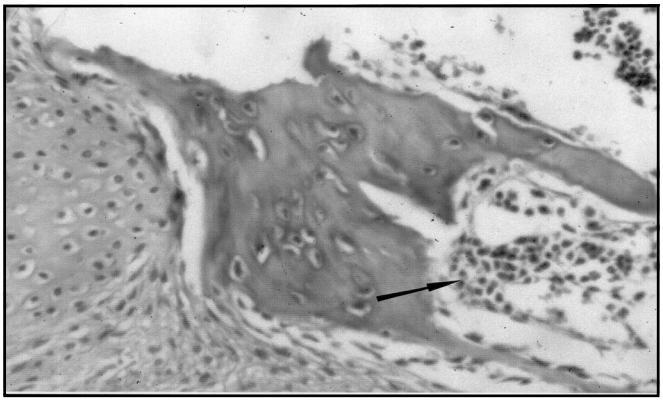

Figure 3 - Microphotograph illustrating cartilage (light color), undergoing enchondral ossification (dark). Note bone marrow spaces (arrow).

intestinal obstruction, necessitating division of adhesive bands. She is now 14 years after her second surgery, and well.

Patient 2. A 4-month-old Saudi boy was admitted as of progressive intermittent vomiting of 2 months duration. Constipation became evident 2 weeks prior to admission. An umbilical swelling gradually developed, but remained reducible. On examination, the abdomen was distended, with an umbilical hernia and a protruding left loin. Bowel sound was normal. Ultrasonographic imaging (U/S) revealed a cystic lesion in the left hypochondrium with a solid component. A non-ionic water-soluble contrast meal with follow through showed a mass with calcification, displacing the splenic flexure and the descended colon. The contrast bypassed unhindered to the rectum.

At exploration, a round and well encapsulated cystic mass of nearly 10 cm diameter was identified, residing in the left half of the transverse meso-colon and upper jejunal mesentery. The mass was bordered anteriorly by branches of the middle colic artery and posteriorly by the superior mesenteric artery. The latter provided 2 arteries, entering the dextroposterior aspect of the mass; one was double-ligated, using 3-0 silk, the other was too short and was divided flush to the tumor capsule. The resulting defect, in the wall of the mesenteric artery was sutured, using interrupted 5-0 prolene. The histology showed a cystic mass with a solid component surrounded by skin and composed of adipose tissue, skeletal muscle and cartilage undergoing enchondral ossification, bone with marrow spaces, glial tissue, nerve trunks and ganglia. All elements were described as mature **(Figure 3)**. He was discharged on the 5th postoperative day, and found in good health 6 months later.

Discussion. Teratomas are neoplasms arising from primordial germ cells. These primitive cells possess all the deoxyribonucleic acid (DNA) necessary for the evolution of any cell type, which explains the multiplicity of tissues encountered in teratomas.[2] Teratomas are classified according to their biologic behavior into mature, immature and malignant.

Teratomas have no pathognomonic signs or symptoms, and their clinical manifestation depends greatly on the size and location of the growth. The anatomy of the mesentery usually offers sufficient space for considerable growth before symptoms can appear, particularly when the lesion is located near the root. The more peripheral at the mesentery a lesion is located; the earlier symptoms may develop. They present frequently, as in both our cases, with a palpable mass or an increasing abdominal girth.[5,6] Nausea, vomiting or constipation is the result of intestinal compression by the mass as seen in the second case. An intractable chronic diarrhea as a manifestation has also been described.[5] Plain abdominal radiograph commonly demonstrates soft

tissue mass with calcification noted in nearly 60% of cases. This was evident in our second case. Ultrasound may show an image varying between predominantly cystic to predominantly solid mass with cysts. Also, septations of the cysts can usually be identified. However, calcification and fat tissue frequently can not be visualized in U/S. Therefore, CT is considered more suited to the diagnostic evaluation of gastrointestinal teratomas.[6] The differential diagnosis includes neuroblastoma hemangioendothelioma hepatoblastoma and hepatocellular carcinoma, but these tumors are usually solid. Nephroblastoma may be predominantly, and mesenteric lymphangioma is primarily cystic, but the first is intrarenal and the latter does not contain fat or calcification.[6] The preoperative diagnosis is important. Gastrointestinal teratomas are benign lesion and should undergo elective surgical treatment. The treatment of choice is complete excision; this is commonly achieved by enucleation.[3-5] Teratomas are normally well-encapsulated masses with a thick fibrous capsule, allowing mostly free dissection of the mass from adjacent structures, although dissection at selected critical areas may be demanding, as observed in both our cases. At times, aspiration of some of the fluid content of the mass may be crucial for safe dissection as observed fortuitously in our second case. Intestinal resection is needless. Based on the few reported cases, mesenteric cystic teratomas are benign tumors of low morbidity and excellent prognosis, once they are completely excised.

References

1. Tapper D, Lack EE. Teratomas in Infancy and childhood. A 54-year experience at the Children's Hospital Medical Center. ***Ann Surg*** 1983; 198: 398-410.
2. Tapper D, Sawin R. Teratomas and other germ cell tumors. In: O' Neil JA, Rowe MI, Grosfeld JL, Fonkalsrud EW, Coran A G, editors. Pediatr Surg. 5th ed. St Louis (MO): Mosby Year Book Inc; 1998. p. 447-459.
3. Naik R, Raghuveer CV. Benign cystic teratoma of mesentery. ***Indian J Pathol Microbiol*** 1993; 36: 151-153.
4. Marcolongo A, Divirgilio G, Bettili G, Camoglio FS, Fasoli L, Marradi P et al. Immature mesenteric teratoma in a male newborn infant: prenatal ultrasonographic diagnosis and surgical treatment. ***Prenatal diagnosis*** 1997; 17: 686-688.
5. Chiba T, Iwami D, Kikuchi Y. Mesenteric teratoma in an 8-month-old girl. ***J Pediatr Surg*** 1995; 30: 120.
6. Bowen B, Ros PR, McCarthy MJ, Olmsted WW, Hjermstad. Gastrointestinal teratomas: CT and US appearance with pathologic correlation. ***Radiology*** 1987; 162: 431-433.