

## Granular cell tumor of the esophagus

**Hiam M. Mohammed**, *MBBS, MRCP,*  
**Suliman S. Fedail**, *MD, FRCP,*  
**Ahmed M. Al-Hassan**, *PhD, FRC(Path).*

**G**ranular cell or Abrikossoff's tumors are rare type of tumors. They are mostly benign and usually asymptomatic. They are found in almost every organ. Its location in the esophagus is unusual, where most of them present as small, well-circumscribed lesions, which follow a benign course.

A 25-year-old man presented with heartburn and dysphagia. This was not accompanied with weight loss or any other significant symptoms. Clinical examination was unremarkable. Upper gastrointestinal endoscopy showed a benign looking 2 x 2 cm tumor at 30 cm in the esophagus (**Figure 1**). Linear esophageal erosions were also seen. Histopathology revealed granular cell tumor (GCT) of the esophagus (**Figure 2**). The patient was given proton pump inhibitors to control his reflux esophagitis, and the tumor was completely ablated by using argon beam plasma photocoagulation (APC) [EREBE, Germany]. The heartburn was attributed to the esophageal erosions but the dysphagia was most likely due to the GCT as it disappeared immediately after the tumor ablation by APC. The heartburn responded to the course of proton pump inhibitors. Follow-up several months later showed complete resolution of the lesion.

Granular cell tumor or Abrikossoff's tumor is purely descriptive term for a histogenetically heterogeneous group of neoplasm. They are either congenital or acquired. The histogenesis of GCT has been a source of controversy since its recognition as an entity by Abrikossoff in 1926. These lesions can virtually occur in any location.<sup>1</sup> Early suggestions says GCT may have a myoblastic origin that have been discounted and the use of the term granular cell myoblastoma as a designation

was discouraged. Others believe that GCT is not a specific entity, but rather a degenerative change that can occur in a variety of normal and neoplastic cells.<sup>1</sup> Granular cell tumor is mostly benign but associated with cancer in 11% of cases reported in the literature. The main morphological feature is the granularity of the cytoplasm which is caused by a massive accumulation of lysosomes<sup>1</sup> and conspicuous intracytoplasmic positivity for S100 protein.<sup>2</sup> These tumors are found predominantly in the head and neck region especially the tongue. Granular cell tumors of the esophagus are rare, approximately 2% of all cases.<sup>3</sup> Less than 200 cases of esophageal GCT have been reported. The tumor generally of neurogenic origin and it shows a malignant course in 2-4% of cases.<sup>4</sup> Esophageal GCTs are usually asymptomatic and found incidentally on the upper endoscopy that was carried out for other reasons. Most patients suffer from nonspecific symptoms; dysphagia occurs only with tumor size more than one cm.<sup>4</sup>

Endoscopy and biopsy are the mainstay in the diagnosis and endoscopic ultrasound can provide additional information on the origin and tumor extension. Cordoba et al<sup>4</sup> diagnosed a case of esophageal GCT using endoscopic brushing of the tumor.<sup>5</sup> No unanimity has been reached regarding management of these tumors. If the lesion is small, it can be removed using endoscopic strip biopsy. A case reported in Brazil had been treated successfully by endoscopic injection of dehydrated ethyl alcohol. Our patient had been treated successfully by using APC, which completely ablated the tumor. To the best of our knowledge, this is the first case to be treated as such. Large size tumors need surgical removal. Observation of these tumors is indicated unless the patient is symptomatic or the tumor is greater than one cm, and has atypical endoscopic, ultrasonographic, or histologic features.

In conclusion, Abrikossoff's tumor is a rare differential diagnosis of polypoid lesions of the esophagus. It has a benign course, usually diagnosed and treated endoscopically.

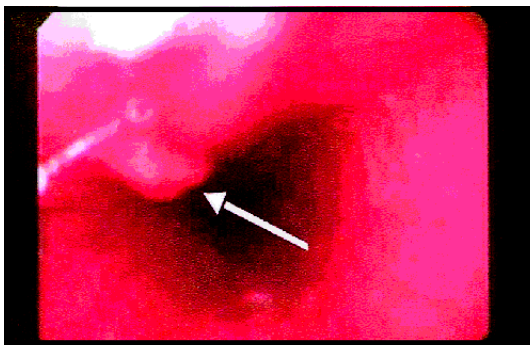


Figure 1 - An endoscopic view showing a benign looking tumor at 30 cm in the esophagus (arrow).

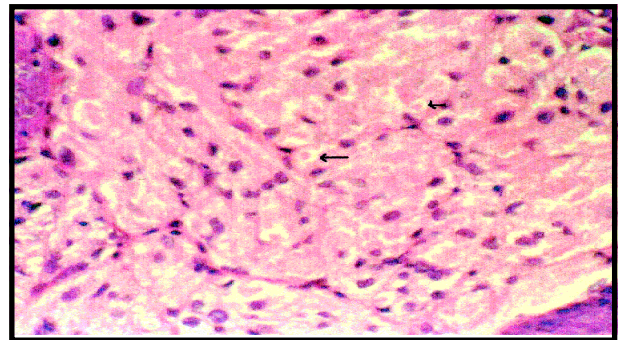


Figure 2 - Histopathology of the lesion in Figure 1 showing pale eosinophilic polygonal cells with cytoplasmic granules with a clear zone around (arrows). These are features of granular cell tumor. Hematoxylin and eosin x 40.

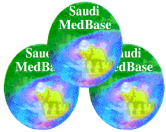
Received 12th October 2002. Accepted for publication in final form 20th January 2003.

From the Department of Gastroenterology (Mohammed, Fedail), National Centre for Gastrointestinal and Liver Diseases, Ibn Sina Hospital, Alamarat, Khartoum, and the Department of Pathology (Al-Hassan), Institute of Endemic Diseases University of Khartoum, Sudan. Address correspondence and reprint requests to: Dr. Hiam M. Mohammed, National Centre for Gastrointestinal and Liver Diseases, Ibn Sina Hospital, Alamarat, Khartoum, PO Box 8057, Sudan. Tel. +249 (12) 216996. Fax. +249 (11) 461796. E-mail: hiam278@hotmail.com

## References

1. Ordonez NG. Granular cell tumour: a review and update. *Adv Anat Pathol* 1999; 6: 186-203.
2. Pianzola HM, Ottino A, Corrons FJ, Herrero Ducloux K, Bello P. Granular cell tumour of the oesophagus. Morphological immunohistochemical study. *Acta Gastroenterol Latinoam* 2001; 31: 131-136.
3. Szigeti N, Horvath OP, Kassai G, Gomori E, Fabian G. Granular cell tumour of the oesophagus. *Orv Hetil* 2001; 142: 733-735.
4. Voskuil JH, van Dijk MM, Wagenaar SS, van Vliet AC, Timmer R, van Hees PA. Occurrence of granular cell tumour of the oesophagus in the Netherlands between 1988 and 1994. *Dig Dis Sci* 2001; 46: 1610-1614.
5. Cordoba A, Manrique M, Zozaya E, Martinez Penuela J, Gomez-Dorrnsoro et al. Granular cell tumour of the esophagus: report of a case with a cytologic diagnosis based on esophageal brushing. *Diagn Cytopathol* 1998; 19: 455-457.

## Related Abstract Source: Saudi MedBase



Saudi MedBase CD-ROM contains all medical literature published in all medical journals in the Kingdom of Saudi Arabia. This is an electronic format with a massive database file containing useful medical facts that can be used for reference. Saudi Medbase is a prime selection of abstracts that are useful in clinical practice and in writing papers for publication.

### Search Word: granular

**Authors:** S. Al-Qahtani  
**Institute:** King Khalid Eye Specialist Hospital, Riyadh, Zahran Al-Janoub Hospital, Abha, Kingdom of Saudi Arabia  
**Title:** Homozygous patient with granular corneal dystrophy: a case report  
**Source:** Saudi Journal of Ophthalmology 1996 October-December, 4: 170-173

### Abstract

A 4-year-old girl (the product of a first cousin marriage with both parents mildly affected by granular corneal dystrophy) presented with a severe case of granular corneal dystrophy. The patient reported an early onset with subsequent severe course of the disease with frequent epithelial defects. The patient is most likely to be homozygous for the dominantly inherited gene.