

Wandering spleen

Faisal M. Al-Mashat, FRCS (I & Ed), FICS, Abdulrahman M. Sibiany, FRCS (Ed), FICS, Abduraouf A. Maimani, ABNM, ABR, Fayad K. Alem, FACHARZT.

ABSTRACT

Congenital malformations of the spleen are rare. We report 3 cases of wandering spleen presented as abdominal or pelvi-abdominal mass. Two patients were suffering from chronic lower abdominal pain with thrombosed splenic pedicle and the third patient had an acute abdomen. All patients underwent splenectomies. Abdominal ultrasound, computerized tomography, Doppler ultrasound, and radioisotope studies were used to confirm the diagnosis. The clinical, diagnostic and treatment modalities are discussed.

Saudi Med J 2004; Vol. 25 (1): 91-94

Wandering spleen is a rare entity with a constant danger of splenic torsion leading to splenomegaly and infarction. It occurs consequent to an embryonal disturbance in the development of the ligaments connecting the spleen with the surrounding tissues.¹ It may be associated with other congenital or hereditary disorders. There is always a constant threat of torsion, infarction, rupture, infection or trauma.²⁻⁴ The diagnosis of this condition is very difficult due to the lack of specific clinical manifestations, and a high index of suspicion is required. Ultrasonography (US), computerized tomography (CT), magnetic resonance angiography, arteriography, scintigraphy and Doppler scanning are very useful tools for confirming the diagnosis.

Case Report. Patient one. A 28-year-old woman presented with recurrent attacks of lower abdominal pain for the last 3-4 months which on presentation were severe. The pain was stabbing in nature and was not associated with vomiting, fever or urogenital symptoms. On examination there was a tender, freely mobile, mid-abdominal mass measuring 8 x 10 cm. Her complete blood count was normal. Abdominal ultrasound revealed an empty splenic area and a homogenous, hypoechoic mass in the center of

abdomen highly suggestive of an ectopic spleen. A Doppler sonogram showed no blood flow in the hilum of the spleen consistent with torsion. At laparotomy, the mass was found to be a spleen located in the center of the abdomen and displacing the bowels. It had a long thrombosed pedicle which was pulling the tail of the pancreas inferiorly. Splenectomy was carried out. The spleen was found viable. The histopathological examination confirmed a normal spleen with thrombosed vascular pedicle. The patient had an uneventful postoperative recovery.

Patient 2. A 40-year-old woman presented with severe pain in the left hypochondrium of few days duration. There was no fever, vomiting or urogenital symptoms. On examination there was tenderness in the left hypochondrium and left renal angle. Abdominal ultrasound showed an empty splenic region and a 12 x 6 cm homogenous mass was replacing the absent left kidney. At laparotomy, the left kidney was absent and the mass was proved to be a spleen with thrombosed pedicle. Splenectomy was carried out. Histopathology revealed multiple infarcted areas. Post-operative period was uneventful.

Patient 3. A 65-year-old female patient was complaining of recurrent lower abdominal pain of 2 months duration. The pain was intermittent, stabbing

From the Department of Surgery (Al-Mashat, Sibiany), and the Department of Interventional Radiology (Maimani), King Abdul-Aziz University Hospital, College of Medicine, King Abdul-Aziz University and the Department of Surgery (Alem), King Abdul-Aziz University Hospital and Oncology Centre, Jeddah, Kingdom of Saudi Arabia.

Received 30th April 2003. Accepted for publication in final form 6th September 2003.

Address correspondence and reprint request to: Dr. Faisal M. Al-Mashat, PO Box 143, Jeddah, 21411, Kingdom of Saudi Arabia. Tel. +966 (2) 6066608. Fax. +966 (2) 6066607. E-mail: falmashat@yahoo.com

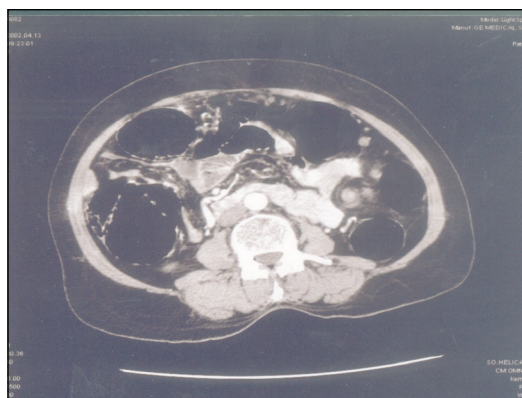

Figure 1 - Computerized tomography scan abdomen showing a twisted splenic pedicle

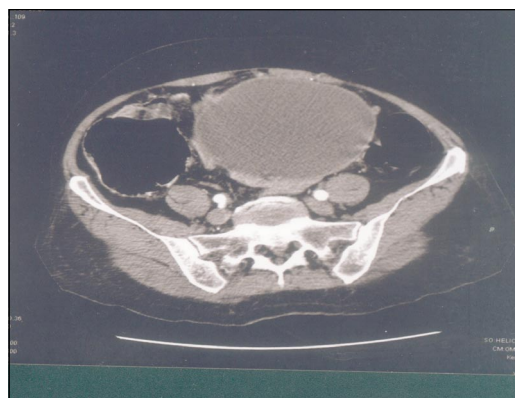


Figure 2 - Computerized tomography scan abdomen illustrating a hypodense totally infarcted wandering spleen.

and localized. There were no associated symptoms, history of abdominal trauma or urinary complaints. On examination, there was a pelvi-abdominal mass (10 x 15 cm). Her complete blood count, urea, creatinine, and electrolytes and blood clotting profile were within normal limits. Abdominal ultrasound revealed the spleen was not in its normal site. In the centre of the lower abdomen there is a splenic-shaped structure measuring 7 x 13 cm, showing multiple large irregular echolucent areas representing necrosis. The picture is highly suggestive of ectopic spleen with multiple infarctions. Color Doppler ultrasound showed no flow in the splenic artery or vein. The findings are those of wandering spleen with areas of infarctions. Liver scan (Tc-99m Tin colloid) showed homogenous uptake in the liver. There was no uptake in the spleen. Computerized tomography angiogram of the abdomen and pelvis demonstrated absence of the spleen from its normal location. There was a large pelvi-abdominal mass (9 x 12 x 14 cm). The mass was predominantly of fluid density and showed a thick enhancing capsule. At the left superior aspect of the mass there was a whorled appearance containing the splenic vessels, pancreatic tail and some peri-pancreatic fat (**Figure 1**). The mass was indenting the urinary bladder and loops of small bowel were adherent to it. This mass represents a wandering spleen with chronic torsion and infarction (**Figure 2**). Laparotomy was carried out. There was a large spleen in the lower abdomen surrounded by peri-splenic hematoma with thrombosed splenic vessels. The splenic pedicle was long and pulled down together with the pancreas. Loops of small bowel were adherent to the mass. Splenectomy was carried out. Histopathology revealed an infarcted spleen with peri-splenic hematoma. The patient had uneventful recovery and was discharged on the 9th post-operative day.

Discussion. Wandering spleen remains an elusive clinical diagnosis. It is a distinctive rare clinical

entity.⁵⁻¹⁷ It is characterized by a normal spleen with extreme mobility associated with an elongated pedicle.¹⁰ The condition results from congenital maldevelopment or acquired laxity of the spleen's suspensory ligaments.⁶ The ectopic spleen is usually located in the pelvis, the pelvi-abdominal region or rarely in the retroperitoneum.^{4,5,11,18,19} It usually occurs at 20-40 years of age and most cases are seen in women.¹² The clinical presentations include acute abdomen, chronic abdominal pain, thrombocytopenia or it may be asymptomatic.^{1,9-12,15,17,18,20-25} The acute and chronic abdominal pain are related to torsion, infarction or gangrene. The torsion is predisposed by the elongated splenic pedicle.^{7,9,10,25} The most common symptom is an acute surgical abdomen related to acute torsion of the ectopic spleen.¹⁰ The wandering spleen may be associated with Beckwith-Wiedemann syndrome, osteopetrosis, Gaucher disease, gastric volvulus, congenital diaphragmatic hernia, diaphragmatic eventration or epidermoid cyst.²⁶⁻³¹

The major concern in ectopic spleen is the development of complications. Many case reports have documented the occurrence of various complications in the wandering spleen. These include trauma, torsion, infarction, infection, subcapsular hematoma, obstructive uropathy, gastric outlet obstruction, duodenal obstruction, intestinal obstruction, herniation through a defect in the transverse colon or left-sided portal hypertension.^{2-4,32-39} The pre-operative diagnosis of this rare condition is often difficult.^{8,13,16} This difficulty is mainly attributable to lack of typical symptoms.⁸

Various diagnostic modalities are available to identify the spleen. These include US, CT, magnetic resonance imaging (MRI), scintigraphy, arteriography and Doppler ultrasound.^{5,6,8,21,25,27,32,38} Ultrasound, CT, MRI, arteriography and scintigraphy are extremely valuable.³⁸ Ultrasound plays a special role and is the elective diagnostic method.^{8,25} The sonographic appearance of the ectopic spleen is the presence of a

homogenous hypoechoic mass and empty splenic area, while CT shows a homogenous, unenhanced mass.^{5,6} The Doppler ultrasound has proven to be a useful tool indicating the presence or absence of blood flow in the splenic pedicle.^{5,6}

The treatment of the wandering spleen is controversial.³⁴ There are 2 lines in the treatment of this condition, conservative or surgical. A conservative approach with Doppler ultrasound follow-up can be offered to patients without symptoms.^{22,40} Surgical intervention is indicated for symptomatic patients and those who develop complications. Splenectomy should be considered for complicated cases only such as infarction, gangrene, subcapsular hematoma or absent splenic blood flow.^{12,18,41} Every effort should be practiced to preserve the spleen and splenopexy is the treatment of choice in symptomatic patients and in children.^{14,17,22,25,31} However, some surgeons may perform it for non-complaining patients.¹¹ Laparoscopic splenopexy is a state of the art. It is safe, feasible, minimally invasive, without impairing splenic function and is applicable even for adult splenomegalic wandering spleen.^{9-11,40,42,43} The hematological complications that may accompany the wandering spleen are reversed following splenectomy or splenopexy.^{4,10,20,24}

In conclusion, an ectopic spleen is a rare clinical entity and torsion remains an important differential diagnosis in patients presenting with acute abdomen. Early diagnosis is necessary to reduce the risk of complications. Awareness of the condition and the judicious use of appropriate imaging modalities can lead to the correct diagnosis. Splenopexy is the treatment of choice. However, in complicated cases splenectomy is a must.

Acknowledgment. We would like to express our thanks to Professor Mohammed Atwa for reviewing the manuscript and to Mrs. Joy Almeda De Silva for her secretarial help.

References

- Popovic M, Knezevic S, Colovic R, Petrovic M, Antunovic P, Djordjevic Z. Ectopic spleen: 2 case reports. *Acta Chir Iugosl* 1995; 42: 59-62.
- Andley M, Basu S, Chibber P, Ravi B, Kumar A. Internal herniation of wandering spleen: a rare cause of recurrent abdominal pain. *Int Surg* 2000; 85: 322-324.
- Horwitz JR, Black CT. Traumatic rupture of a wandering spleen in a child: case report and literature review. *J Trauma* 1996; 41: 348-350.
- Etcheverry R, Allamand JP, Guzman G, Robinson MI. Ectopic or migrating spleen and supernumerary spleens: detection and identification with ^{99m}Tc, ⁵¹Cr and ¹¹³In radioisotopes. *Rev Med Chil* 1989; 117: 1403-1408.
- Cobellis L, Di Pietto F, Di Pietto L, Stradella L, Reis FM, Severi FM, et al. Ultrasound diagnosis and Doppler monitoring of a pelvic spleen in pregnancy. *Ultrasound Obstet Gynecol* 2001; 17: 453-454.
- Danaci M, Belet U, Yalin T, Polat V, Nuro S, Selcuk MB. Power Doppler sonographic diagnosis of torsion in a wandering spleen. *J Clin Ultrasound* 2000; 28: 246-248.
- Swischuk LE, Williams JB, John SD. Torsion of wandering spleen: the whorled appearance of the splenic pedicle on CT. *Pediatr Radiol* 1993; 23: 476-477.
- Cendrowski K, Sawicki W, Stelmachow J, Wypych K. Ectopic spleen in pelvis minor: a case report. *Ginek Pol* 1992; 63: 312-314.
- Peitgen K, Majetschak M, Walz MK. Laparoscopic splenopexy by peritoneal and omental pouch construction for intermittent splenic torsion (wandering spleen). *Surg Endosc* 2001; 15: 413.
- Benoist S, Imbaud P, Veyrieres M. Reversible hypersplenism after splenopexy for wandering spleen. *Hepatogastroenterology* 1998; 45: 2430-2431.
- Cohen MS, Soper NJ, Underwood RA, Quasebarth M, Brunt LM. Laparoscopic splenopexy for wandering (pelvic) spleen. *Surg laparosc Endosc* 1998; 8: 286-290.
- Desai DC, Hebra A, Davidoff AM, Schnauffer L. Wandering spleen: a challenging diagnosis. *South Med J* 1997; 90: 439-443.
- Posillico LF, Shah AN. A wandering spleen. Detection by In-111 leukocyte imaging. *Clin Nucl Med* 1996; 21: 287-289.
- Maxwell-Armstrong CA, Clarke ED, Tsang TM, Stewart RJ. The wandering spleen. *Arch Dis Child* 1996; 74: 247-248.
- Marchena Gomez J, Gomez Guerra G, Catala Deniz L, San Jose Bouillon G, Hernandez JA, et al. Torsion of an ectopic spleen as a cause of acute abdomen. *Rev Esp Enferm Dig* 1990; 77: 445-448.
- Mukendi MP. Occlusive syndrome, ectopic spleen and malaria. A propos of a case report. *Acta Chir Belg* 1985; 85: 217-218.
- Riebel T, Lambrecht W, Amon O, Bromel T. Torsion of a wandering spleen. *Monatsschr Kinderheilkd* 1985; 133: 300-303.
- Lamesch P, Lamesch A. Anomalies of the position of the spleen in the child. Case report and review of the literature from 1896 to 1990. *Langenbecks Arch Chir* 1993; 378: 171-177.
- Vassilopoulos PP, Apostolikas NG, Papajoglou I, Tsoupis DJ. Ectopic spleen in the retroperitoneum. Case report. *Acta Chir Scand* 1990; 156: 655-658.
- Ravid A, Lev D, Makarin V, Klausner Y, Umansky M, Kluger Y. The wandering spleen syndrome. *Harefuah* 1999; 136: 366-368.
- Adamski A, Fornal P, Zrodowski W. Tumor in the minor pelvis: ectopic spleen. Case report. *Ginek Pol* 1997; 68: 384-385.
- Weijmer MC, Hondebrink Y, Strack van Schijndel RJ. A wandering spleen. *Ned Tijdschr Geneesk* 1998; 142: 1927-1929.
- Raissaki M, Prassopoulos P, Daskalogiannaki M, Magkanas E, Gourtsoyannis N. Acute abdomen due to torsion of wandering spleen: CT diagnosis. *Eur Radiol* 1998; 8: 1409-1412.
- Moll S, Igelhart JD, Ortel TL. Thrombocytopenia in association with a wandering spleen. *Am J Hematol* 1996; 53: 259-263.
- Barrios Fontoba JE, Lluna Gonzalez J, Gutierrez San Roman C, Font de Mora Lleo F, Cortina Orts H, Poquet Tormos J. Wandering spleen syndrome in childhood. *Cir Pediatr* 1997; 10: 79-81.
- Teomete U, Secil M, Goktay AY, Igci E, Dicle O. Ectopic spleen and left-sided vena cava in Beckwith-Wiedemann syndrome. *Comput Med Imaging Graph* 2002; 26: 177-180.
- Reisli I, Caliskan U, Tastekin G, Koc H, Acikgozoglul S, Aydogdu-kiresi D, et al. A case of osteopetrosis with pelvic ectopic spleen: an unusual association. *Turk J Pediatr* 2001; 43: 265-268.

28. Dweck A, Abrahamov A, Hadas-Halpern I, Zimran A, Elstein D. Wandering spleen in a young girl with Gaucher disease. *Isr Med Assoc J* 2001; 3: 623-624.
29. Pelizzo G, Lembo MA, Franchella A, Giombi A, D'Agostino F, Sala S. Gastric volvulus associated with congenital diaphragmatic hernia, wandering spleen and intrathoracic left kidney: CT findings. *Abdom Imaging* 2001; 26: 306-308.
30. Ratan SK, Grover SB, Kulsreshtha R, Puri V, Puri A. Left diaphragmatic eventration with a suprapubic spleen: a report of a case. *Surg Today* 2001; 31: 184-186.
31. Baglaj M, Czernik J. Epidermoid cyst in a wandering spleen. *Pediatr Surg Int* 1998; 14: 113-115.
32. Grenier N, Granger N, Calen S, Richard O, Boissinot F, Broussin J. Chronic volvulus of an ectopic spleen with subcapsular hematoma. CT x-ray aspect. *J Radiol* 1987; 68: 615-617.
33. Emir H, Yesildag E, Yeker Y, Soylet Y, Senyuz OF. A case of wandering spleen causing urinary symptoms after correction of a posterolateral diaphragmatic hernia. *Pediatr Surg Int* 2000; 16: 602-603.
34. Gurski RR, Schirmer CC, Fischer CA, Thofehn R, Osvaldt AB, Padoin A, et al. Laparoscopic approach to wandering spleen: a case report and an update to the question. *Surg Laparosc Endosc* 1998; 8: 363-365.
35. Nino-Murcia M, Friedland GW, Grass D. Imaging the effects of an ectopic spleen on the urinary tract. *Urol Radiol* 1988; 10: 195-197.
36. Ugolini G, Potenti FM, Pricolo VE. Gastric outlet obstruction secondary to wandering spleen. *Surgery* 2000; 128: 480-481.
37. Ng T, Lessin MS, Luks FI, Wallach MT, Wesselhoeft CW Jr. Wandering spleen presenting as duodenal obstruction after repair of congenital diaphragmatic hernia. *J Pediatr Surg* 1997; 32: 1790-1792.
38. Calik A, Bilgin Y, Kucuktulu U, Cinel A. Intestinal obstruction caused by splenic volvulus: report of a case. *Surg Today* 1996; 26: 704-706.
39. Angeras U, Almskag B, Lukes P, Lundstam S, Weiss L. Acute gastric hemorrhage secondary to wandering spleen. *Dig Dis Sci* 1984; 29: 1159-1163.
40. Haj M, Bickel A, Weiss M, Eitan A. Laparoscopic splenopexy of a wandering spleen. *J Laparoendosc Adv Surg Tech A* 1999; 9: 357-360.
41. Sarimurat N, Tekant GT, Huseyin S, Soylet Y, Senyuz OF. Wandering spleen in childhood: a report of three cases. *Surg Today* 1997; 27: 1086-1088.
42. Nomura H, Haji S, Kuroda D, Yasuda K, Ohyanagi H, Kudo M. Laparoscopic splenopexy for adult wandering spleen: Sandwich method with two sheets of absorbable knitted mesh. *Surg Laparosc Endosc Percutan Tech* 2000; 10: 332-334.
43. Hirose R, Kitano S, Bando T, Ueda Y, Sato K, Yoshida T, et al. Laparoscopic surgery for pediatric wandering spleen. *J Pediatr Surg* 1998; 33: 1571-1573.