Case Reports

Multidrug resistant miliary tuberculosis and Pott's disease in an immunocompetent patient

Ashok Shah, MD, Chandramani Panjabi, MD, Vikas Maurya, MD, Puneet Khanna, MD.

ABSTRACT

In a high tuberculosis (TB) prevalence country, mortality due to miliary TB is not unknown but the treatment outcome in general is good. We describe a previously healthy man with miliary TB who did not respond to 2-months antituberculous therapy with 4 drugs. Persistent complaints of backache, which antedated chest symptoms, resulted in a diagnosis of Pott's disease. Culture of bronchial aspirate yielded multidrug resistant *Mycobacterium tuberculosis* that responded slowly to streptomycin, ethionamide, cycloserine, clofazimine, ofloxacin, paraaminosalicylic acid and isoniazid. The association of multidrug resistant miliary TB with Pott's disease in an immunocompetent patient is yet to be highlighted.

Saudi Med J 2004; Vol. 25 (10): 1468-1470

In a high tuberculosis (TB) prevalence country, miliary mottlings seen on a chest radiograph are often presumed to be caused by miliary TB until proved otherwise. This stems from the fear of the many dangerous and varied complications of this hematogenously disseminated form of the disease. Furthermore, if timely and appropriate intervention is not effected, fatal consequences often result. However, miliary TB is highly amenable to treatment and prompt recognition followed by standard antituberculous therapy (ATT) ensures cure. With the advent of acquired immunodeficiency syndrome (AIDS), miliary TB is being seen more frequently especially with multiple drug resistance.[1,2] We present an immunocompetent patient who presented to us with multidrug resistant (MDR) miliary TB along with Pott's disease, the symptoms of which antedated respiratory complaints. The concomitant occurrence of miliary TB and Pott's disease is a rarely reported event.[3,4] Although MDR miliary TB has been reported in immunocompromised patients,[2] the absence of such a description in an immunocompetent patient prompted this report.

Case Report. A 57-year-old, non-diabetic, human immunodeficiency virus (HIV)-negative Indian male was referred to our institute for evaluation of a diagnosis of miliary TB not responding to 2-months standard ATT. His clinical course was characterized by low-grade fever and malaise along with cough and breathlessness for past 4-months. Anorexia, nausea and significant weight loss resulting in profound weakness were also recorded. A history of back pain radiating to the leg was elicited. This had commenced 2-months prior to respiratory symptoms. The patient was a non-smoker, a teetotaler and had no history of contact with a patient of TB. Physical examination revealed a poorly nourished patient with marked spinal tenderness from dorsal (D) 11 to lumbar (L) 1 vertebrae, and moderate limitation of spinal motion. Straight leg raising test was negative. On presentation, he was still on ATT.

Investigations including a chest radiograph showed miliary mottling which had coalesced, and suggested a marked deterioration since commencement of therapy. A computed tomogram (CT) of the thorax confirmed the presence of

From the Department of Respiratory Medicine, Vallabhbhai Patel Chest Institute, University of Delhi, Delhi, *India*.

Received 22nd February 2004. Accepted for publication in final form 23rd May 2004.

Address correspondence and reprint request to: Prof. Ashok Shah, Department of Respiratory Medicine, Vallabhbhai Patel Chest Institute, University of Delhi, PO Box 2101, Delhi 110 007, *India*. Tel. +91 (11) 2543 3783. Fax. +91 (11) 2766 7420. E-mail: ashokshah99@yahoo.com

Figure 1 - Computed tomogram of thorax showing miliary opacities in both lung fields along with consolidation of the posterior segment of upper lobe and superior segment of lower lobe of right lung.

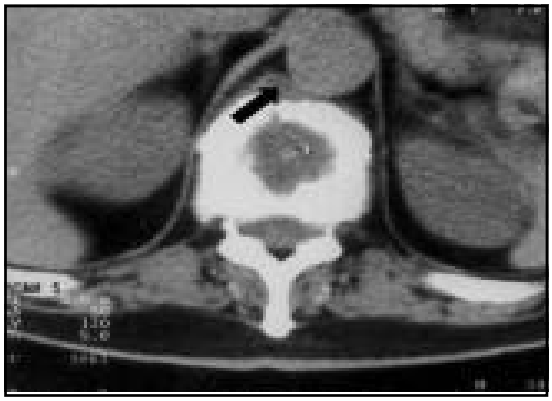

Figure 2 - Computed tomogram of dorsolumbar spine across dorsal 12 vertebra showing osteolytic lesion in the vertebral body along with mild soft tissue thickening in pre- and paravertebral areas.

miliary parenchymal opacities in both lung fields and demonstrated consolidation of the posterior segment of upper lobe and superior segment of lower lobe of right lung (**Figure 1**). The laboratory evaluation showed a hemoglobin of 12.4 gm% and a total leucocyte count of 6400/mm^3 with 72% polymorphonuclear cells, 20% lymphocytes, 5% monocytes and 3% eosinophils. Other biochemical parameters and urine examination were within normal limits. The Mantoux test with 5 TU was negative. An ophthalmoscopic examination detected the presence of a patch of healed choroiditis in the right eye and choroidal tubercles in the left eye. Several sputum stains for acid-fast bacilli were negative. On fibre optic bronchoscopy, granulomatous lesions were visualized in both bronchial trees. Direct smear examinations of bronchial aspirate and post bronchoscopy sputum were positive for acid fast bacilli. Culture of bronchial aspirate and post-bronchoscopy sputum yielded *Mycobacterium tuberculosis*, which 12-weeks later was reported to be resistant to rifampicin, isoniazid, streptomycin, kanamycin and ethionamide but sensitive to fluoroquinolones, ethambutol and para-amino salicylic acid (PAS). Sensitivity to pyrazinamide was not carried out. Radiograph of the dorsolumbar spine showed partial loss of volume of D12 vertebra with intervertebral disc lesion at the level of D11-D12 that was confirmed on CT (**Figure 2**).

A diagnosis of MDR miliary TB with associated osteomyelitis of the D12 vertebra, which was thought to be Pott's disease, was made. The patient was initiated on intramuscular streptomycin 0.75gm once daily along with oral daily doses of ethionamide (750mg), cycloserine (750mg), clofazimine (200mg), ofloxacin (400mg) and a combination of isoniazid and PAS (150mg and 5gms twice daily), with which he improved steadily. Chest radiograph, carried out 10-weeks later, revealed marked radiological clearing. As the patient had a remarkable improvement, the treatment regimen was not altered in spite of the sensitivity report received 12-weeks after the therapy was modified. The patient was subsequently lost to follow up but we learnt that he had recovered.

Discussion. Although miliary TB was recognized earlier in our patient, the symptoms of Pott's disease preceded respiratory complaints. A literature search revealed 2 reports documenting the coexistence of these 2 forms of TB.[3,4] A 37-year-old man with miliary TB, multiple cerebral tuberculomas and spinal TB in whom considerable diagnostic delay had occurred was reported from Japan.[3] The authors did not clarify, which condition occurred earlier, nor were there any mention of MDR TB. Another recent report[4] documented the co-occurrence of miliary TB and Pott's disease in a 22-year-old man with a history of alcohol and drug abuse, though the clinical outcome was not detailed. However, disseminated infection due to *Mycobacterium scrofulaceum* in an immunocompetent host has been described.[5] The clinical manifestations included miliary lung lesions, mediastinal lymphadenitis, granulomatous hepatitis, osteomyelitis, subcutaneous abscesses and probable renal involvement. The bony involvement was limited to the medial portion of the right second rib. In this patient too, attention was first drawn by the predominant chest symptoms.

The isolates of *Mycobacterium tuberculosis* obtained from bronchial aspirate and post-bronchoscopy sputum of our patient were resistant to rifampicin, isoniazid, streptomycin, kanamycin and ethionamide. Although

hematogenous dissemination of MDR tubercle bacilli have been reported in patients with AIDS,[1,2] such a report in an immunocompetent HIV-negative patient is yet to be documented. Our patient had no history of contact with TB, had no factors predisposing to infection and had no evidence of an immunocompromised state such as HIV infection, diabetes, malignancy, steroid therapy or chronic renal failure. Sime et al[6] reviewed 29 patients with miliary TB from 1984-1992 in Edinburgh and compared the findings with 40 patients previously reported from 1954-1967. Multidrug resistant miliary TB was not recorded in any of these 69 patients. Similarly, a review of 100 non-HIV adult patients with miliary TB from India[7] found no mention of multi-drug resistance although 12 patients succumbed to the severity of their illness. This report, according to the authors, was the first large series in the previous 10-years from India. In 2 recent clinical reviews of miliary TB, one in 74 adults from Japan[8] and the other in 23 children from Turkey,[9] the authors reported that antituberculous therapy was successful in most patients. Mortality occurred in 7 and 2 patients but the outcome in general was good. Neither of these series recorded the occurrence of multidrug resistance.

The term, 'third epidemic' was coined to highlight the fact that MDR TB, the nightmare of all pulmonologists, had assumed panepidemic proportions.[10] Our case brings forth a hitherto unknown danger that multi-drug resistance can occur in an immunocompetent patient with miliary TB.

Acknowledgment. The authors are thankful to Dr. N. K. Jain, Consultant Mycobacteriologist, for conducting the mycobacteriological studies.

References

1. Hill AR, Premkumar S, Brustein S, Vaidya K, Powell S, Li PW, et al. Disseminated tuberculosis in the acquired immunodeficiency syndrome era. ***Am Rev Respir Dis*** 1991; 144: 1164-1170.
2. Daikos GL, Uttamchandani RB, Tuda C, Fischl MA, Miller N, Cleary T, et al. Disseminated miliary tuberculosis of the skin in patients with AIDS: Report of four cases. ***Clin Infect Dis*** 1998; 27: 205-208.
3. Sakao S, Sasaki Y, Yamagishi F, Yagi T, Mizutani F, Tada Y. A case of miliary tuberculosis with multiple cerebral tuberculoma and spinal tuberculosis owing to total delay. ***Kekkaku*** 1998; 73: 519-523.
4. Langhorst M, Reeves A, Tarver R, Miller D. Miliary tuberculosis and Pott's disease. ***Semin Respir Infect*** 2001; 16: 149-151.
5. Hsueh PR, Hsiue TR, Jarn JJ, Ho SW, Hsieh WC. Disseminated infection due to *Mycobacterium scrofulaceum* in an immunocompetent host. ***Clin Infect Dis*** 1996; 22: 159-161.
6. Sime PJ, Chilvers ER, Leitch AG. Miliary tuberculosis in Edinburgh. A comparison between 1984-1992 and 1954-1967. ***Respir Med*** 1994; 88: 609-611.
7. Sharma SK, Mohan A, Pande JN, Prasad KL, Gupta AK, Khilnani GC. Clinical profile, laboratory characteristics and outcome in miliary tuberculosis. ***Q J Med*** 1995; 88: 29-37.
8. Nagai H, Kurashima A, Akagawa S, Tamura A, Nagayama N, Kawabe Y, et al. Clinical review of 74 cases with miliary tuberculosis. ***Kekkaku*** 1998; 73: 611-617.
9. Gurkan F, Bosnak M, Dikici B, Bosnak V, Yaramis A, Tas MA, et al. Miliary tuberculosis in children: a clinical review. ***Scand J Infect Dis*** 1998; 30: 359-362.
10. Malin AS, McAdam KPWJ. Escalating threat from tuberculosis: The third epidemic. ***Thorax*** 1995; 50 (Suppl 1): S37-S42.