Case Report

Abdominal cocoon

An unusual cause of intestinal obstruction

Abdulla A. Al-Abassi, *FRCS (Ed),* ***Mohammed Emad,*** *MD, PhD.*

ABSTRACT

We report a case of abdominal cocoon in a young male patient, presenting with acute intestinal obstruction and abdominal mass. This is a rare acquired condition of the peritoneum in which the small bowel is encased either partially or totally by a dense fibrous membrane. Operative findings, perioperative imaging and treatment guidelines are discussed. A better awareness of this condition may facilitate preoperative diagnosis; prevent inadvertent bowel damage at laparoscopy and unnecessary bowel resection at laparotomy.

Saudi Med J 2004; Vol. 25 (10): 1482-1485

Abdominal cocoon is a rare disease of the peritoneum characterized by total or partial encasement of the small bowel by a dense fibrous membrane.[1-3] It primarily affects young females and shows tropical and subtropical distribution.[1] Abdominal cocoon usually presents as recurrent acute or subacute intestinal obstruction with or without a mass.[1,4] Unawareness of this condition resulted in unnecessary bowel resection[1] and in the era of laparoscopic surgery, inadvertent damage to the small bowel at insertion of the trocar and canula.[5] We report a case of abdominal cocoon in a young male patient, presenting with acute intestinal obstruction and abdominal mass. To the best of our knowledge, <50 cases have been reported in the English literature since it was first described in 1978.[2,4]

Case Report. A 24-year-old Egyptian male, admitted to our hospital with central abdominal pain of one day duration. The pain was colicky in nature, associated with abdominal distension and vomiting several times. He admitted having mild attacks of similar nature in the previous 2-years, but had no specific treatment due to its spontaneous symptomatic relief. He had appendectomy through a right McBurney incision 2-years before and the nature of which was not known. No history of other abdominal surgery or previous infection and he was receiving no medication.

On examination, he looked in pain, pulse was 86 per minute, blood pressure was 120/70 mm Hg and temperature was 37°C. The abdomen was distended and tender. Maximum tenderness was felt over a central abdominal mass, lying more towards the right iliac fossa. The mass itself was firm, measuring 15 x 15 cm. Bowel sounds were exaggerated. Laboratory workup revealed a hemoglobin of 13.7g/dl, a total leukocytic count of 4.600/mm^3, platelets count of 357/mm^3 and serum amylase of 132 U/L. Alkaline phosphatase showed an interesting rise and decline. It was 539 IU/L preoperatively, increased to 1098 U/L on the first postoperative day, declined to 785U/L on the

From the Department of General Surgery (Al-Abassi) and the Department of Radiology (Emad), Saqr Hospital, Ras Alkhaimah, *United Arab Emirates*.

Received 15th March 2004. Accepted for publication in final form 24th May 2004.

Address correspondence and reprint request to: Dr Abdulla Al-Abassi, Consultant General Surgeon, Department of General Surgery, PO Box 3405, Ras Alkhaimah, *United Arab Emirates.* Tel. +971 (7) 2223666. Fax. +971 (7) 2222760. E-mail: alabassi@hotmail.com

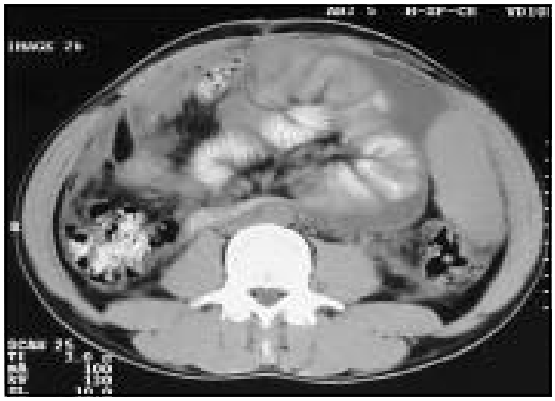

Figure 1 - Axial computerized tomography section at the mid abdomen revealed loculated fluid collection, containing partially the jejunal loops and partially going outside that sheath, having prominent mucosal lining with thickened mural walls.

Figure 2 - Ultrasound of the abdomen showing the well defined multi-loculated fluid collection (with inside thin septae) seen just posterior to the anterior abdominal wall, limited posteriorly by a well defined sheath. The underlying small bowel loops are thickened, entrapped within a thick peritoneal layer and coiled in a serpentine fashion.

second postoperative day, then to near normal on successive days. Abdominal plain x-ray showed remarkable appearance of the jejunal loops. However, there was no definite signs of intestinal obstruction. Abdominal ultrasound revealed distended small bowel loops with fluid collection in the pelvis, extending to the right iliac fossa and umbilical area just under the posterior rectus sheath. Under provisional diagnosis of acute intestinal obstruction with possibility of strangulated bowel, an exploration laparotomy was performed through a midline incision. There was approximately 200 ml of straw-colored, jelly like fluid. The small bowel was found encased and markedly shortened within a thick whitish membrane which had free edges near the mesentery. The cecum, large bowel, liver, gallbladder, spleen, greater omentum and pelvic organs were hidden behind a similar whitish semitransparent sheath. Fibrous adhesions were found near the ileo-cecal valve, at the site of previous appendectomy. The membranous sheath encasing the small bowel was found firmly adherent to the serosa. Trial of separation of the 2-layers denuded the small bowel of its serosa. Therefore, it was thought more appropriate to release this membranous sheath by multiple vertical incisions at its free mesenteric border, thus providing partial relief of the underlying obstructed small bowel. The adhesions near the cecum were released by sharp dissection. Distal patency was confirmed by a small (1cm) enterotomy in the terminal ileum through which infusion of normal saline via a Foley's catheter was found to pass freely to the cecum. Postoperatively, he had an abdominal distension and difficulty in breathing secondary to diaphragmatic compression by the distended small bowel loops. Peritoneal fluid taken for aerobic and anaerobic cultures did not grow any bacteria. Barium meal and follow through showed free flow of barium throughout the whole course of the gastrointestinal tract. Clusters of small bowel loops were compressed within a thickened sheath of peritoneum. Computed tomography of the abdomen revealed a loculated fluid limited posteriorly by a well defined sheath. Clusters of small bowel loops showed prominent mucosal lining and thickened mural wall (**Figured 1**). His conditions improved gradually on conservative management and he was discharged home on the eighth postoperative day. Two months later he had a progressive abdominal distension, and occasional vomiting after food intake. Follow up abdominal ultrasonography revealed multi-loculated fluid collection in the peritoneal cavity, most of which was in the right upper quadrant. The underlying small bowel loops were edematous, entrapped within a thick peritoneal layer and coiled in a serpentine fashion (**Figure 2**). Trial of percutaneous drainage under ultrasound guidance failed due to the jelly-like consistency and the multiloculate nature of the fluid. On his 3-months follow up, he was getting occasional abdominal colic and distension after food intake. He was advised to have frequent small meals and to avoid further surgery if possible.

Discussion. Abdominal cocoon has been given different names in the medical literature.[3] It was first described in 1907[3] as "peritonitis fibrosa incapsulata". Foo[1,3] were the first to name and describe 'cocoon abdomen' in adolescent girls. Terms such as sclerosing peritonitis, encapsulating peritonitis and sclerosing encapsulating peritonitis have been used to describe this condition.[2] In a relatively recent review, a total of 35 cases have been reported since abdominal cocoon was first

described in 1978.[2] Twenty-five of them were females and 10 were males. Four of the female patients were children. Most of the patients were from tropical and subtropical regions. Abdominal cocoon is an acquired condition and may be classified into "primary" or "idiopathic" and "secondary" forms.[3] Primary abdominal cocoon mainly occurs in young women from tropical and subtropical zones and is thought to be due to retrograde menstruation or infection via the fallopian tubes.[1-3] Secondary abdominal cocoon has been reported in association with many causes including long term use of beta-adrenergic blocking agents, chronic ambulatory peritoneal dialysis, ventriculoperitoneal and peritoneovenous shunting, liver transplantation, sarcoidosis, familial Mediterranean fever, carcinoid syndrome, exposure to asbestosis and autoimmune disease.[2,3,6,7] The underlying pathogenesis of secondary abdominal cocoon remains obscure. It has been attributed to peritoneal infection, intra-peritoneal bleeding and auto-immune reaction.[3,4,8] Intraperitoneal use of povidone iodine for peritoneal lavage,[9] intraperitoneal administration of antibiotics and antiseptics in peritoneal dialysis[10,11] and the intraoperative use of rubber gloves coated with talcum powder[12] have been suggested as causes of cocoon abdomen after surgery. Although we do not have access to the operative details of previous appendectomy in our patient, generalized bacterial peritonitis, mild chemical peritonitis secondary to intraoperative administration of some antiseptic or antibiotic solution or the use of povidone iodine for peritoneal lavage are possible causes of abdominal cocoon in our patient.

Abdominal cocoon should not be confused with congenital malformations of the peritoneum. Peritoneal encapsulation is characterized by an accessory peritoneal sac derived from the yolk sac as it is withdrawn into the abdominal cavity with the small bowel during the 12-weeks gestation.[13] It may present in infancy or childhood as an acute intestinal obstruction.[3] The accessory peritoneal sac, in contrary to abdominal cocoon, is thin and envelops the entire small bowel without being adherent to its serosa.[2] Left mesocolic or para-duodenal hernia is another congenital malformation where most of the small bowel enters into peritoneal sac through an opening inferior to the fourth part of the duodenum. This condition is thought to happen when the midgut returns into the abdomen and rotates to its normal position.[13] Although it can be an incidental finding at laparotomy or at autopsy, some cases are symptomatic and may present with colicky pain and left sided abdominal mass.

Patients with abdomen cocoon usually present with recurrent attacks of intestinal obstruction.[1,3,4] Biochemical investigations are usually normal. Increased serum alkaline phosphatase of intestinal origin is seen in states of chronic inflammatory bowel disease,[14] intestinal strangulation or obstruction.[15] This explains the perioperative rise in serum alkaline phosphatase in our patient. Radiological findings are non-specific but may give clues to the diagnosis of abdominal cocoon. Barium small bowel series occasionally brings on the characteristic 'cauliflower sign'[16] and serpentine configuration of the small bowel loops within the cocoon.[1] Ultrasound of the abdomen may show hyperechogenic mass with entrapped small bowel loops within a thickened peritoneal layer, and may reveal a loculated ascitis.[3,8] Computed tomography may be more diagnostic demonstrating a smooth peritoneal thickening,[3] circumferential bowel wall thickening and marked ascitis.[8]

Definitive diagnosis of abdominal cocoon is made at laparotomy. Characteristically, the small bowel is found totally or partially compressed and coiled up in a concertina-like fashion and encased in a dense whitish membrane.[1,4] The condition primarily involves the small bowel. In occasional cases, the membrane may extend to the surrounding organs such as the large bowel, the liver and the stomach.[1,3,4] In our case, the peritoneal sac covered all visible intra-abdominal organs including the anterior aspect of small and large bowel, liver, gallbladder, spleen and urinary bladder. Approach to these organs cannot be achieved without dissecting the enveloping membrane. Surgery is the definitive treatment of this condition. Partial release of the overlying membrane, as in our case, should improve the underlying obstruction. Resection of the membrane and lysis of adhesions should be attempted when feasible.[1,3,17] Bowel resection is indicated if a segment is found nonviable.[3] Surgical treatment is not recommended in asymptomatic patients, cirrhotic patients with ascitis and in patients with subacute intestinal obstruction.[17]

In conclusion, preoperative recognition of abdominal cocoon should result in the correct management of this condition; prevent inadvertent damage to the small bowel at laparoscopy and unnecessary bowel resection at laparotomy.

References

1. Yoon YW, Chung JP, Park HJ, Cho HG, Chon CY, Park IS et al. A case of abdominal cocoon. ***J Korean Med Sci*** 1995; 10: 220-225.
2. Hamaloglu E, Altun H, Ozdemir A, Ozenc A. The abdominal cocoon: a case report. ***Dig Surg*** 2002; 19: 422-424.
3. Abul S, Al-Oazweni H, Zalat S, Al-Sumait B, Asfar S. Cocoon abdomen in a liver transplant patient. ***J R Coll Surg Edinb*** 2002; 47: 579-581.
4. Kumar M, Deb M, Parshad R. Abdominal cocoon: report of a case. ***Surg Today*** 2000; 30: 950-953.
5. Dasari P, Raghavan S, Srinivasan K. Abdominal Cocoon Syndrome: A Case Report. ***J Obstet Gynecol India*** 2000; 50: 122.

6. Eltringham WK, Espiner HJ, Windsor CW, Griffiths DA, Davies JD, Baddeley H et al. Sclerosing peritonitis due to practolol: a report on 9 cases and their surgical management. ***Br J Surg*** 1977; 64: 229-235.
7. Pollock CA. Diagnosis and management of encapsulating peritoneal sclerosis. ***Perit Dial Int*** 2001; 21 Suppl 3: S61-S66.
8. Kim MY, Koo JH, Yeon JW, Suh CH, Kim KK. Ileal obstruction caused by idiopathic sclerosing encapsulating peritonitis. ***Abdom Imaging*** 1999; 24: 82-84.
9. Keating JP, Neill M, Hill GL. Sclerosing encapsulating peritonitis after intraperitoneal use of povidone iodine. ***Aust N Z J Surg***1997; 67: 742-744.
10. Freiman JP, Graham DJ, Reed TG, McGoodwin EB. Chemical peritonitis following the intraperitoneal administration of vancomycin. ***Perit Dial Int*** 1992; 12: 57-60.
11. Mackow RC, Argy WP, Winchester JF, Rakowski TA, Fields PA, Rotellar C et al. Sclerosing encapsulating peritonitis in rats induced by long-term intraperitoneal administration of antiseptics. ***J Lab Clin Med*** 1988; 112: 363-371.
12. Wirnsberger GH, Ganser K, Domej W, Sauseng G, Moore D, Moczygemba M et al. Sclerosing encapsulating peritonitis: differential diagnosis to peritoneal encapsulation and abdominal cocoon. A case report. ***Z Gastroenterol*** 1992; 30: 534-537.
13. Kyaw K. Left mesocolic hernia or peritoneal encapsulation? A case report. ***Singapore Med J*** 1998; 39: 30-31.
14. Ockner R. Alkaline phosphatase. In: Liver, Gallbladder and Biliary Disease, Cecil Textbook of Medicine. 20th ed. Philadelphia (PA): W. B. Saunders; 1996.
15. Kazmierczak SC, Lott JA, Caldwell JH. Acute intestinal infarction or obstruction: search for better laboratory tests in an animal model. ***Clin Chem*** 1988; 34: 281-288.
16. Navani S, Shah P, Pandya S, Doctor N. Abdominal cocoon--the cauliflower sign on barium small bowel series. ***Indian J Gastroenterol*** 1995; 14: 19.
17. Celicout B, Levard H, Hay J, Msika S, Fingerhut A, Pelissier E. Sclerosing encapsulating peritonitis: early and late results of surgical management in 32 cases. ***French Associations for Surgical Research Dig Surg*** 1998; 15: 697-702.