

## **The effect of melatonin on changes in brown and white adipose tissue ratios induced by exercise. The significance of age in this effect**

*Hilmi Ozden, MD, PhD, Davut Ozbag, PhD, Fahrettin Akyuz, PhD, Emine Sunal, PhD, Firdevs Gurer, PhD, Mine Inal, PhD.*

Of the cell rich connective tissue types, adipose tissue formations are named unilocular or white fat cells when seen in large and singular lipid drop formation states and multilocular or brown fat cells when there is a great variety and excess of lipid drop formations with a large amount of contained mitochondria within. Brown fat tissue in particular, and that given the name brown adipose tissue, does not only provide support and protective functions, but also play a higher role in metabolic tissue activity. While brown adipose tissue is more widely seen in newborns, transference to white adipose tissue occurs with the advance of age. In states such as long-term starvation, cold, aging and chronic illnesses, hypertrophy occurs.<sup>1</sup> However, researchers reported that in mice, running for a long period increases the amount of brown fat tissue. This effect when exercise took place at 24°C and 4°C, with shaking and thermogenesis especially agitated in humans; and an adaptation of brown fat tissue in cold conditions was observed, especially occurring within the thyroid along with the endocrine system.<sup>2</sup>

Exercise carried out during the cold winter season when there is lack of sunlight, coupled with an increase in people's appetite results in an increase in body weight, this can be put down to the thermoregulation function of the brown fatty tissue or the role of the related metabolic events. Our research into the effect of the amount and length of sunlight on the oscillation of the endogen melatonin, resulted in a relationship between the amount of brown adipose tissue and cellularity. The results of this research will also help other studies, especially obesity. However, the results of this relationship were inconclusive when we looked into the active function of tissue thermoregulation and its connection with sunlight in hibernating organisms. Thus, the important role of pineal gland in neuroendocrine behavior and its partnership of brown fatty tissue in hibernating organisms, mammals and humans is not clearly understood and still requires more information.<sup>3</sup>

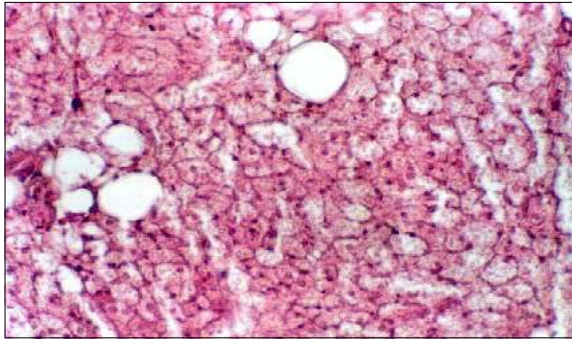
Probable relationships may support many ethyo-physiology diagnoses and treatment protocols, above all that of obesity. However, studies have been conducted jointly into both the relationship between melatonin-brown adipose tissue, cold and diet, and the connection of brown adipose tissue to cold, and exercise. The effects of diet and exercise have also been investigated separately. Up to now there has only been one

previous study into the relationship between melatonin brown adipose tissue and exercise.<sup>4</sup> In the study, experiments were carried out on hamsters exercising in a short photoperiod. Present day information shows that after a period of high-energy use there is an increase in appetite, which in turn results in an increase in body weight and lipid concentration, while the compensation provided by melatonin in complications such as these needs further investigation. For example, in a study on the connection between the body's proportions of brown and white adipose tissue and the consumption of sucrose and caffeine in coca cola, it was found that coca cola provided resistance against cold, and this was due to the conversion of sucrose spurring the production of brown adipose tissue cellularity, and in addition to this, caffeine inhibited the proliferation of white adipose tissue, preventing obesity.<sup>5</sup>

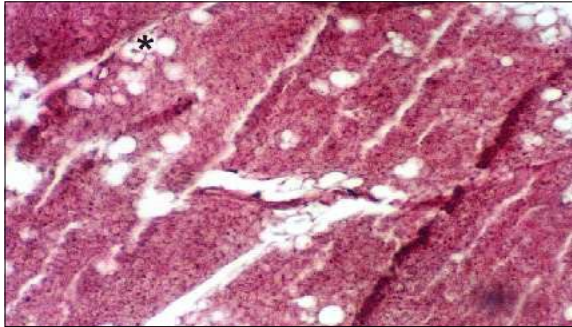
In order to eliminate a possible age connection to differing amounts of brown adipose tissue found in the body, we studied the effects of exercise on 3 age groups of Sprague Dawley rats: Young (n=16), middle-aged (n=16) and elderly (n=16). Each group ran 40m/min for 15 minutes a day over a 5-day period with the experimental group of each receiving a 10mg/kg intraperitoneal injection one hour before exercise. Samples were taken from the area around the kidney to conduct tests on the effects of exercise on the variation and proportion of brown or white adipose tissue found and how an injection of melatonin changed this effect. Histological comparisons for each age group were then carried out.

We observed the reasons why exercise completely effected the formation of brown adipose tissue in the old (**Figure 1**) and middle-aged groups (**Figure 2**), while it affected the transitive formation of the young group (**Figure 4**). In the experiment group of middle-aged subjects, those administered with melatonin injection, were found that the adipose tissue was entirely white (**Figure 3**), while in the elderly experimental group, there was evidence of minimal transitive brown adipose tissue, a larger amount of white adipose tissue. In almost the entire experimental group of young subjects, a larger amount of white adipose tissue was seen than in the control group, and this state of having white adipose tissue does not alter.

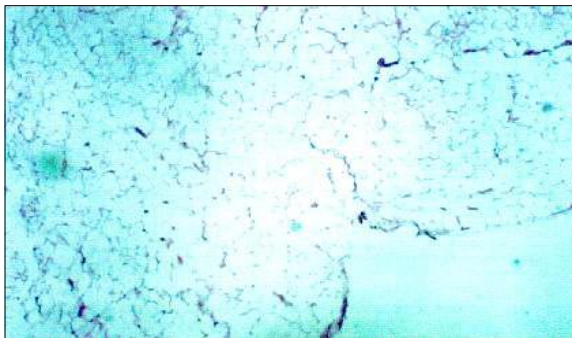
To define the role of the thermoregulation function of brown adipose tissue in hibernatic organisms, or the role of the related metabolic event in the increase in body weight seen following exercise during the cold winter months when there is lack of sunlight. Probable links found between these factors may support many ethyo-physio-pathological diagnosis and treatment protocols. According to our findings, complications such as an increase in body weight due to the augmentation of brown adipose tissue are dependent on factors such as short daylight periods, cold and



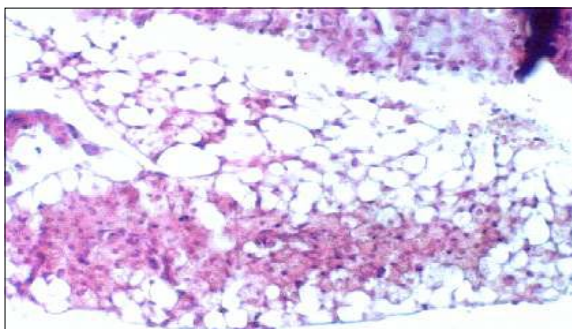
**Figure 1** - The reason behind the presence of entirely brown adipose tissue in the exercising elderly control group. Hemoxilyn and Eosin x 66.



**Figure 2** - The presence of minimal white adipose tissue cells in brown adipose tissue (\*) for the middle-aged control group after exercise. Hemoxilyn and Eosin x 33.



**Figure 3** - White adipose tissue remaining after melatonin injection taken from the kidney area in the middle-aged experimental group. Hemoxilyn and Eosin x 13,2.



**Figure 4** - White adipose tissue in the young group is observed with exercise, but this returns to brown adipose tissue. Hemoxilyn and Eosin x 66.

exercise. We found that the group of young subjects best tolerated this change due to their generally possessing more brown adipose tissue than the other groups. This may be put down to oscillation of the endogen melatonin. However, nearly the entire middle-aged group in particular, had almost white tissue, and the least oscillation of the endogen melatonin. We believe that treatment with Exogen melatonin inhibited the increase of brown adipose tissue and therefore, reduced the complication of increased body weight.<sup>3,4</sup>

In conclusion, we suggest that in the planning of diet and exercise programs designed for health and weight-loss purposes, the most important consideration should be for which photoperiod these activities will take place in. To this aim we suggest that when considering the different age groups, attention must be paid to the suggestion that the period of sunlight combined with differences in the amount of oscillation of endogen melatonin can most affect the middle-aged group. Disorders in circadian rhythm are caused by inter-continental journeys made in the winter months, obligatory professional sportsmen's training and exercise programs where there is not enough protection from the cold<sup>2</sup> and a lack of daylight. In order to combat these problems, there is a necessity for planning the use of exogen melatonin when designing sport and diet plans and we believe that there is a need for more studies into sport and diet programs supported by exogen melatonin.

Received 15th March 2004. Accepted for publication in final form 29th May 2004.

From the Departments of Anatomy (Ozden), and Biochemistry (Akyuz, Sunal, Inal), Histology and Embryology (Gurer), Medical School of Osmangazi University, Eskisehir, and the Department of Anatomy (Ozbag), Faculty of Veterinary Medicine, Dicle University, D Yarbakir, Turkey. Address correspondence and reprint requests to Dr. Hilmi Ozden, Department of Anatomy, Medical School of Osmangazi University, Eskisehir, Turkey. Tel. +90 (222) 2392979/2394434. Fax. +90 (222) 2290170. E-mail: hozden@ogu.edu.tr, hilmiuzden@hotmail.com

## References

1. Tang QQ, Otto TC, Lane MD. Mitotic clonal expansion: A synchronous process required for adipogenesis. *Proc Natl Acad Sci* 2003; 100: 44-49.
2. Shephard RJ. Adaptation to exercise in the cold. *Sports Med* 1985; 2: 59-71.
3. Wade GN, Bartness TJ. Seasonal obesity in Syrian hamsters: effects of age, diet, photoperiod, and melatonin. *Am J Physiol* 1984; 247: 328-334.
4. Heldmaier G, Steinlechner S, Rafael J, Vasia P. Photoperiodic control and effects of melatonin on nonshivering thermogenesis and brown adipose tissue. *Science* 1981; 212: 917-919.
5. Bukowiecki LJ, Lupien J, Folllea N, Jahjah L. Effects of sucrose, caffeine and cola beverages on obesity, cold resistance, and adipose tissue cellularity. *Am J Physiol* 1983; 244: 500-507.