

# Male breast disorders in Jordan

## Disease patterns and management problems

Rami J. Yaghan, MD, FRCS, Kamal E. Bani-Hani, MD, FRCS.

---

### ABSTRACT

**Objective:** To highlight the features and management problems of male breast disorders in an eastern country such as Jordan.

**Methods:** Data regarding 33 male patients who underwent surgery for breast diseases in the Department of Surgery at Jordan University of Science and Technology, Irbid, Jordan, between the year 1996 and 2002 were analyzed.

**Results:** Gynecomastia (45.5%), ductal carcinoma (18.2%), and lipoma (12.1%) were the most frequent lesions. Endocrine testing when the clinical diagnosis was physiologic gynecomastia was not yielding. Many features of male breast carcinoma in Jordan (symptomatology, male to female ratio, high education rate, age, diagnostic yield of fine-needle aspiration, histological type, and estrogen receptor status) did not depart from the experience of others. Delayed presentation is evident from the fact that 57% of tumors were stage III. Loco-regional control was achieved by modified radical mastectomy. Tamoxifen was used in 5

patients, and chemotherapy in 4 patients. The patient with stage I is still disease free 6 years after the diagnosis. The 5-year survival rate for stages II and III was zero. Rare lesions (cystic hygroma, cystic mastopathy, fibroadenoma, duct papilloma, tuberculosis, periductal mastitis, and the previously unreported primary primitive neuroectodermal tumor of the breast) accounted for the rest of the group. The patient with primary primitive neuroectodermal tumor of right breast was treated by mastectomy and adjuvant chemotherapy. He remains disease free 31 months after the diagnosis.

**Conclusion:** Unawareness and the fact that male breast enlargement is considered a social stigmata are responsible for the delayed presentation. The value of fine needle aspiration cytology and mammography is not widely appreciated. The wide spectrum of potential pathologies calls for referring all patients to specialized breast units.

Saudi Med J 2004; Vol. 25 (12): 1877-1883

---

**M**ale breast carcinoma (MBC) is an old recognized entity. The first clinical description dates back to the 14th century, while the earliest reference to breast cancer appears to be to a male patient from Egypt about 3000-2500-years B.C.<sup>1</sup> Despite this, the pathophysiology and management of MBC and other male breast disorders (MBD), are still controversial. In view of the rarity of MBC, the vast majority of available data comes from

retrospective reports or from comparison to postmenopausal female breast carcinoma. This prompted us to report our experience regarding MBD in Northern Jordan to give an example of the pathological, clinical, and epidemiological features of MBD in the Middle East where such data is lacking. Comparison to data available from other parts of the world was performed whenever possible. At the same time, we will highlight the

---

From the Department of Surgery, Jordan University of Science and Technology, Irbid, Jordan.

Received 3rd May 2004. Accepted for publication in final form 12th June 2004.

Address correspondence and reprint request to: Dr. Rami J. Yaghan, Professor of Surgery, Faculty of Medicine, Jordan University of Science and Technology, PO Box 3030, Irbid 22110, Jordan. Tel. +962 (2) 7060616. Fax. +962 (2) 7060569. E-mail: lamees32@yahoo.com

problems facing the clinician when dealing with MBD. Our series includes the first case of a primary primitive neuroectodermal tumor (PNET) to be reported in the breast, in both sexes.

**Methods.** Data regarding male patients who underwent surgery for breast diseases at the Department of Surgery, Jordan University of Science and Technology, Irbid, Jordan, during the period 1996 through to 2002 were analyzed. Patients with breast disorders were treated in a breast unit. Pertinent data including age, mode of presentation, diagnostic methods, pathological diagnosis, treatment modalities, and treatment outcome were collected. Male patients who visited the unit for various breast problems that were clinically judged not to necessitate tissue diagnosis, were not included among our study group. Breast carcinoma was staged according to the primary tumor, regional nodes, metastasis (TNM) staging system.<sup>2</sup>

**Results.** During the study period, 33 patients were identified. The median age was 38.96-years (range: 15-80-years). **Table 1** lists the spectra, and percentages of different pathologies encountered, and the main presenting features. Gynecomastia was the most frequent lesion seen in 15 patients accounting for 45.5% of the cases. These patients were diagnosed to have physiologic gynecomastia on clinical bases. Five patients (33%) underwent further hormonal investigations (including human chorionic gonadotropin, estradiol, luteinizing

hormone [LH], and testosterone levels), and gonadal ultrasonography. In none of these cases did we find an underlying disorder. The lesion was localized to the left side in 7 (46.7%), right side in 4 (26.7%), and bilateral in 4 (26.7%) patients. These patients were treated by subcutaneous mastectomies for cosmetic reasons. The average size of resected lesions was 5.3 cm in maximum diameter (range: 2-9 cm). In one patient, the unusual lobule formation was observed. A hard breast lump was the presenting feature in the 6 patients with MBC. The mass was subareolar in 4 (66.6%) patients and was infiltrating the skin in one patient (**Figure 1**). The average duration of symptomatology was 12-months prior to presentation (range: 2-24 months). Left side affection was observed in 3 (50%), right side affection was observed in 2 (33.3%), and bilateral affection was observed in one patient (16.7%). None of the patients had history of orchitis, undescended testis, liver disease, or exogenous estrogen intake. Three of them were well-educated (University or School teachers). All of them got married before the age of 30-years and had multiple children with an average of 3.5. None of them gave a positive family history of breast cancer. Fine needle aspiration cytology (FNAC) was performed for 4 patients and was diagnostic in all of them. Mammography was performed for 3 patients and reported as malignant in 2 (**Figure 2**). Primary tumor, regional nodes, metastasis stage was I in 1 (14.3%), II in 1 (14.3%), III in 4 (57.1%), and X in 1 (14.3%) tumors. The number of tumors were 7 as the patient with a bilateral disease was considered to have 2 primaries. All patients underwent a modified

Table 1 - Characteristics of 33 male patients with breast diseases.

Diagnosis	N (%)	Median age (range) years	Symptomatology
Gynecomastia	15 (45.5)	21.2 (15-30)	Diffuse breast enlargement
Lipoma	4 (12.1)	50 (39-70)	Painless mass
Duct papilloma	1 (3)	46	Subareolar mass
Cystic mastopathy	1 (3)	37	Painful mass
Fibroadenoma	1 (3)	43	Painless mass
Cystic hygroma	1 (3)	30	Diffuse swelling
Tuberculosis	1 (3)	68	Hard mass
Periareolar inflammation	2 (6.1)	51.5 (38-65)	Nipple eczema in one patient, subareolar abscess in one patient
Ductal carcinoma	6 (18.2)	66.3 (60-80)	Painless mass with skin infiltration in one patient
Primitive neuroectodermal tumor	1 (3)	30	Painless mass

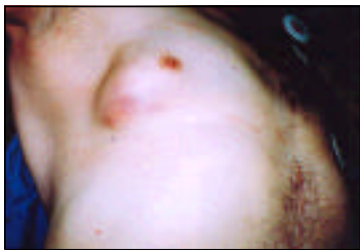

Figure 1 - This 64-year-old male patient presented with a hard mass in the lower outer quadrant of the right breast. Note skin discoloration and fixation to the underlying mass. The patient was aware of the presence of this malignant mass for the last 24 months.

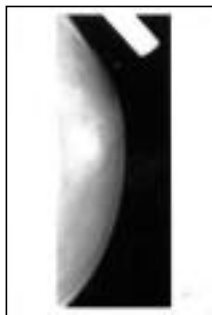

Figure 2 - Mammographic appearance of a malignant right breast mass in a 60-year-old man. Note the presence of a well-defined hyperdense malignant mass.

radical mastectomy with the exception of one patient who refused treatment after a positive FNAC. This patient was never convinced that he might get breast carcinoma. He never reported back to our unit, despite calling him several times. Infiltrating ductal carcinoma of no special type was present in all cases. Two patients had an associated gynecomastia in the surrounding normal breast tissue. None of the patients had an associated evidence of Paget's disease of the nipple. The estrogen receptor status was positive (immunohistochemical technique) in the 3 patients who had this test. Tamoxifen was used as an adjuvant treatment for 5 patients. Chemotherapy (cyclophosphamide, methotrexate, and 5-fluorouracil) was also given for patients with stage II and III disease. The patient with stage I is still disease free 6-years after the diagnosis. The 5-year survival for stages II and III was zero. Very rare lesions were encountered in 24.1% of the cases. Namely, these included: primary PNET, tuberculosis, duct papilloma, fibrocystic disease, fibroadenoma, cystic hygroma, and periductal mastitis (PM). One of our patients (30-years old) presented in September 2001 with a right-sided 2x1 cm breast lump, just below the nipple. Excisional biopsy revealed a PNET (**Figure 3a**). The tumor stained positive for CD99 antigen; a feature shared by all the morphologic spectra of these tumors (**Figure 3b**). Cytokeratin, synaptophysin, desmin, actin, leukocyte common antigen, CD20, CD45 Ro, and S 100 protein stains were negative. The lesion was totally intra-mammary in position and has no anatomical relation to the chest wall. Investigations including chest and abdominal computerized tomography scans, magnetic resonance imaging of

brain and spine, and a Tc-99 bone scan revealed no other tumors. Bilateral mammography and ultrasonography did not reveal any abnormality. So, the case was diagnosed as a primary tumor of the breast. Search over the Medline did not reveal any similar primary breast lesion, both in males and females. Mastectomy, with level II axillary clearance was performed. Biopsies from the underlying pectoralis major muscle were also taken at the end of the procedure. Histopathology showed no residual tumor mass in the breast; the deeper edge of the previous biopsy cavity was grossly one cm away from the pectoralis fascia. The muscle biopsies were tumor free. The removed lymph nodes showed reactive histiocytosis. Postoperatively, he received adjuvant chemotherapy (single agent doxorubicin 75mg/m<sup>2</sup>). The patient remains disease free till now (31 months). Four patients had lipomas. Apart from being part of the differential diagnosis of more serious lesions, they did constitute any special management problem. One of our patients was diagnosed to have a cystic hygroma after excising a mass from the upper outer quadrant of his right breast. Two years later he presented to our unit with a huge recurrence involving the right upper quadrant extending to the axilla. At operation, he was found to have multiloculated lesions filled with thick yellowish fluid and occasional pockets of altered blood. The lesion was adherent to surrounding structures and was removed with difficulty. Histology confirmed the same diagnosis (**Figure 4**). He remains symptom free for 40-months. Biopsy from the patient who presented with recurrent eczema of areola and nipple showed nonspecific dermatitis with no evidence of Paget's disease.





Figure 3 - Primitive neuroectodermal tumor of the right breast a) note the presence of monomorphic small around cells with scanty cytoplasm and conspicuous mitoses. The tumor cells are arranged in nests separated by fibrous septa (hematoxylin and eosin stain 100 x) b) the tumor stained positive for CD99 antigen, a feature shared by all the morphologic spectra of these tumors (200 x).

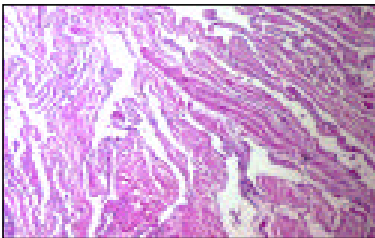


Figure 4 - Cystic hygroma of the right breast. Note the large, irregularly shaped vascular spaces mantled by bland, flattened endothelial cells in the background of a fibroblastic and collagenous stroma (hematoxylin and eosin stain 100 x).

**DISCUSSION.** Worldwide, MBD impose special problems both to the patient and the clinician. Men are aware that breast cancer is a nightmare for women, but only few appreciate that they, themselves, are potential victims. In an eastern community, a male patient with breast enlargement or mass will be very reluctant to seek medical advice. By some people, this might be looked upon as a social stigma and a sign of incomplete masculine. In view of the rarity of MBD, the problem of early referral is further complicated by the fact that surgeons working outside breast clinics would like to treat these rare conditions, in order to expand their career experience. The value of FNAC and mammography in the management of MBD is not widely appreciated. Recent literature indicates that FNAC in evaluating MBD should be an integral part of the initial assessment. Sensitivity (95.3-100%), specificity (100%), and diagnostic accuracy (98-100%) figures were reported in 2 large studies including 1121 male breast aspirates.<sup>3,4</sup> Mammography can accurately distinguish between malignant and benign MBD,<sup>5,6</sup> and in addition to ultrasonography, and FNAC will help in reducing the number of unnecessary surgeries. Unfortunately, only 12 patients among our study group (36.4%) had a preoperative FNAC. Gynecomastia was the most prevalent histological diagnosis. In consistency with some other reports,<sup>7,8</sup> our results indicated that routine endocrine testing in patients with the clinical diagnosis of idiopathic gynecomastia is not yielding. So, in a developing country with limited resources such as Jordan, clinicians should be very selective when ordering these tests. The absence of secondary type gynecomastia among our study group might be due to the fact that patients with underlying systemic disorders are usually seen in the medical clinics and usually do not require surgery. Worldwide, MBC accounts for less than 1% of female breast carcinoma and comprises 0.2% of malignancies in men.<sup>2,9</sup> Its prevalence increases with age with a mean of 60-65 years.<sup>1</sup> In consistency with this, in the year 2000, 4 cases of MBC were reported in Jordan. During the same year, 551 new breast cancers among females were diagnosed, giving a male to female ratio of 0.73%.<sup>10</sup> Breast cancer accounted for 0.2% of all cancers affecting Jordanian males in the year 2000.<sup>10</sup> Likewise, many other features of MBC among our study group (including age at presentation, tumor localization, the good diagnostic yield of FNAC and mammography, and the histological type) did not depart from the experience of others.<sup>1,2,4,9</sup> Feminization weather genetic or acquired (such as orchitis, undescended testes, testicular injury, Klinefelter's syndrome, excess estrogen exposure) was reported as a potential risk factor for MBC.<sup>9</sup>

Other factors include high education level, late marriage, and a history of breast cancer in a first-degree relative.<sup>1</sup> Inherited mutations of BRCA2, a major breast cancer susceptibility gene, has been linked to breast cancer in both men and women.<sup>19</sup> Apart from a good education level among our study group, none of the above mentioned risk factors were identified. The delay in presentation is evident from the fact that 57% of patients presented with stage III, and this explains, at least partially, the unsatisfactory treatment outcome. It is now appreciated that the early reports of a much worse survival for men than women might be largely a result of a more advanced stage at presentation in men, rather than a built-in biological aggressiveness of male tumors.<sup>2</sup> Despite the small number of patients in our series, very rare lesions were encountered in 24% of the cases namely: primary PNET, tuberculosis, duct papilloma, fibrocystic disease, fibroadenoma, cystic hygroma, and PM. This very wide pathologic spectrum of diseases emphasizes again the need to refer male patients with breast disorders to specialized breast units right from the beginning. There have been previous reports of metastatic PNET to breast,<sup>11,12</sup> but our case represents the first primary encountered in the breast in both sexes. PNET is an aggressive soft tissue neoplasm occurring predominantly in children and adolescents.<sup>13</sup> Adults are affected rarely.<sup>14</sup> They are characterized by a specific and reproducible reciprocal chromosome translocation, t(11;22)(q24;q12).<sup>15</sup> To a varying degree, all these tumors will show evidence of neuro-ectodermal differentiation.<sup>15</sup> Other names for PNET include: peripheral neuroepithelioma, Askin tumor of the chest wall, and extrasosseous Ewing's sarcoma.<sup>15</sup> Most cases are found in deep soft tissue, particularly on the trunk (with predilection for paravertebral region), lower limbs, and the retroperitoneal region.<sup>13,16</sup> The axial or deep location of the lesion usually precludes successful surgical excision with wide margins. So, the majority of these tumors are biopsied first and patients are given neoadjuvant chemotherapy (with variable response rate) aiming to make the lesions amenable for surgery.<sup>13,17</sup> Initial presentation (status of metastasis and size of primary tumor) seems to represent the only predictors of survival identified in adult patients with PNET.<sup>14,16</sup> Radiotherapy is helpful in achieving local control.<sup>13,17</sup> However, in our particular case adequate surgical excision was feasible by mastectomy. Due to the lack of previous similar cases and in view of the reported aggressiveness of the tumor,<sup>16,17</sup> we elected to use adjuvant chemotherapy in trying to get the best for our patient. The patient remains free of recurrence until now (31-months). Fibroadenomas are reported

rarely in male patients, probably due to the absence of lobules in the normal male breast.<sup>18</sup> Apart from initial clinical confusion with carcinoma, these lesions do not constitute any special management problem in males. It is worth noting that there has been a report of a fibroadenoma occurring in a male receiving exogenous estrogens,<sup>19</sup> and a juvenile fibroadenoma occurring in 19-year-old patient with complete androgen insensitivity syndrome (46 XY karyotype) after she underwent orchidectomy and received estrogen replacement therapy.<sup>20</sup> Our patient with fibroadenoma was a father of 3 children and did not have any exogenous steroid intake. One of our patients had an intraduct papilloma, and another patient had fibrocystic disease. Only few reports are available regarding these lesions.<sup>21,23</sup> The patient with fibrocystic disease had a normal testicular ultrasonography and a normal endocrinology profile. Tuberculosis of the breast is rare with prevalence among surgically removed breast lesions ranging from less than 0.025% in developed countries up to 3% in certain developing countries.<sup>24,25</sup> In a large study from India, including 160 patients with the cytological diagnosis of breast tuberculosis, Kakkar et al<sup>26</sup> reported a male to female ratio of 3.9%. This gives an example of the extreme rarity of this disease among males. As demonstrated by our patient, initial presentation might be a lump mimicking carcinoma.<sup>27,28</sup> Other presentations include ulceration, sinus formation, abscess formation, nipple retraction, and diffuse nodularity, with or without concomitant lymph node involvement.<sup>28</sup> Although most cases are reported from areas where *Mycobacterium tuberculosis* infection is known to exist,<sup>28,29</sup> tuberculosis is reemerging again in European industrialized countries and North America.<sup>30</sup> These infections are not only localized to the classic sites, but also are identified in unusual sites (such as the breast). Predisposition includes population-aging, immunosuppression, and emergence of resistant strains.<sup>31</sup> Diagnosis is facilitated by Ziehl-Neelson stain, purified protein derivative of tuberculin, and routine histology. However, confirming the diagnosis can sometimes be very difficult and the use of polymerase-chain-reaction (PCR) on paraffin embedded tissues to detect *Mycobacterium* DNA-sequences,<sup>27</sup> and even a trial of antitubercular treatment are occasionally indicated. Fine needle aspiration cytology will be helpful in ruling out malignancy, however, it sometimes confirms the diagnosis.<sup>27</sup> Mammography findings are nonspecific.<sup>31</sup> "At ultrasonography, the findings of abscesses and sinus tracts and of circumscribed hypoechoic masses with moving internal echoes and posterior enhancement may aid in differential diagnosis."<sup>31</sup> Excisional biopsy and antitubercular

treatment are usually curative. Immigration and the increasing prevalence of immunosuppressive disorders including acquired immune deficiency syndrome, add a global impact to this rare, yet serious, entity. Cystic hygromas usually occur at sites related to the embryological origins of the lymphatic system and usually present in infancy. The breast is a rare site of involvement, and the initial presentation might be in childhood or, as in our case, during adulthood.<sup>32,33</sup> Excision might be difficult, especially if the lesion extends to the axilla. The patient who presented with a subareolar abscess needed drainage 3 times. Biopsy revealed periductal inflammation without ductal dilatation. Work up for tuberculosis was negative. He was a heavy smoker. When he was advised to quit smoking and received metronidazole, his symptoms did not recur. It remains to be answered whether this represents the counterpart of female PM. In females, PM is now considered a separate entity from duct ectasia. Females with this disease might present with non-lactating periareolar inflammation, pus discharge, abscesses, mammary fistula or nipple inversion in the absence of pathological ductal dilatation.<sup>34</sup> Etiologically, the condition is related to smoking and anaerobic infection.<sup>35</sup> Duct ectasia on the other hand is considered an aging phenomenon with no relation to smoking or sepsis.<sup>36</sup>

In conclusion, unsatisfactory awareness of MBD, a low rate of use of FNAC and mammography, and the social restraints were the main problems facing the clinician in our community. Despite the small number of patients in this study, we encountered extremely rare conditions. This emphasizes the importance of referring male patients with breast disorders to specialized breast units right from the beginning.

**Acknowledgment.** The authors are very thankful to Dr. Ismael I. Matalqa for his assistance in preparing the photographs.

## References

- Donegan WL, Redlich PN. Breast cancer in men. *Surg Clin North Am* 1996; 76: 343-363.
- Bland KI, Vezzeridis MP, Copeland EM 3rd. Breast. In: Schwartz SL, Shires GT, Spencer FC, Daly JM, Fischer JE, Galloway AC, editors. Principles of surgery. New York (NY): McGraw-Hill; 1999. p. 533-599.
- Joshi A, Kapila K, Verma K. Fine needle aspiration cytology in the management of male breast masses. Nineteen years of experience. *Acta Cytol* 1999; 43: 334-338.
- Siddiqui MT, Zakowski MF, Ashfaq R, Ali SZ. Breast masses in males: multi-institutional experience on fine-needle aspiration. *Diagn Cytopathol* 2002; 26: 87-91.
- Evans GF, Anthony T, Turnage RH, Schumpert TD, Levy KR, Amir Khan RH et al. The diagnostic accuracy of mammography in evaluation of male breast disease. *Am J Surg* 2001; 181: 96-100.
- Gunhan-Bilgen I, Bozkaya H, Ustun EE, Memis A. Male breast disease: clinical, mammographic, and ultrasonographic features. *Eur J Radiol* 2002; 43: 246-255.
- Rohrich RJ, Ha RY, Kenkel JM, Adams WP Jr. Classification and management of gynecomastia: defining the role of ultrasound-assisted liposuction. *Plast Reconstr Surg* 2003; 111: 909-923, discussion 924-925.
- Bowers SP, Pearlman NW, McIntyre RC Jr, Finlays CA, Huered S. Cost-effective management of gynecomastia. *Am J Surg* 1998; 176: 638-641.
- English JC III, Middleton C, Patterson JW, Slingluff CL. Cancer of the male breast. *Int J Derm* 2000; 39: 881-886.
- Alkayed S, Hijawi B. National cancer registry: Incidence of cancer in Jordan 2000. Amman (JO): Ministry of Health; 2002.
- Silverman JF, Berns LA, Holbrook CT, Neill JS, Joshi VV. Fine needle aspiration cytology of primitive neuroectodermal tumors. A report of these cases. *Acta Cytol* 1992; 36: 541-550.
- Kwak JY, Kim EK, You JK, Oh KK, Hong SW, Kim SH. Metastasis of primitive neuroectodermal tumor to the breast. *J Clin Ultrasound* 2002; 30: 374-377.
- Zimmermann T, Blutters-Sawatzki R, Flechsenhar K, Padberg WM. Peripheral neuroectodermal tumor: challenge for multimodal treatment. *World J Surg* 2001; 25: 1367-1372.
- Martin RC II, Brennan MF. Adult soft tissue sarcoma or primitive neuroectodermal tumors: predictors of survival. *Arch Surg* 2003; 138: 281-285.
- Fletcher CDM. Peripheral neuroectodermal tumors. In: Fletcher CDM, editor. Diagnostic histopathology of tumors. China: Churchill Livingstone; 2001. p. 1679-1711.
- Verrill MW, Judson IR, Harmer CL, Fisher C, Thomas JM, Wiltshaw E. Ewing's sarcoma and primitive neuroectodermal tumor in adults: are they different from Ewing's sarcoma and primitive neuroectodermal tumor in children? *J Clin Oncol* 1997; 15: 2611-2621.
- Shamberger RC, LaQuaglia MP, Gebhardt MC, Neff JR, Tarbell NJ, Marcus KC et al. Ewing's sarcoma/primitive neuroectodermal tumors of the chest wall: impact of initial versus delayed resection on tumor margins, survival, and use of radiation therapy. *Ann Surg* 2003; 238: 563-567.
- Ansah-Boateng Y, Tavassoli FA. Fibroadenoma and cystosarcoma phyllodes of the male breast. *Mod Pathol* 1992; 5: 114-116.
- Kanhai RC, Hage JJ, Bloemena E, van Diest PJ, Karim RB. Mammary fibroadenoma in a male-to-female transsexual. *Histopathology* 1999; 35: 183-185.
- Davis SE, Wallace AM. A 19-year-old with complete androgen insensitivity syndrome and juvenile fibroadenoma of the breast. *Breast J* 2001; 7: 430-433.
- Durham JR, Fechner RE. The histologic spectrum of apocrine lesions of breast. *Am J Clin Path* 2000; 113 (5 Suppl 1): S3-S18.
- McClure J, Banerjee SS, Sandilands DG. Female type cystic hyperplasia in a male breast. *Postgrad Med J* 1985; 61: 441-443.
- Banik S, Hale R. Fibrocystic disease in the male breast. *Histopathology* 1988; 12: 214-216.
- Diallo R, Frelvet L, Poremba C, Cirkel U, Metzke D, Dockhorn-Dworniczak B. Lupus vulgaris as the etiology of tuberculous mastitis. *Pathology* 1997; 18: 67-70.
- Murphy DP, SenGupta SK, Muthiah AC. Benign breast diseases in Papua New Guinea. *P N G Med J* 1992; 35: 101-105.
- Kakkar S, Kapila K, Singh MK, Verma K. Tuberculosis of the breast. A cytomorphologic study. *Acta Cytol* 2000; 44: 292-296.

27. Bani-Hani KE, Yaghan RJ, Matalka II, Shatanawi NJ. Idiopathic granulomatous mastitis: Time to avoid unnecessary mastectomies. *Breast J* 2004; 10: 318-322.
28. Shinde SR, Chandawarkar RY, Deshmuch SP. Tuberculosis of the breast masquerading as carcinoma: a study of 100 patients. *World J Surg* 1995; 19: 379-381.
29. Jaideep C, Kumar M, Khanna AK. Male breast tuberculosis. *Postgrad Med J* 1997; 73: 428-429.
30. Cherubini M, Sustersich M, Baxa P. Mycobacterium infection directly observed in a surgical outpatient center. *Minerva Chir* 2003; 58: 77-82, 82-85.
31. Engin G, Acunas B, Acunas G, Tunaci M. Imaging of extrapulmonary tuberculosis. *Radiographics* 2000; 20: 471-488.
32. Kangesu T. Cystic hygroma of the breast in childhood. *Br J Clin Pract* 1990; 44: 787-788.
33. Sa EJ, Choi YH. Cystic lymphangioma of the breast. *J Clin Ultrasound* 1999; 27: 351-352.
34. Ammari FF, Yaghan RJ, Omari AK. Periductal mastitis. Clinical characteristics and outcome. *Saudi Med J* 2002; 23: 819-822.
35. Dixon JM, Ravisekar O, Chetty U, Anderson TJ. Periductal mastitis: different conditions with different aetiologies. *Br J Surg* 1996; 83: 820-822.