

Portal vein thrombosis after splenectomy for beta-thalassemia major

Zakaria M. Al-Hawsawi, DCH, CABP, Ammar S. Haouimi, DURP, EDUC (France),
Ruhul Amin A. Hassan, FRCSI, Ahmad M. Tarawah, CABP, FPHO.

ABSTRACT

Portal vein thrombosis is a recognized complication after splenectomy in beta-thalassemia major due to the chronic hypercoagulable state which has been recognized to exist in childhood thalassemia and contribute to thromboembolic events. We are reporting one patient with beta-thalassemia major developed portal vein thrombosis following splenectomy.

Saudi Med J 2004; Vol. 25 (2): 225-228

Portal vein thrombosis (PVT) is recognized with increasing frequency by ultrasonography. It is an important condition because of its serious long term complications. Portal vein thrombosis occurs secondary to infection, surgical intervention, abdominal malignancy or as a result of liver dysfunction. It occurs in approximately 5% of patients who have undergone hepatic transplantation.^{1,2} Procoagulant states are established risk factors for PVT.³⁻⁶

Despite the difficulties associated with treatment of thalassemia, standards of care have improved in recent years, resulting in almost doubling the average life expectancy. As a consequence, previously undescribed complications are now being recognized and treated. In particular, the chronic hypercoagulable state, which has been recognized to exist in childhood thalassemia and contribute to thromboembolic events. The hypercoagulable state are partly secondary to protein C and protein S deficiencies along with post splenectomy thrombocytosis.

We report this case of portal vein thrombosis following splenectomy for childhood beta-thalassemia major with associated protein C,

protein S and antithrombin III deficiency. To the best of our knowledge, this is the first case report from the Kingdom of Saudi Arabia.

Case Report. A 10-year-old boy was diagnosed with thalassemia major at 3 years of age. His clinical presentation was of anemia and hepatosplenomegaly with hemoglobin (Hb) electrophoresis showing Hb F of 97% and Hb A2 of 3%. Hypertransfusion regimen was initiated at diagnosis with the aim of maintaining Hb level at 9-10g/dl. Packed red blood cell transfusion was given at 4 weekly intervals. Subcutaneous desferrioxamine was started at 5 years of age when serum ferritin reached 1000ng/dl. His parents were first degree cousins and had two other siblings with beta-thalassemia major.

At 9 years of age, patient underwent open splenectomy secondary to hypersplenism with a smooth postoperative recovery. Preoperative platelet counts were 460,000/mm³ and monitored over the first week post splenectomy and the highest count were 1,000,000/mm³. Twelve days later, the child developed severe abdominal pain with fever.

From the Department of Pediatric (Al-Hawsawi, Tarawah), Department of Pediatric Surgery (Hassan), Department of Radiology (Haouimi), Madina Maternity and Children's Hospital, Madina Al Munawarra, Kingdom of Saudi Arabia.

Received 18th May 2003. Accepted for publication in final form 2nd September 2003.

Address correspondence and reprint request to: Dr. Zakaria M. Al-Hawsawi, Department of Pediatric, Madina Maternity and Children's Hospital, PO Box 6205, Madina Al Munawarra, Kingdom of Saudi Arabia. Fax: +966 (4) 8368333. E-mail: Zhawsawi@yahoo.com

Abdominal examination revealed epigastric tenderness and the laboratory investigation showed thrombocytosis with highest platelet count of 1,465,000/mm³. Abdominal ultrasonography was normal. Pain lasted for few days and disappeared spontaneously. A year later when the child is at 10, partial thrombosis of portal vein was observed during routine abdominal ultrasonography (**Figure 1**). This finding was confirmed by computerized tomography (CT) scan (**Figures 2 & 3**). At that time, the patient was asymptomatic and his physical examination revealed body weight of 26 kg, height 142 cm, all were below third centile for standard age. Other systemic examinations were unremarkable, laboratory tests revealed, white blood cell (WBC) count of 96,000/mm³, hemoglobin 8.4g/dl, platelet count of 1,900,000/mm³, serum ferritin of 2000ng/dl, protein C 0.36 IU/ml (range 0.72 - 1.40), protein S 0.34 IU/ml (range 0.64 - 1.50) and antithrombin III 0.53 IU/ml (range 0.85 - 1.20), all were low. Liver function tests, prothrombin time (PT), partial thromboplastin time (PTT), bleeding time (BT) and clotting time, all were within normal limits. The patient subsequently was started on oral anticoagulant (warfarin) and anti platelet agent (aspirin) at low dosage (81mg/day). The patient was followed regularly at outpatient clinic with laboratory monitoring of the international normalization ratio (INR) and warfarin dose was adjusted to maintain INR between 2-3. At the third month of follow up after starting anti-coagulant therapy, abdominal ultrasonography showed partial recanalization of portal vein.

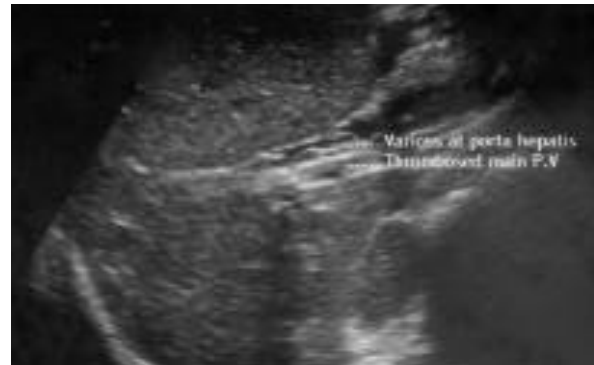

Figure 1 - Abdominal ultrasound at the level of portal vein (PV) showing thrombosis within the main portal vein with varicoses at porta hepatic.

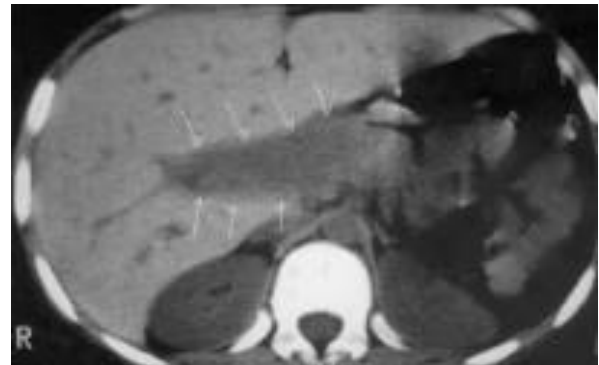


Figure 2 - Plain abdominal computerized tomography showing dilated main portal vein and right branch consistent with thrombosis.

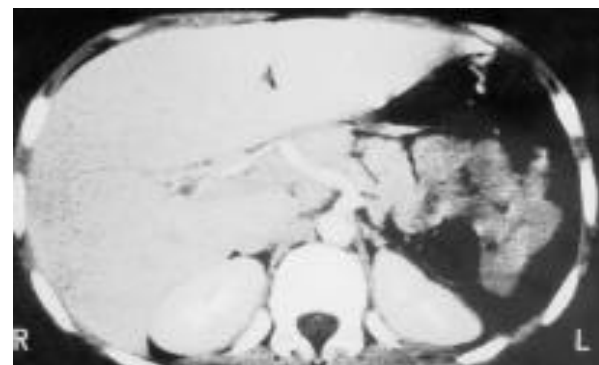


Figure 3 - Enhanced abdominal computerized tomography showing complete thrombosis (lack of opacification) of the main portal vein. The enhanced structures correspond to the aorta, celiac trunk and hepatic artery.

Discussion. In the past, portal vein thrombosis was thought to be rare, but now a days, it is a well-established complication of splenectomy. Recently, it has been reported to occur in an average of 7-10% of patients following splenectomy.^{7,8} Nevertheless, the diagnosis is difficult to make and the index of suspicion often remains low.⁹ Recently, chronic hypercoagulable state is being recognized in association with beta-thalassemia major, which contribute to thrombotic events.¹⁰ It was found to be due to protein C and protein S deficiency.^{10,11} Activation of the coagulation cascade by altered thalassemic red blood cells has also been described.¹² Our patient had a deficiency of protein C, protein S and antithrombin III. The deficiency of antithrombin III is probably following splenectomy, as it has been reported to be significantly deficient in splenectomized thalassemic patients.^{13,14} The added risk factor for thrombosis in our patient was post-splenectomy reactive thrombocytosis. The prevalence of splenectomy at our institute is 34%¹⁵ and we were not screening our patients radiologically for PVT prior to this case.

The clinical presentation of PVT was abdominal pain and fever, which was consistent with other reports.¹⁶ The onset of symptoms occurred 12 days following splenectomy, similar observations were reported by others.¹⁷ The earliest presentation was seen on the sixth day¹⁸ and the delayed one was observed 3 years following splenectomy.¹⁹ Our feeling is that, PVT occurred at 12 days post splenectomy but was missed by ultrasound at the onset of symptoms. This is not rare observation as recent thrombosis had been overlooked by ultrasound, since it is echo-poor and may be indistinguishable from blood flow.²⁰⁻²² Color Doppler ultrasonography is usually required for the diagnosis during acute onset PVT. When PVT goes unrecognized during acute state, symptoms resolve as collateral channels become established and the result may be portal hypertension^{22,23} if not diagnosed and treated early. Thus, we do recommend routine abdominal Doppler ultrasonography following splenectomy in thalassemia, especially, those with risk factors for thrombosis. Chaffanjon et al²⁴ found that systematic ultrasonography has increased the frequency of diagnosis of PVT by 7-folds. Diagnosis of PVT is usually confirmed by contrast-enhanced CT.²⁵ Portal vein thrombosis can lead to serious complication such as bowel gangrene and portal hypertension. Though, these complications do not necessarily occur in all patients, even if the treatment was not initiated at an early stage as in our case. An early diagnosis and prompt initiation of anticoagulant therapy can prevent the development of such lethal complications. Recanalization also occurs with high frequency on anti coagulant therapy²⁶ as it happened in our case indicating that anticoagulant therapy can be effective even if delayed.

Aspirin was used in our case for thrombocytosis, as our patient had significant reactive thrombocytosis. All available literature on the thromboembolic risk of post-splenectomy thrombocytosis is inconclusive because no studies have been established whether patients with thrombocytosis following splenectomy should be treated with anti coagulants or anti-platelet in order to prevent thrombotic complications. Valla et al²⁷ have shown that the thrombotic complication itself is not related to the absolute platelet count but it is more associated with an altered platelet function.

Recently, activated protein C resistance (APCR) has been considered as the most common inherited pre-thrombotic condition. The defect is a point mutation in factor V (R506Q) called factor V Leiden which confers resistance of factor Va to degradation by activated protein C.²⁸ It accounts for up to 50% of cases of thrombophilia and has been reported to be present in thalassemic patients²⁹ increasing the thrombotic risk for PVT. Although, this test is not available at our center, we believe it

may be beneficial to screen all thalassemic patients for APCR especially before splenectomy.

In conclusion, we recommend that PVT should be considered in a patient with abdominal pain and fever after splenectomy and color Doppler ultrasonography imaging is the best non-invasive study for the diagnosis at onset of presentation. We also recommend, routine screening of thalassemic patients for natural coagulation inhibitors (protein C, protein S and anti thrombin III).

Acknowledgment. The authors would like to express their thanks to Dr. Sabah Ibrahim Ammar, Pediatric Registrar in Pediatric Hematology Unit for her help in collecting medical data. Thanks also to Ms. Samira and Mr. Sadiq Ahmed, secretaries in the Department of Pediatric for their secretarial work.

References

- Lallier M, St Vil D, Dubois J, Paradis K, Laberge JM, Bensoussan AL et al. Vascular complication after pediatric liver transplantation. *J Pediatr Surg* 1995; 30: 1122-1126.
- Pariet D, Urvoas S, Riou JY, Tammam S, Husson B, Bihet MH et al. Imaging of complications of liver transplantation in children. *Ann Radiol (Paris)* 1994; 37: 372-376.
- Levoir D, Aubertin JM, Becheur H, Bloch F, Alhenc M, Petite JP. A new hereditary cause of portal vein thrombosis. *Gastroenterology* 1996; 110: 1250.
- Pertuiset E, Tribout B, Wechsler B, Bellin MF, Godeau P, Jian R, et al. Systemic lupus erythematosus presenting with portal vein thrombosis. *Am J Med* 1989; 86: 501-502.
- Fiddler H, Booth A, Hodgson HJF, Calam J, Luzatto L, Hughes JM. Portal vein thrombosis in myeloproliferative disease. Uses of thrombolytic and anti platelet treatments. *Br Med J* 1990; 300: 590-592.
- Green D, Ganger DR, Blei AT. Protein C deficiency in splanchnic venous thrombosis. *Am J Med* 1987; 82: 1171-1174.
- Hassan AM, Al Fallouji MA, Ouf TI, Saad R. Portal vein thrombosis following splenectomy. *Br J Surg* 2000; 87: 362-373.
- Petit P, Bret PM, Atri M, Hreno A, Casola G, Gianfelice D. Splenic vein thrombosis after splenectomy: Frequency and role of imaging. *Radiology* 1994; 190: 65-68.
- Rattner DW, Ellman L, Warshaw AL. Portal Vein Thrombosis after elective splenectomy: An underappreciated, potentially lethal syndrome. *Arch Surg* 1993; 128: 565-570.
- Eldor A, Durst R, Hy-Am E, Goldfarb A, Gillis S, Rachmilewitz EA et al. A chronic hypercoagulable state in patients with beta-thalassaemia major is already present in childhood. *Br J Haematol* 1999; 107: 739-746.
- Shirahata A, Funahara Y, Oparkiattikul N, Fucharoen S, Laosombat V, Yamada K. Protein C and protein S deficiency in thalassaemic patients. *Southeast Asian J Trop Med Public Health* 1992; 23: 65-73.
- Eldor A, Rachmilewitz EA. The hypercoagulable state in thalassaemia. *Blood* 2002; 99: 36-43.
- Shebl SS, El-Sharkawy HM, El-Fadaly NH. Haemostatic disorders in non splenectomized and splenectomized thalassaemic children. *East Mediterr Health J* 1999; 5: 1171-1177.
- Peters TG, Lewis JD, Flip DJ, Morris L. Antithrombin III deficiency causing post splenectomy mesenteric venous thrombosis coincident with thrombocytopenia. *Ann Surg* 1977; 185: 229-231.

15. Al-Hawsawi ZM, Ismail GA, Al-Harbi HA, Al-Sobhi ZR. β -thalassemia major. *Saudi Med J* 2003; 24: 1027-1029.
16. Van't Riet M, Burger JW, Van Muiswinkel JM, Kazemier G, Schipperus MR, Bonjer HJ. Diagnosis and treatment of portal vein thrombosis following splenectomy. *Br J Surg* 200; 87: 1229-1233.
17. Skarsgard E, Doski J, Jaksic T, Wesson D, Shandlim B, Ein S, et al. Thrombosis of the portal venous system after splenectomy for pediatric hematologic disease. *J Pediatr Surg* 1993; 28: 1109-1112.
18. Broe PJ, Conley CL, Cameron JL. Thrombosis of the portal vein following splenectomy for myeloid metaplasia. *Surg Gynecol Obstet* 1981; 152: 488-492.
19. Nagasure N, Inokuchi K, Kobayashi M, Saku M. Mesenteric venous thrombosis occurring late after splenectomy. *Br J Surg* 1977; 64: 781-783.
20. Mori H, Hayashi K, Uetani M, Matsuoka Y, Iwao M, Maeda H. High-attenuation recent thrombosis of the portal vein: CT demonstration and clinical significance. *Radiology* 1987; 163: 353-356.
21. Miller VE, Berland LL. Pulsed Doppler duplex sonography and CT of portal vein thrombosis. *Am J Roentgenol* 1985; 145: 73-76.
22. Albertyn LE. Case report: Acute portal vein thrombosis. *Clin Radiol* 1987; 38: 645-648.
23. Cohen J, Edelman RR, Chopra S. Portal vein thrombosis: A review. *Am J Med* 1992; 92: 173-182.
24. Chaffanjon PC, Brichon PY, Ranchoup Y, Gressim R, Sotto JJ. Portal vein thrombosis following splenectomy for hematologic disease: Prospective study with Doppler color flow imaging. *World J Surg* 1998; 22: 1082-1088.
25. Winslow ER, Brunt LM, Drebin JA, Soper NJ, Klingensmith ME. Portal vein thrombosis after splenectomy. *Am J Surg* 2002; 184: 631-635.
26. Condat B, Pessione F, Helene Denninger M, Hillaire S, Valla D. Recent portal or mesenteric venous thrombosis: increased recognition and frequent recanalization on anti coagulant therapy. *Hepatology* 2000; 32: 466-470.
27. Valla D, Casadevall N, Huisse MG, Tulliez M, Grange JD, Muller O et al. Etiology of portal vein thrombosis in adult: A prospective evaluation of primary myeloproliferative disorders. *Gastroenterology* 1998; 94: 1063-1069.
28. Sun X, Evatt B, Griffin JH. Blood coagulation Factor Va abnormality associated with resistance to activated protein C in venous thrombophilia. *Blood* 1994; 83: 3120-3125.
29. Giordano P, Del Vecchio GC, Altomare M, Coppola B, Schettini F, Iolascon A et al. Resistance to activated protein C in thalassaemic patients: An underlying cause of thrombosis. *Eur J Haematol* 1998; 61: 123-127.