

An abnormal chest radiograph in a 6-year-old boy

Tariq M. Jaber, *ABS, FRCSC*

ABSTRACT

An unexpected finding in a chest radiograph of a child with upper respiratory symptoms is presented as a clinical quiz. The condition is discussed, and the relevant literature is reviewed and summarized.

Saudi Med J 2004; Vol. 25 (3): 379-381

Case Presentation

A 6-year-old Saudi boy was brought to the emergency room with a 3-day history of cough, fever and coryza. The child was earlier found to have iron deficiency anemia, for which he was started on iron supplement. The rest of his past medical history was unremarkable. Examination revealed normal vital signs other than a temperature of 37.8°C. The throat was mildly congested. The chest and abdomen were normal on examination. Chest radiograph was obtained (Figure 1).

Questions

1. What abnormality is seen in this chest x-ray?
2. What is your diagnosis?
3. What further actions you might consider?

Answers

1. The presence of air under the right hemidiaphragm is noticed in both anteroposterior and lateral views.

2. Hepatodiaphragmatic interposition of the intestine (Chilaiditi's syndrome)

3. Nothing at this point. This is a known benign usually asymptomatic condition.

Discussion. Chilaiditi's syndrome or hepatodiaphragmatic interposition of the intestine is a condition in which a part of the intestine, usually the right or transverse colon, is permanently or temporarily lodged between the liver and right dome of the diaphragm.

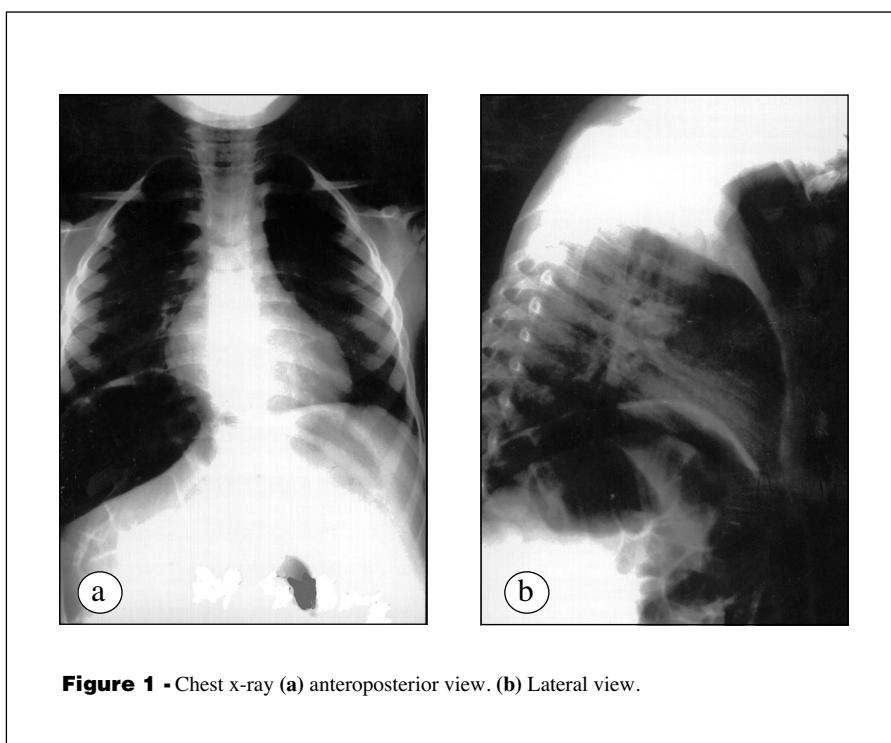
Appreciation of this phenomenon is important in clinical practice and should be considered in the differential diagnosis of radiologically detected air under the diaphragm in patients who are stable or have mild abdominal pain, as it can be easily confused with some serious conditions like subphrenic abscess, pneumoperitoneum and ruptured viscus.¹

This condition was earlier mentioned in 1865. Bécclère² in 1899 gave a pathological description of the entity. This was followed in 1910 by Chilaiditi,³ who studied the syndrome radiologically, proposing an anatomic and physiologic explanation and gave it his name.

From the Department Surgery, King Khalid National Guard Hospital, Jeddah, *Kingdom of Saudi Arabia*.

Received 4th October 2003. Accepted for publication in final form 1st December 2003.

Address correspondence and reprint request to: Dr. Tariq Jaber, PO Box 9515, Jeddah 21423, *Kingdom of Saudi Arabia*. Tel. +966 (2) 6240000 Ext. 2068. Fax. +966 (2) 6240000 Ext. 2071. E-mail: tariqjaber@hotmail.com



The reported incidence of this finding is between 0.1-0.3%. There is, however, an attributable geographical variation and increasing incidence with age up to 10 folds.^{4,5} The male to female ratio ranges from 4:1-10:14.⁵ An incidence of 8.8% was reported in mentally challenged adults.⁶ Other conditions were also found to be associated with increased incidence including cirrhosis of the liver and chronic obstructive lung disease.⁷

Intestinal, hepatic and diaphragmatic factors have all been implicated in the etiology of this syndrome. The list of attributed anatomical predisposing defects includes, redundant or dilated colon secondary to aerophagia or hypotonia, long lax transverse mesocolon with lack of fixity and relaxation of the hepatic suspensory ligament especially when the liver is cirrhotic and shrunken.⁸ Usually it is the hepatic flexure that gets interposed in the subphrenic space, but other parts of the gut have also been involved. Generally, the displacement is anterior and superior to the liver, though posterior displacement has been described, it can be argued that this should be considered as an internal hernia and not a Chilaiditi's syndrome.^{9,10} The condition is generally asymptomatic, commonly diagnosed as an incidental finding in chest radiograph taken for other reasons. When symptoms develop, patients may experience some abdominal discomfort mainly in the right upper quadrant, abdominal distention, nausea, vomiting, audible bowel sounds, constipation and even chest pain.

Chilaiditi's syndrome is usually a benign condition but some catastrophic complications, though very rare, have been reported (obstruction, incarceration, strangulation and colonic and gastric volvulus).⁹ Usually plain x-ray is sufficient to establish the diagnosis and further imaging studies are reserved to situations where there is uncertainty about the diagnosis or when the clinical picture mandates.

The management is usually conservative. Even when symptoms develop, patients are managed by bed rest in supine position, selective use of nasogastric decompression. A stool softeners and enemas may have a role. For serious complications, surgery is indicated.^{8,9,10}

References


1. Bishop CC. Misdiagnosis of the Chilaiditi syndrome. *Br Med J* 1987; 295: 1655.
2. Béclère A. Rectification d'une erreur de diagnostic: ectopie du colon transverse prise a l'examen radioscopique pour un abcès gazeux sousphrenique. *Bulletin et Memoires de la Societe de Medicine de Paris* 1899; 16: 506-507.
3. Chilaiditi D. Zur Frage der Hepatoptose und Ptose in allgemeinen in Anchluss a drei fall von temporarer, partieller Lebersverlagerung. *Fortschr Geb Rotgenstr Nuklearmed Ergänzungsband* 1910; 16: 173-208.
4. Haddad CJ, Laclé J. Chilaiditi's syndrome. A diagnostic challenge. *Postgrad Med* 1991; 98: 249-252.
5. Torgersen J. Suprahepatic interposition of the colon and volvulus of the cecum. *American Journal of Roentgenology, Radium Therapy and Nuclear Medicine* 1951; 66: 747-751.

6. Lekkas CN, Lentino W. Symptom-producing interposition of the colon in mentally deficient adults. *JAMA* 1978; 240: 747-750.
7. Vessal K, Borhanmanesh F. Hepatodiaphragmatic interposition of the intestine (Chilaiditi's syndrome). *Clin Radiol* 1976; 27: 113-116.
8. Melester T, Burt ME. Chilaiditi's syndrome. Report of three cases. *JAMA* 1985; 254: 944-945.
9. Orangio GR, Fazio VW, Winkelman E, McGonagle BA. The Chilaiditi syndrome and associated volvulus of the transverse colon. An indication for surgical therapy. *Dis Colon Rectum* 1986; 29: 653-656.
10. Pritchard GA, Price-Thomas JM. Internal hernia of the transverse colon. A new syndrome. *Dis Colon Rectum* 1986; 29: 257-258.

SAUDI MEDICAL JOURNAL SUPPLEMENTS

- **MEDICAL JOURNALISM**

(Vol. 25 Supplement 1 January 2004)



- **HEPATITIS C VIRUS (with Consensus Guideline)**

(Vol. 24 Supplement 2 July 2003)



- **PEDIATRIC SURGERY**

(Vol. 24 Supplement 1 May 2003)



TO ORDER:

Call: +966 1 477 7714 ext. 6577, 6570, 6596, 6579 Fax: +966 1 476 1810/ 477 7194
e-mail: info@smj.org.sa