

Lymphangiomas in infancy and childhood

Ahmed H. Al-Salem, FACS, FICS.

ABSTRACT

Objectives: Lymphangiomas are rare congenital malformations, commonly seen in the head and neck. This is a review of our experience in the management of 22 children with lymphangiomas.

Methods: The medical records of children with lymphangioma admitted to Qatif Central Hospital, Qatif, Kingdom of Saudi Arabia over a period of 10 years from August 1989 to July 2000 were retrospectively reviewed for age at diagnosis, gender, mode of presentation, site of lymphangioma, method of treatment and outcome.

Results: We treated 22 children (12 females and 10 males) with lymphangioma. Their ages ranged from birth to 12 years, but majority (73%) were 4 years of age or younger. In 10 (45.5%), the lymphangioma involved the neck, 5 of them presented with sudden neck swelling as a result of hemorrhage into a lymphangioma, which caused diagnostic confusion. One patient had extensive lymphangioma involving the floor of the mouth, tongue, and left parotid gland. The remaining 11 patients had lymphangioma involving the parotid gland in 2, floor of

the mouth in 3, and one each in the abdominal wall, above the right knee, mediastinum, breast, scrotum, and mesentery. All were treated surgically except 3 who were treated with intralesional bleomycin and showed complete disappearance of their lesions. There was recurrence in the child with mediastinal lymphangioma and a small recurrence in the child with bilateral lesions in the floor of the mouth.

Conclusion: Lymphangiomas are relatively rare, involving mainly the head and neck, but they can be rarely seen at other sites. An important observation is the sudden appearance of cervical lymphangioma as a result of hemorrhage, which should be kept in mind. Our experience in the treatment of lymphangiomas using bleomycin is limited to draw any conclusions. We therefore considered surgery as treatment of choice for lymphangiomas. However, sclerotherapy can be used when there is a risk of damaging surrounding structures, and also to obviate the poor cosmetic results.

Saudi Med J 2004; Vol. 25 (4): 466-469

Lymphangiomas are rare congenital malformations of the lymphatic system that can appear at any age or site, but commonly seen in the cervical region and the majority are diagnosed at birth.¹ Although benign, and commonly asymptomatic, they can sometimes cause pressure and life threatening complications especially massive lesions involving the neck and mediastinum in newborn infants or cause a diagnostic confusion as a result of sudden enlargement following hemorrhage or infection.¹⁻³ This is a report of 22 infants and children with lymphangiomas at different sites, outlining aspects of diagnosis and management.

Methods. The medical records of all children with the diagnosis of either lymphangioma or cystic hygroma admitted to Qatif Central Hospital, Qatif, Kingdom of Saudi Arabia from August 1989 to July 2000 were retrospectively reviewed and the following informations were collected: age at diagnosis, gender, site of lymphangioma, mode of presentation, method of treatment and outcome. The operative findings and histological features were obtained from the operative notes and histopathology report.

Results. Twenty-two children (12 females: 10 males) with the diagnosis of lymphangioma were

From the Department of Surgery, Division of Pediatric Surgery, Qatif Central Hospital, Qatif, Kingdom of Saudi Arabia.

Received 9th September 2003. Accepted for publication in final form 28th December 2003.

Address correspondence and reprint request to: Dr. Ahmed H. Al-Salem, PO Box 61015, Qatif 31911, Kingdom of Saudi Arabia. Tel. +966 55818009. Fax. +966 (3) 8630009. E-mail: asalem56@hotmail.com

treated at our hospital. Their ages at diagnosis ranged from birth to 12 years, but in the majority of them (73%), the diagnosis was made at 4 years of age or younger. In 10 (45.5%), the lymphangioma involved the neck (8 posterior triangle, one submandibular, one supraclavicular). Five of them without prior history presented with sudden appearance of neck swelling which caused diagnostic confusion. All 5 children were found to have sudden hemorrhage into a cervical lymphangioma (**Figure 1**) and the diagnosis was confirmed histologically. All the cervical lymphangiomas were treated surgically except in one who was treated with sclerotherapy (bleomycin 0.6 mg/kg). He required 2 injections of bleomycin with total disappearance of the lesion. One of our patients was seen as a newborn with multiple lymphangiomas involving the floor of the mouth, tongue and left parotid gland (**Figure 2**). She was treated conservatively and on follow-up, there was marked regression of the floor of the mouth lymphangioma except for a ranula swelling on the right side. This was treated surgically at the age of 3 years. It was opened, deroofed and marsupialized. The tongue lymphangioma decreased markedly and only multiple superficial cystic swellings were seen on the dorsum of the tongue at the age of 2.5 years. These were excised using diathermy. The left parotid lymphangioma increased in size, and she underwent excision, but there was a recurrence. This was subsequently treated with one injection of sclerotherapy using bleomycin, with total disappearance. Now she is 15-year-old with no evidence of recurrence. Two other patients with parotid lymphangioma were treated. One was a 9-year-old girl with left parotid lymphangioma treated surgically while the other was a 6-month-old female with right parotid lymphangioma treated with bleomycin sclerotherapy. Both of them showed complete disappearance of their lesions. The 2 children with parotid lymphangioma treated surgically were difficult to excise but fortunately, the lymphangiomas involved the superficial part of the gland only. Three patients had lymphangioma of the floor of the mouth. All were treated with marsupialization of the cysts. One of them had bilateral lesions. This patient developed a small recurrence on the right side and currently being followed up in the clinic. A 10-year-old girl presented with lymphangioma above the right knee, treated by excision, and a newborn with a large abdominal wall (lumbar region) lymphangioma is currently being followed up. She will subsequently require excision. Four of our patients presented with lymphangiomas at unusual sites including the mediastinum, the mesentery, left breast and scrotum. The child with scrotal lymphangioma was a 3-year-old boy who presented with right scrotal swelling that was diagnosed as a hydrocele. Intra

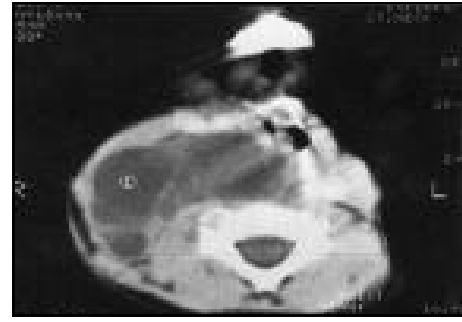

Figure 1 - Computerized tomography scan of the neck showing hemorrhage in a cervical lymphangioma.

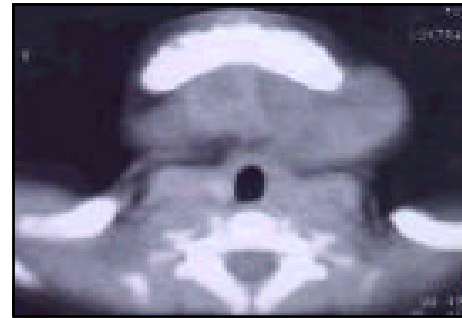


Figure 2 - Computerized tomography scan of the neck showing extensive lymphangioma of the floor of the mouth and left parotid gland.

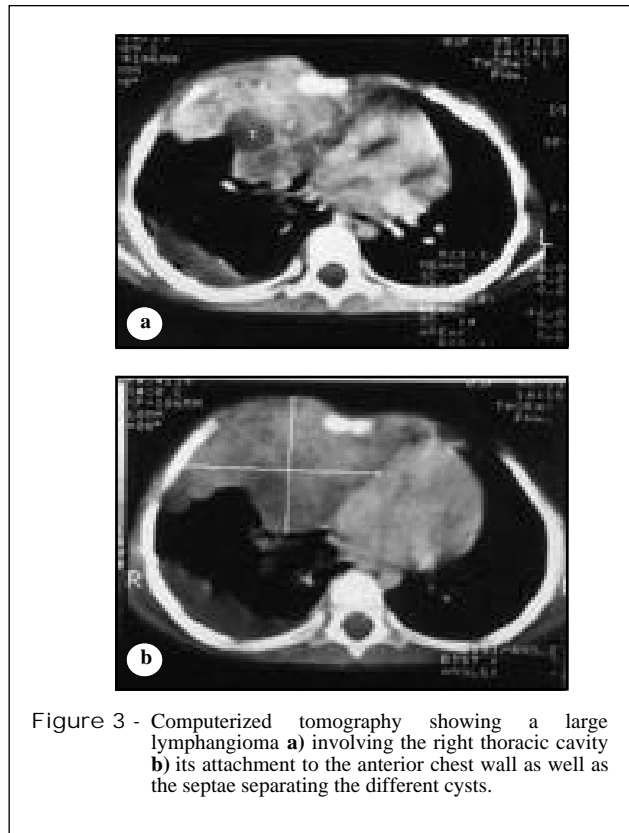


Figure 3 - Computerized tomography showing a large lymphangioma **a**) involving the right thoracic cavity **b**) its attachment to the anterior chest wall as well as the septae separating the different cysts.

operatively, he was found to have a lymphangioma that was separate from the testis and epididymis which was completely excised. A one-year-old girl presented with left breast enlargement, and clinically was found to have lymphangioma at the periphery of the left breast. This was excised surgically and histology proved this lymphangioma involving the breast. Two of our patients presented with a large mediastinal and mesenteric lymphangiomas. A 3-year-old female presented with chest pain and bulging of the right side of the chest, and chest x-ray revealed a soft tissue density on the right side with pleural effusion which was also confirmed by CT scan (**Figure 3a and 3b**). She underwent thoracotomy and excisional biopsy. This was followed by a subsequent thoracotomy and total excision of the tumor. Both biopsies proved this to be a lymphangioma. Postoperatively, she did well, but on follow up 15 months later, she was found to have a recurrence. The family was offered surgery but they refused. The other patient was also a 3-year-old male, who was admitted to the hospital due to abdominal pain and vomiting. Abdominal ultrasound and computerized tomography scan revealed a large multiseptate cystic swelling occupying most of the abdominal cavity. Laparotomy revealed a large cystic swelling arising from the mesentery of the small bowel and encroaching on a loop of ileum that was very adherent to the cyst wall. The cyst as well as this part of ileum were excised and histology proved it as a large lymphatic cyst.

DISCUSSION. Most lymphangiomas, which are benign developmental malformations of the lymphatic system, occur in the head and neck with the cervical region being the commonest site.¹ In 16 (72.7%) of our patients, lymphangiomas occurred in the head and neck, and in 10 (45.5%), the cervical region was affected. The majority of lymphangiomas being congenital were diagnosed at birth and over 90% were diagnosed by the fourth year of life.¹ In our series, 73% were diagnosed by the age of 4 years. Lymphangiomas can however appear at any age. This is specially at sites other than the head and neck including the abdomen and mediastinum where they can attain a large size before being clinically apparent. This was the case in 2 of our patients. Sometimes they can attain a large size as a result of infection or hemorrhage. This can cause pressure symptoms or life-threatening complications at sites such as the mediastinum. An important observation we noted in 5 of our patients was the sudden appearance of cervical lymphangioma as a result of bleeding. This caused diagnostic confusion and the final diagnosis was confirmed only intraoperatively and by histology. The possibility of lymphangioma should always be considered in children with sudden

appearance of a cervical swelling. The lymphangiomas are rare lesions, and their exact incidence is not known. Gupta⁴ reported an incidence of one case in approximately 4,000 live births. Nicholls et al¹ reported an incidence of one in 6,500 live births. The exact incidence in Saudi Arabia is not known. Kennedy³ has classified lymphangiomas into 5 groups as follows: (1) superficial cutaneous lymphangioma (lymphangioma simplex and lymphangioma circumscriptum), (2) cavernous lymphangioma, (3) cystic hygroma, (4) diffuse system lymphangioma and (5) mixed lymphangioma. Although lymphangiomas occur most commonly in the head and neck area, they can be seen rarely at other sites including the mediastinum (5), mesentery (6), scrotum (7), spleen (8), breast (9), retroperitoneum (10) and bones (11). Four of our patients had lymphangiomas at rare sites including the breast, scrotum, mediastinum and mesentery. Although rare, lymphangioma should be considered in the differential diagnosis of children presenting with cystic swellings at these unusual sites.

The treatment of lymphangiomas continues to be a challenge. Although spontaneous regression of lymphangiomas has been reported as in one of our patients, it is however rare. It may be reasonable to treat small asymptomatic lymphangiomas expectantly. The treatment of lymphangiomas is early surgery as this is technically easier before further invasion of normal tissue or scarring secondary to infection has occurred. This however needs to be a complete radical resection, as with an incomplete resection the danger of a recurrence with tendency to invasive growth. Although surgical excision has been considered the treatment of choice by most surgeons, sclerotherapy with OK-432 (produced from the low virulent strain of type 3, group A *Streptococcus pyogenes*) and bleomycin has gained popularity during recent years.¹² Rantio et al¹² found OK-432 safe and effective in the treatment of lymphangiomas, and Claesson and Kuylenstierna¹⁴ proposed OK-432 to be the first choice of treatment of lymphangioma. Banieghbal and Davies¹⁵ found that macrocystic lymphangiomas respond almost universally to OK-432 injections, whereas patients with microcystic lesions generally do not respond and should not therefore be injected with OK-432. Hall et al¹⁶ reported that OK-432 injection was effective in approximately one third of children with lymphangiomas and cysts larger than 5 cm are unlikely to respond to this therapy.¹⁶ They also advised against using this form of therapy for lesions outside the head and neck and for lymphangiomas surrounding the airways.¹⁶

Our experience in the treatment of lymphangiomas using bleomycin is limited to draw any conclusions, but we consider surgery as the

treatment of choice for lymphangiomas. Sclerotherapy has a place in the treatment of lesions where there is risk of damaging surrounding structures as well as to obviate the poor cosmetic results. Sclerotherapy can also be used as an adjunctive therapy in the treatment of wide spread and incompletely excised lymphangiomas.

References

- Nicholls EA, King PA, McMullin ND. A decade of pediatric lymphangiomas. *Pediatr Surg Int* 1991; 6: 421-424.
- Emery PJ, Bailey CM. Cystic hygroma of the head and neck, A review of 37 cases. *J Laryngol Otol* 1984; 98: 613-619.
- Kennedy TL. Cystic hygroma- lymphangioma: a rare and still unclear entity. *Laryngoscopy* 1989; 99: 1-10.
- Gupta B. Incidence of congenital malformations in Nigerian Children. *West Afr Med J* 1969; 18: 22-23.
- Shefty RC, Aggarwal BK, Kamath SG, Prabhu P, Aggarwal M, Rao L. Giant cystic lymphangioma of the middle mediastinum. *Indian J Chest Dis Allied Sci* 2003; 45: 125-129.
- Losanoff JE, Richman BW, El-Sherif A, Rider KD, Jones JW. Mesenteric cystic lymphangioma. *J Am Coll Surg* 2003; 196: 598-603.
- Loberant N, Chernihovski A, Goldfeld M, Sweed Y, Vais M, Tzilman B, Cohen I. Role of Doppler sonography in the diagnosis of cystic lymphangioma of the scrotum. *J Clin Ultrasound* 2002; 30: 384-387.
- Solomou EG, Patriarheas GV, Mpadra FA, Karamouzis MV, Dimopoulos I. Asymptomatic adult cystic lymphangioma of the spleen. Case report and review of the literature. *Magn Reson Imaging* 2003; 21: 81-84.
- Chung SY, Oh KK, Kim DJ. Mammographic and sonographic findings of a breast cystic lymphangioma. *J Ultrasound Med* 2003; 22: 307-309.
- Tsukamoto T, Tanaka S, Yamamoto T, Kakinoki E, Uemichi A, Kubo S et al. Laparoscopic excision of a retroperitoneal cystic Lymphangioma. Report of a case. *Surg Today* 2003; 33: 142-144.
- Sakamoto A, Matsuda S, Tanaka K, Shukuri T, Harimaya K, Iwamoto Y. Solitary lymphangioma of the femure. A case report. *J Orthop Sci* 2002; 7: 501-504.
- Sanlialp I, Karnak I, Tanyel FC, Senocak ME, Buyukpamukcu N. Sclerotherapy for lymphangioma in children. *Int J Pediatr Otorhinolaryngol* 2003; 67: 795-800.
- Rautio R, Keski-Nisula L, Laranne J, Laasonen E. Treatment of Lymphangiomas with OK-432 (Picibanil). *Cardiovasc Intervent Radiol* 2003; 26: 31-36.
- Claesson G, Kuylenstierna R. OK-432 therapy for lymphatic malformation in 32 patients (28 children). *Int J Pediatr Otorhinolaryngol* 2003; 133: 238-242.
- Banieghbal B, Davies MR. Guidelines for the successful treatment of Lymphangioma with OK-432. *Eur J Pediatr Surg* 2003; 13: 103- 107.
- Hall N, Ade-Ajayi N, Brewis C, Roebuck DJ, Kiely EM, Drake DP et al. Is intralesional injection of OK-432 effective in the treatment of Lymphangioma in Children? *Surgery* 2003; 133: 238-242.