

Jaffe–Campanacci syndrome

Ammar C. Al-Rikabi, FRCPath, FIAC, Jyothi C. Ramaswamy, MBBS, MD, Venkatraman V. Bhat, MD, FRCR.

ABSTRACT

This case report describes the clinical, radiological and histopathological features of the Jaffe–Campanacci syndrome as seen in a 6-year-old Qatari male patient who was initially misdiagnosed as a case of systemic neurofibromatosis. Our case has all the diagnostic stigmata of Jaffe–Campanacci syndrome as described in the literature and these include café au lait macules, skeletal deformities and multiple histologically confirmed non-ossifying fibromas of the long bones.

Saudi Med J 2005; Vol. 26 (1): 104-106

Jaffe–Campanacci syndrome is characterized by the presence of numerous or multifocal non-ossifying fibromas. The disorder could be familial and it usually associated with cutaneous café au lait spots.

We describe the clinicopathological and radiological features of the syndrome as encountered in a 6-year-old Qatari male who was presented with multiple bony lesions and was previously diagnosed as a case of neurofibromatosis.

Case Report. A 6-year-old Qatari male patient was referred to the Department of Orthopedic, Hamad General Hospital, Doha, Qatar due to a slowly enlarging right upper tibial lytic bone lesion. Clinical examination revealed that the patient has right severe genu varus deformity with leg shortening by about 1.5 cm as well. The patient has had a previous clinical diagnosis of neurofibromatosis due to a large and confluent café au lait spot skin lesion, which was extending from his pubis and over the internal aspects of the right thigh and in a radicular distribution, which suggested a disorder of neuroectodermal origin. There was, however, no histological confirmation of

his neurofibromatosis diagnosis and a brain scanogram was reported to be within normal limits. There was no clinical evidence of scoliosis. X-rays and scanograms of the right lower limb showed several lucencies in the distal femur and proximal tibia. There was intensive sclerotic reaction in the upper metaphysis of the right tibia with persistent cortical defect and the medical aspect (**Figure 1**).

Fibrous cortical bony changes were also noted in the medial part of the lower metaphysis of femur. In addition, there was a similar defect in the distal third of the tibia. However, this latter lesion was not showing signs in progression as the right upper metaphyseal tibial lesion did. Due to the enlarging nature and size of the right upper tibial lucency, curettage was performed on the lesion with bone grafting. During operation, several friable gray brown tissue fragments were curetted from the tibial lesion, which appeared to be extending into the bone metaphysis by at least 0.5 cm. The material obtained was subsequently sent for histopathological examination.

Histopathological findings. The material received by the histopathology laboratory consisted of a few brown and irregular soft tissue fragments all measuring 2 x 1.5 x 0.5 cm. Sections from the

From the Department of Histopathology (Al-Rikabi, Ramaswamy) and the Department of Radiology (Bhat), Hamad General Hospital, Doha, Qatar.

Received 5th July 2004. Accepted for publication in final form 18th September 2004.

Address correspondence and reprint request to: Dr. Ammar C. Al-Rikabi, Chairman and Consultant Histopathologist, Department of Laboratory Medicine and Pathology, Hamad General Hospital, PO Box 3050, Doha, Qatar. Tel. +974 4392591. Fax. +974 4312751. E-mail: ammar_rikabi@hotmail.com

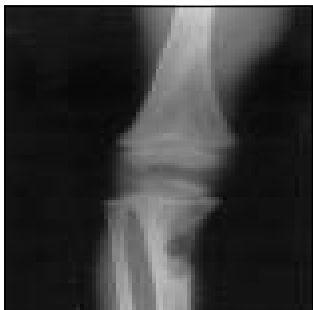

Figure 1 - Anteroposterior x-ray view of the right leg showing metaphyseal cortical defect in upper tibia surrounded by an intense sclerotic reaction. A second oval lytic bone lesion is also seen in lower femur. The radiological features are consistent with non-ossifying fibroma.

above described material showed a proliferating fibroblastic and spindle cell stroma with storiform features and a variable number of multinucleated giant cells (Figure 2). Elsewhere in the lesion, mononuclear inflammatory cells and a small number of histiocytes were also seen. Immunohistochemical stains showed strong and confluent positive staining with vimentin (mesenchymal cells marker) and negative staining with S100 protein (marker for Schwann cells). Based on the above histological features a diagnosis of non-ossifying fibroma (also called metaphyseal fibrous defect, fibroma and fibrous cortical defect) was made. Furthermore, clinicopathological and radiological correlation enabled us to label this patient as a case of Jaffe–Campanacci syndrome.^{1,3}

Discussion. Non-ossifying fibromas or metaphyseal fibrous defect are distinctive lesions of bone that occur in children and adolescents, most of them affecting upper or lower tibia or the lower femur.^{4,5} Multifocal non-ossifying fibromas may be familial or associated with cafe' au lait spots and in such cases they constitute the Jaffe-Campanacci syndrome.^{1,2} There has been a long standing and still unresolved controversy regarding whether non ossifying fibromas are neoplastic or whether they principally represent developmental aberration at the epiphyseal plate.⁶ Grossly, these lesions are granular and brown or dark red and microscopically, they consist of cellular masses of fibrous tissue often arranged in a storiform pattern with many

osteoclastic giant cells. Indeed, the microscopic appearance is very reminiscent of benign fibrous histiocytoma.⁷ Clinically, there are usually few or no symptoms except pain. The lesions may even be found incidentally on x-ray examination but can cause pathological fractures through the thinned bony cortex if large in size.⁸ Cafe' au lait spots are uniformly pigmented, tan to dark brown macules, which vary in size from small, freckle-like lesions to large patches which are 20 cm or more in diameter. They may be present at birth or develop within the first few years of life.⁹ They are found in approximately 15% of individuals.¹⁰ Multiple cafe' au lait spots are a feature of neurofibromatosis especially clinical type 4 and 6,⁹ but familial, multiple cafe' au lait spots have also been reported without any evidence of co-existing neurofibromatosis¹¹ as indeed, the case in our patient.

Our case has all the diagnostic stigmata of Jaffe-Campanacci syndrome as described by Mirra et al,² which include skeletal deformities, multiple non-ossifying fibromas and a single and large cafe' au lait macule without any histological evidence of neurofibromatosis. In addition, the reported incidence of bone abnormalities in neurofibromatosis was between 9-37%.¹² These include scoliosis, orbital wall defects and growth disturbances. Our patient did not show any of these changes nor did he have more than 6 cafe' au lait spots, which is a requirement for the diagnosis of neurofibromatosis as indicated by Von Riccardi.⁹ Finally, in young patients with lytic bone lesions, and single or few cutaneous cafe' au lait spots, the clinicians are warned against making a definite diagnosis of systemic neurofibromatosis. Non ossifying fibromas with or without familial Jaffe-Campanacci syndrome should be considered and confirmed by histopathological examination.

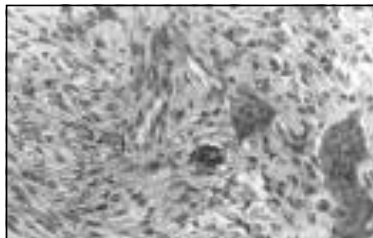


Figure 2 - Non-ossifying fibroma showing a cellular, spindle pattern with three multinucleated giant cells. Hematoxylin and eosin stain x 400.

Acknowledgment. The authors would like to thank Ms. Soja Andipet for her excellent secretarial skills. Our thanks also goes to Dr. Andrew Wozniak and Dr. Abdul Rehman Khan for their comments on the clinical presentation of this patient.

References

1. Campanacci M, Laus M, Boriani S. Multiple non ossifying fibromata with extra skeletal anomalies: a new syndrome? *J Bone Joint Surg Br* 1983; 65: 627-632.
2. Mirra JM, Gold RH, Rand F. Disseminated non ossifying fibromas in association with cafe'-au-lait spots (Jaffe-Campanacci Syndrome). *Clin Orthop* 1982; 168: 192-205.
3. Moser RP Jr, Sweet DF, Haseman DB. Multiple skeletal fibroxanthomas: Radiologic-pathologic correlation of 72 cases. *Skeletal Radiol* 1987; 16: 353-359.
4. Jaffe HL, Lichenstein L. Non osteogenic fibroma of bone. *Am J Pathol* 1942; 18: 205-221.
5. Cunningham JB, Ackerman LV. Metaphyseal fibrous defects. *J Bone Joint Surg Am* 1956; 38: 797-808.
6. Hatcher CH. Pathogenesis of localized fibrous lesion in the metaphyses of long bones. *Ann Surg* 1945; 122: 1016-1030.
7. Clarke BE, Xipell JM, Thomas DP. Benign fibrous histiocytoma of bone. *Am J Surg Pathol* 1985; 9: 806-815.
8. Arata MA, Peterson HA, Dahlin DC. Pathological fractures through non ossifying fibromas. Review of the Mayo Clinic experience. *J Bone Joint Surg Am* 1981; 63: 980-988.
9. Von Riccardi VM, Recklinghausen neurofibromatosis *N Engl J Med* 1981; 305: 1617-1627.
10. Mclean DI, Gallagher RP. "Sunburn" freckles, cafe'-au-lait macules and other pigmented lesions of school children: the Vancouver mole study. *J Am Acad Dermatol* 1995; 32: 565-570.
11. Arnsmeier SL, Riccardi VM, Paller AS. Familial multiple cafe'-au-lait spots. *Arch Dermatol* 1994; 130: 1425-1426.
12. Hunt JC, Pugh DG. Skeletal lesions in neurofibromatosis. *Radiology* 1961; 76: 1-20.