

Rare variation of the celiac trunk and related review

Kadir Demirtas, MD, Nadir Gulekon, MD, PhD, Ayla Kurkuoglu, MD, Alper Yildirim, MD, Rabet Gozil, PhD.

ABSTRACT

In this study, we report a rare variation of the branching of the celiac trunk. During a routine abdominal dissection on a female cadaver, we found the celiac trunk to emerge from the abdominal aorta as 2 roots named hepatogastric trunk and hepatosplenic trunk. The hepatogastric trunk arises from the anterior surface of the abdominal aorta and divides into an aberrant branch to the right lobe of the liver, a branch to the right hemi diaphragm, the left hepatic and the left gastric arteries. The hepatosplenic trunk, which arises 1.5 cm below the hepatogastric trunk, gave off the common hepatic and splenic arteries. The common hepatic artery divided into the gastroduodenal, the right branch to the hepatic and the cystic arteries. It is important to know the variations of hepatogastric trunk and hepatosplenic trunk for the success of surgical operations to the liver and radiological investigations of those regions.

Saudi Med J 2005; Vol. 26 (11): 1809-1811

During the embryological stage, each metamer consists of 3 pairs of arteries that originate from the anterior, posterior, and lateral faces of the aorta. Posterior pairs then grow as intestinal arteries. Primitive metameric intestinal arteries (vitellin arteries) join to the longitudinal anterior anastomosis. These metameric arteries, and ventral anastomosis regress during development of the embryo and when the embryo reaches nearly 9 mm, the celiac trunk, superior mesenteric artery, and inferior mesenteric artery become visible. When the embryo is approximately 12.5 mm, the form of adult vascularization is reached. However, in some cases, one of these primitive arteries may not develop and the anterior anastomosis result in variations.¹⁻² The celiac trunk is a short (1.25 cm), and thick (7-20 mm) branch. It originates from the anterior aspect of the aorta just below the aortic hiatus at the level of 12th thoracic vertebrae, travels anterolaterally, and gives off 3 main branches; left gastric artery, common hepatic artery, and splenic artery.³ Haller⁴

was the first to report 3 main branches of celiac trunk. Vandamme and Bonte³ reported the incidence of these as 90% and 86% and other authors illustrated the reported variations in the branching of celiac trunk.⁵ In this study, we report 2 rare variations; the hepatogastric trunk and hepatosplenic trunk in the same case. Our aim is to emphasize the importance of the rare variations of these arterial structures, which may lead to misinterpretation in radiographic examinations and complications during abdominal surgical procedures.

Case Report. During routine abdominal dissection on a female cadaver, at the level of thoracic 12th-lumbar 1st vertebrae, just below the aortic hiatus, on the anterior aspect of abdominal aorta, the hepatogastric trunk was observed. Approximately one cm below and right to this root, the hepatosplenic trunk was visible. The celiac trunk was noticed to originate as 2 roots; inferior and

From the Department of Anatomy (Demirtas, Yildirim), School of Medicine, Yeditepe University, Istanbul, and the Department of Anatomy (Gulekon, Kurkuoglu, Gozil), School of Medicine, Gazi University, Ankara, Turkey.

Received 11th April 2005. Accepted for publication in final form 10th July 2005.

Address correspondence and reprint request to: Dr. Rabet Gozil, Professor, Department of Anatomy, Faculty of Medicine, Gazi University, Besevler 06500, Ankara, Turkey. Tel. +90 (312) 2026976. Fax. +90 (312) 2124647. E-mail: rabetg@gazi.edu.tr

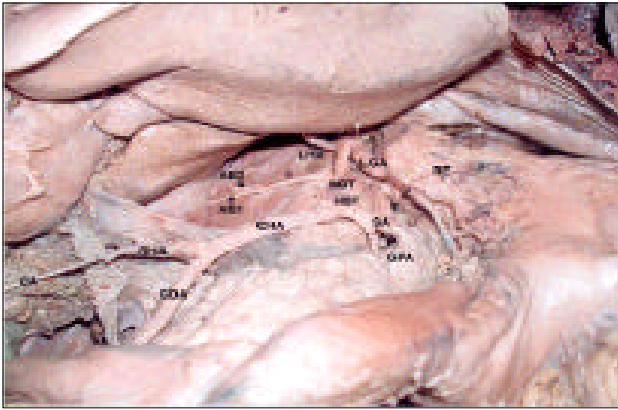


Figure 1 - Variable branches of the celiac trunk from the anterior view of the supramesocolonic area: hepatogastric trunk (HGT), aberrant branch to the right lobe of liver (AB1), aberrant branch to right hemidiaphragm (AB2), left hepatic artery (LHA), left gastric artery (LGA), esophageal ramie (RE), hepatosplenic trunk (HST), splenic artery (SA), common hepatic artery (CHA), gastroduodenal artery (GDA), right hepatic artery (RHA), cystic artery (CA), and greater pancreatic artery (GPA).

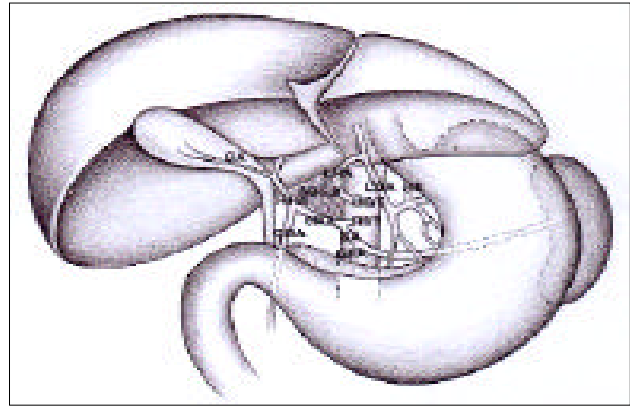


Figure 2 - Schematic representation of variable branches of the celiac trunk: hepatogastric trunk (HGT), aberrant branches to the right lobe of liver (AB1) and to right hemidiaphragm (AB2), left hepatic artery (LHA), left gastric artery (LGA), esophageal ramie (RE), hepatosplenic trunk (HST), splenic artery (SA), common hepatic artery (CHA), gastroduodenal artery (GDA), right hepatic artery (RHA), cystic artery (CA), and greater pancreatic artery (GPA).

superior, from the anterior aspect of abdominal aorta at the level of thoracal 12th-lumbar 1st vertebrae (**Figures 1 & 2**). The superior root was in the form of the hepatogastric trunk forming an arch posterosuperiorly, giving 2 branches to the liver. The thinner one originated from 1 cm of the beginning of celiac trunk and proceeded to the right; after 2 cm, divided into 2 smaller branches; one for the right lobe of liver and the other for right hemidiaphragm. The thicker branch originating from the hepatogastric trunk crossed to the left lobe of the liver (left hepatic artery). The last branch of hepatogastric trunk was the left gastric artery going to the lesser curvature of the stomach. Left gastric artery here divided into 3 branches; esophageal ramie originated from the superior branch whereas the other 2 were divided again into small branches and followed to the lesser curvature (**Figures 1 & 2**).

The inferior root was in the form of hepatosplenic trunk and originated from the anterior surface of the abdominal aorta 1 cm more distal to the superior. This root gave off the branches of common hepatic artery and splenic artery. The splenic artery was positioned to the left along the superior edge of pancreas, giving the branch of great pancreatic artery before entering the splenic hilum. The common hepatic artery was longer along the edge of head of pancreas passing to the right superiorly. The common hepatic artery, gave gastroduodenal branch and continued as right hepatic artery superior to the upper part of duodenum, anterior to portal vein, and below to the caudate lobe of liver. Eventually before entering the right lobe of the liver, the hepatic artery gave off cystic artery (**Figures 1 & 2**). There was no other variation of the abdominal arterial system.

DISCUSSION. The celiac trunk and its branches may show several variations.^{1-3,6} Weiglein⁷ reported the study of celiac trunk in 138 cadaver dissections that in only 9% of the cases, the celiac trunk was in the normal position. Other authors reported in the absence of celiac trunk and left the gastric artery, splenic artery and common hepatic artery originated directly from the abdominal aorta.³ Basar et al⁵ instead of celiac trunk, described a trunk that emerged from the abdominal aorta at the level of first lumbar vertebrae with gastroduodenal artery, hepatic artery, inferior pancreaticoduodenal artery, splenic artery, left gastric artery, and jejunal branches. Vandamme and Bonte³ claimed the frequency of 3-branched celiac trunk as 86%, 2-branched celiac trunk as 12%. They further pointed out that in 2 branched forms namely "hepatosplenic trunk and left gastric artery" and "hepatogastric trunk and splenic artery" all concerned branches originated from the abdominal aorta separately.³ Caty et al⁸ observed that the celiac trunk branched as a splenic artery and a common hepatic artery, left gastric artery originated directly from abdominal aorta. Kahraman et al¹ reported 2 roots originating from the abdominal aorta instead of a typical celiac trunk. One of these was the gastrosplenic trunk that in turn gave rise to the left gastric artery and splenic artery; and the other was the hepatomesenteric trunk that gave rise to the common hepatic artery and superior mesenteric artery.

In this study, we observed that the celiac trunk emerged as 2 different roots. The superior root: hepatogastric trunk with the branches of left hepatic artery, left gastric artery and an aberrant branch,

which supplied the right lobe of the liver. The inferior root: the hepatosplenic artery separated into 2 branches called splenic artery and common hepatic artery. However, Nonent et al² described the celiac trunk, superior mesenteric artery, and inferior mesenteric artery to originate from the abdominal aorta as one trunk, named celiac-bimesenteric trunk. Oran et al⁹ demonstrated 2 variations; as 1. the right hepatic artery origination directly from the abdominal aorta and 2. the splenomesenteric trunk from the abdominal aorta in turn dividing into the branches as splenic and superior mesenteric arteries. Some investigators reported that the splenic artery always emerged from the celiac trunk. The common hepatic artery and inferior mesenteric artery were observed to emerge from the splenic artery.³ In the present study, the splenic artery emerged from the hepatosplenic artery. Descomps¹⁰ reported that the common hepatic artery always emerged from the celiac trunk. However, there may be origin anomalies of common hepatic artery. It can originate directly from the abdominal aorta (1%) or superior mesenteric artery (7%).³ According to Nagino et al,¹¹ the right anterior hepatic artery branch separated from the superior mesenteric artery. Paduraru¹² showed an accessory hepatic artery, which separated from the first segment of the superior mesenteric artery. In our study, we observed an aberrant branch and left hepatic artery both originating from the hepatogastric trunk leading to right and left lobes of liver, and the common hepatic artery from the hepatosplenic trunk, which in turn gave rise to a right hepatic branch. There may be some origin anomalies of left gastric artery as well, which may originate directly from abdominal aorta, from splenic artery, from hepatic artery, and from inferior phrenic artery.¹³ Left gastric artery may give a branch to the liver named left hepatic artery.³ In this study, left gastric artery originated from the hepatogastric trunk. The celiac trunk can give collaterals to the surrounding organs. Among these, the most frequently seen is left phrenic artery and right (40%).^{3,14} Cavdar et al¹⁶ reported that right-inferior phrenic artery and right gastric artery originated from the celiac trunk. Some researchers reported that celiac trunk was 4-5 cm in length (normally 1-5 cm), and the inferior phrenic artery originated from this root.¹⁵ However, in this study, we determined a branch that supplies the right hemidiaphragm, to originate from the hepatogastric trunk.

In conclusion, insufficient development of one of the primitive metameric intestinal arteries (vitellin arteries) or disorders of anterior anastomosis may cause many variations in the branching mode of

celiac trunk. It is important to know the existence of the variations of hepatogastric trunk (1%) and hepatosplenic trunk (5-6%) for the success of the surgical operations, and radiological investigations of those regions.

Acknowledgment. The authors express their profound gratitude to their medical illustrator, Tuna Ferit Hidayetoglu, for his original artwork.

References

1. Kahraman G, Marur T, Tanyeli E, Yildirim M. Hepato-mesenteric trunk. *Surg Radiol Anat* 2001; 23: 433-435.
2. Nonent M, Larroche P, Forlodou P, Senecail B. Celiac bimesenteric trunk: anatomic and radiologic description-case report. *Radiology* 2001; 220: 489-491.
3. Vandamme JPJ, Bonte J. The branches of the celiac trunk. *Acta Anat* 1985; 122: 110-114.
4. Haller A. Icones anatomicae in quibus aliquae partes corporis humani delineatae proponuntur et arteriarum potissimum historia continetur. Vandenhoek: Gottingen; 1756.
5. Basar R, Onderoglu S, Cumhuri T, Yuksel M, Olcer T. Agenesis of the celiac trunk: an angiographic case. *Acta Anatomica Nipponica* 1995; 70: 180-182.
6. Cavdar S, Gurbuz J, Zeybek A, Sehirli U, Abik L, Ozdogmus O. A variation of coeliac trunk. *Kaibogaku Zasshi* 1998; 73: 505-508.
7. Weiglein AH. Variations and topography of the arteries in the lesser omentum in humans. *Clin Anat* 1996; 9: 143-150.
8. Caty L, Deneve E, Fontaina C, Guillem P. Concurrent aberrant right gastric vein directly draining into the liver and variations of the hepatic artery. *Surg Radiol Anat* 2004; 26: 70-73.
9. Oran I, Yesildag A, Memis A. Aortic origin of right hepatic artery and superior mesenteric origin of splenic artery: two rare variations demonstrated angiographically. *Surg Radiol Anat* 2001; 23: 349-352.
10. Descomps P. Le tronc coeliaque. Paris: Steinheil; 1910.
11. Nagino M, Hayakawa N, Kitagawa S, Dohke M, Nimura Y. Right anterior hepatic artery arising from the superior mesenteric artery: a case report. *Hepatogastroenterology* 1993; 40: 407-409.
12. Paduraru D. Hepatic artery variants originating from the superior mesenteric artery-the surgical implications. *Rev Med Chir Soc Med Nat Iasi* 1997; 101: 205-208.
13. Yildirim M, Ozan H, Kutoglu T. Left gastric artery originating directly from the aorta. *Surg Radiol Anat* 1998; 20: 303-305.
14. Rosenbusch G, Van Douveren W, Penn W, de Vries P, Kuypers P. Reno-coeliac steal phenomenon: the inferior phrenic and suprarenal arteries as collaterals for the coeliac trunk. *Rofo* 1975; 122: 218-224.
15. Yuksel M, Yalin A, Weinfeld AB. Concurrent anomalies of the abdominal arteries: an extremely long coeliac trunk, an inferior phrenic trunk, and an aberrant right hepatic artery. *Kaibogaku Zasshi* 1998; 73: 497-503.