Case Report

Recurrent maturing perineal lipoblastoma

Hashem M. Al-Momani, *MSc, FRCS.*

ABSTRACT

Lipoblastoma is a rare benign neoplasm of fetal adipose tissue that we see mostly in infants and young children less than 3 years of age. Most lipoblastomas occur on the extremities, trunk, head and neck, and various other organs have been described. We report a case of a recurrent perineal lipoblastoma in a 2.5-year-old boy, which showed maturation of the lipoblasts as compared to the primary tumor.

Saudi Med J 2005; Vol. 26 (11): 1815-1817

Lipoblastomas are rare mesenchymal neoplasms of fetal adipose tissue, confined almost exclusively to infants and young children. They present either as localized well-circumscribed masses referred to as lipoblastoma; or as diffuse multicentric masses with a tendency for local infiltration referred to as lipoblastomatosis. Although they have the capability of growing rapidly and causing local recurrence, the treatment is excision of the tumor without mutilation of vital surrounding structures. There are no reports of distant metastasis. Most lipoblastomas occur on the extremities, trunk, head, and neck, and various other organs have been described; the perineum is very rare with only 2 cases reported in the literature. In this report, we present a rare case of perineal lipoblastoma, which showed cellular maturation with time.

Case Report. A 2.5-year-old boy was referred to us for a perineal swelling, which was first noticed and excised at the age of one. The histopathology then was consistent with lipoblastoma (**Figure 1**); the swelling recurred and increased in size progressively to a size of 8 × 6 cm. It was soft in consistency with the previous scar seen to the left of the midline (**Figure 2**); otherwise, the patient was completely healthy with no sphincter problem for both urinary and stool. A CT-scan showed a mass encroaching on the anorectal canal more to the left side, and its density was suggestive of lipoma. The mass was well encapsulated and excised completely through an anterior sagittal incision; the mass was attached to the external anal sphincter posteriorly but not infiltrating it; and close to the urethra anteriorly. Microscopically, the histology as compared to the previous slides, showed maturation of the lipoblastoma (**Figure 3**). The patient recovered uneventfully postoperatively. He was seen 6 months later free of recurrence, with a nicely healed scar and with intact anal and urinary sphincteric control.

Discussion. Lipoblastoma is a rare tumor of infancy and early childhood. It was first described by Jaffe in 1926;[1] and since then many cases were reported; Chung and Enzinger, in 1973, suggested the term benign lipoblastoma for the circumscribed type, and the term benign lipoblastomatosis for the diffuse multicentric type of this neoplasm.[2] Lipoblastomas occur mainly in the extremities, other less common sites include the trunk, neck,

From the Department of Pediatrc Surgery, Jordan University Hospital, Amman, *Jordan.*

Received 30th April 2005. Accepted for publication in final form 17th July 2005.

Address correspondence and reprint request to: Dr. Hashem M. Al-Momani, Assistant Professor, Consultant Pediatric Surgeon, Jordan University Hospital, PO Box 13764, Amman 11942, *Jordan.* Tel. +962 65353444 Ext. 2483. Fax. +962 65353388. E-mail: hashemmomani@yahoo.com

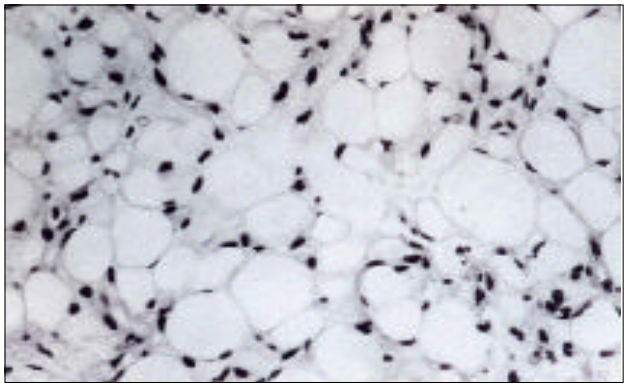

Figure 1

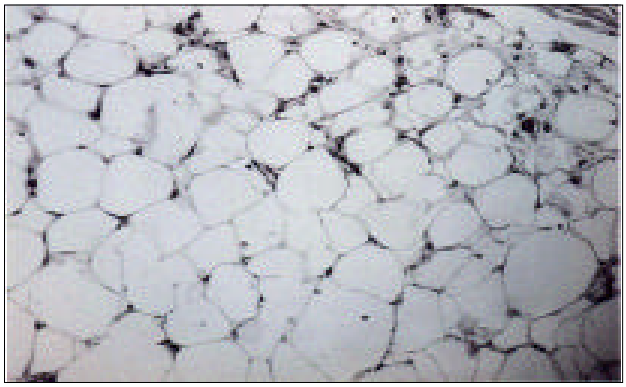

Figure 3

Figure 2

Figure 1 - The previous histopathology 1.5 year earlier; lipoblasts of variable sizes and forms are the main components in a myxoid background (Hematoxylin & eosin stain).

Figure 2 - The perineal mass extending from the anal verge to the scrotum.

Figure 3 - Maturing lipoblastoma, predominant mature adipocytes with few residual lipoblasts in a focal myxoid background (Hematoxylin & eosin stain).

retroperitoneum and the chest;[3-7] whereas the perineum is very rare with only 2 cases previously reported in the literature.[8,9]

In the present case, the patient had a perineal lipoblastoma without any other abnormality especially in the external genitalia; as compared to the other 2 cases of perineal lipoblastoma reported in the literature; describing a bifid scrotum[8] and genital ambiguity.[9] Complete surgical excision; but not radical cancer-type surgery, is the treatment of choice as these tumors are benign and with no reports of metastasis,[4,10] and radical surgery might be mutilating in children. The prognosis in these tumors is excellent, despite their potential for local recurrence. One case reports spontaneous resolution of the tumor.[8]

The ultimate diagnosis depends on the histological examination of the excised tumor. We found good correlation between the histological and cytological findings in the fine needle aspiration material, but a lipoblastoma diagnosis must be established only after careful consideration of all available clinical and radiological data to be differentiated from lipoma with regressive changes and myxoid liposarcoma.[11-14] These tumors have a high tendency for local recurrence of 14-33% as reported in the literature,[1] especially in deeply seated and infiltrative types of lipoblastomatosis, where total excision without destroying major structures is difficult. In the present case the patient was free from recurrence for 6 months, but he requires longer follow up as there are reports of tumor recurrence in 2 cases 6 and 8 years postoperatively.[7]

The histopathology of recurrent tumor shows a continuous maturation into a mature lipoma,[1,2] as occurred in this case; and we can treat the recurrence by excision.

An important clinical issue is to differentiate lipoblastoma and lipoblastomatosis from liposarcoma, especially its myxoid variant. Liposarcoma is extremely rare in patients under 10 years.[7] Helpful clues are the lack of lobulation, variable growth pattern, and increased nuclear atypia in liposarcoma. Furthermore, these tumors mature into a lipoma if followed up for a long period,[5] this fact is also supported by the continuous maturation of the lipoblasts into adipocytes seen on

successive histopathologic studies on recurrences of the tumors.[3,4]

References

1. Jaffe RH. Recurrent lipomatous tumors of the groin. ***Arch Pathol Lab Med*** 1926; 1: 381-387.
2. Chung EB, Enzinger FM. Benign lipoblastomatosis. An analysis of 35 cases. ***Cancer*** 1973; 32: 482-492.
3. Chun YS, Kim WK, Park KW, Lee SC, Jung SE. Lipoblastoma. ***J Pediatr Surg*** 2001; 36: 905-907.
4. Harrer J, Hammon G, Wagner T, Bolkenius M. Lipoblastoma and Lipoblastomatosis: A Report of Two Cases and Review of the Literature. ***Eur J Pediatr Surg*** 2001; 11: 342-349.
5. Mognato G, Cecchetto G, Carli M, Talenti E, d'Amore ES, Pederzini F, et al. Is surgical treatment of lipoblastoma always necessary? ***J Pediatr Surg*** 2000; 35: 1511-1513.
6. Erkmen Gülhana S, Adams PY, Sarıcaa EA, Turuta H, Agackıranb Y. Chest wall lipoblastoma in a seven-month-old girl: A case report. ***J Pediatr Surg*** 2004; 39: 1414-1417.
7. Mentzel T, Calonje E, Fletcher CD. Lipoblastoma and lipoblastomatosis: a clinicopathological study of 14 cases. ***Histopathology*** 1993; 23: 527-533.
8. Ito M, Hashizume K, Kanamori Y. New phenotype of accessory scrotum with perineal lipoblastoma: Coexistence of midperineal and lateral accessory scrotums. ***Int J Urol*** 2004; 11: 125-127.
9. Tsai H, Whitney K, Kogan SJ. Perineal lipoblastoma in a neonate. ***J Urol*** 1997; 158: 2272-2273.
10. Stringel G, Shandling B, Mancer K, Ein SH. Lipoblastoma in infants and children. ***J Pediatr Surg*** 1982; 17: 277-280.
11. Walaas L, Kindblom LG. Lipomatous tumors: a correlative cytologic and histologic study of 27 tumors examined by fine needle aspiration cytology. ***Hum Pathol*** 1985; 16: 6-18.
12. Leon ME, Deschler D, Wu SS, Galindo LM. Fine needle aspiration diagnosis of lipoblastoma of the parotid region. A case report. ***Acta Cytol*** 2002; 46: 395-404.
13. Talwar MB, Misra K, Marya SK, Dev G. Fine needle aspiration cytology of a lipoblastoma. ***Acta Cytol*** 1990; 34: 855-857.
14. Lopez-Ferrer P, Jimenez-Heffernan JA, Yebenes L, Vicandi B, Viguer JM. Fine-needle aspiration cytology of lipoblastoma: a report of two cases. ***Diagn Cytopathol*** 2005; 32: 32-34.