

Immunohistochemical evaluation of periprosthetic membrane from loose cemented and uncemented total hip arthroplasty

Bulent Atilla, MD, Pergin Atilla, MD, PhD, Ahmet M. Tokgözoğlu, MD, Ayşe N. Çakar, PhD, Ahmet M. Alpaslan, MD.

ABSTRACT

Objective: Evaluate the cellular mechanisms responsible for the aseptic loosening of total hip replacements.

Methods: Twenty periprosthetic membranes were collected during revision procedures at the Department of Orthopedics, Hacettepe University, Ankara, Turkey, during 1998 to 1999. Arthroplasties with polyethylene components and without polyethylene components were examined under light microscopy and immunohistochemically using the indirect immunoperoxidase technique into 2 different groups.

Results: Immunohistochemical analysis with monoclonal antibodies reactive to certain cell surface antigens (CD45, CD44, CD98, CD31, CD26, CD71) revealed different morphological characteristics regarding the adjacent fibrosis, leukocyte activation, and immunologic response.

Conclusion: These findings suggested the role of different cellular mechanisms in each group.

Saudi Med J 2005; Vol. 26 (3): 429-433

The tissue adjacent to the total hip prostheses (periprosthetic membrane) consists of synovial tissue, variably organized and variably vascularized fibrous tissue, lymphocytes, and foreign-body inflammatory cells (macrophages and giant cells).^{1,7} Motion in intended (hip articulation) and unintended surfaces (prosthesis-bone interface), generate small particles due to wear. Those particles elicit a cascade of responses at the cellular and tissue levels. The cell whose function is central to the biological reaction to prosthetic wear particles appears to be the macrophage.⁷ When particles within a certain size-range are phagocytized, the macrophages enter into an activated state of metabolism, releasing substances that can result in periprosthetic bone

resorption and eventual failure of the prosthesis.^{5,7} There is an ongoing controversy to explain the cellular reactions around cemented total hip replacements which lead to implant loosening in the long term. The cellular mechanisms responsible for the loosening have not been completely understood yet.^{1,4} Recently, several researchers have focused on immunopathological and molecular mechanisms associated with periprosthetic tissues.^{2,6,7} Understanding the exact cellular mechanisms hopefully will provide therapy with certain drugs (bisphosphonates), to reduce the resorptive changes by suppressing the cellular response. This therapeutic strategy may improve the results and longevity of primary total hip arthroplasties. The

From the Department of Orthopedics and Traumatology (Atilla B., Tokgozolu, Alpaslan) and the Department of Histology and Embryology (Atilla P., Çakar), Faculty of Medicine, Hacettepe University, Sımanpazarı, Ankara, Turkey.

Received 21st September 2004. Accepted for publication in final form 12th December 2004.

Address correspondence and reprint request to: Dr. Bulent Atilla, Department of Orthopedics and Traumatology, Faculty of Medicine, Hacettepe University, Sımanpazarı 06100, Ankara, Turkey. Fax: +90 (312) 3100161. E-mail: b-atilla@hacettepe.edu.tr

purpose of this study was to characterize the cell types (using immunohistochemistry) of tissues surrounding loose hip prosthesis and to obtain better understanding of the biological mechanisms connected with loosening.

Methods. We examined clinically and radiographically 20 patients who had undergone total hip revision surgery. According to the radiologic criteria of Harris and Mc Gann, only the arthroplasties classified as definitely loose were included in the study and 2 groups were identified: 1) polyethylene positive hip arthroplasties (11 hips), 2) polyethylene negative hemi-arthroplasties (9 hips).

Harris and Mc Gann⁹ have defined 3 categories to determine loosening of primary components: definite (radiographic evidence of migration of the component or the cement), probable (evidence of a complete radiolucent zone at the bone-cement interface on one radiograph or more), and possible (a radiolucent zone at the cement-bone interface of more than 49% but <100% on one radiograph or more).⁹ All the hip arthroplasties in this series were classified as definitely loose with marked migration of the components and periprosthetic bone loss. At surgery, a specimen was harvested from the bone cement interface and it is divided into 2 pieces. One of them was processed for light microscopy staining while the other half was immediately frozen in liquid nitrogen. From the frozen specimen, cryostat sections of 6µm thick were taken and immunostained by indirect immunoperoxidase technique. A number of monoclonal antibodies reactive to certain cell surface antigens defined as CDs including: CD45 (leukocyte common antigen),

CD44 (Hermes antigen), CD98 (4F2 antigen), CD31 (platelet endothelial cell adhesion molecule [PECAM-1]), CD26 (ADA-binding protein), CD71 (transferrin receptor) and ki67 are used to distinguish certain cell types, leukocytes, and distribution of the vasculature. Ten percent of the tissue samples for light microscopic examination were fixed into formaldehyde. After routine tissue, processing the sections were stained with hematoxylin-eosin and trichrome and examined under light microscope (Table1).

Results. The membrane formed in Group I was mainly consisted of a dense vascularized fibrous connective tissue. The collagen fibers were arranged parallel to each other and to the surface similar to the reparative connective tissue. In some regions degraded polyethylene particles surrounded by a denser connective tissue and some with histiocytes (Figure 1). In polyethylene (-) group (Group II), the structure of the membrane was different. A synovial membrane-like lining covered the prosthetic surface. The tissue was highly cellular and vascularized. The collagen fibers were not arranged in a certain direction.

In Group I, CD45 (+) leukocytes were scattered singly close to the surfaces as a layer but they were arranged in clusters in deeper regions of the membrane. Some of these clusters were arranged around the capillaries indicating migration of leukocytes into the tissue.

In Group II, CD45 (+) leukocytes were scattered singly and almost evenly at the surfaces in a layer-like distribution. Leukocytes formed large clusters in some regions of the bony surface. In the main bulk of the membrane, the leukocytes were not

Table 1 - Monoclonal antibodies used in the study.

Monoclonal antibodies	Working dilutions	Isotype	Specificity	Source ⁹
7E-12	1/100	IgG1	CD45	Taskov
TA-9B1	1/100	IgG2b	CD44	Kikuchi
J1-G3B	1/100	IgG1	CD98	Skubitz
TP1/15	1/100	IgG2	CD31	Sachez-Madrid
M-A261	1/100	IgG1	CD26	Rieber
LS65-3	1/100	IgG1	CD71	Sun
MIB-2	1/100	IgG1	Ki67	Gerdes

⁹The names of the investigators who introduced these monoclonal antibodies were obtained from the Fifth Leukocyte Typing Workshop¹¹ (Boston-1993) and Sixth Leukocyte Typing Workshop¹² (Kobe-1996).

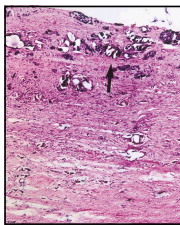


Figure 1 - Prosthetic surface of Group I showing degraded polyethylene particles (arrow) and parallel arranged collagen fibers within fibrous vascularized connective tissue (hematoxylin-eosin x4).




Figure 2 - Aggregation of CD45 (+) cells mainly around blood vessels on the bone surface (B) of a patient from Group II. (Hematoxylin counter-stained, original magnification x10).




Figure 3 - The CD44 expression in Group I. CD44 is mainly expressed around the polyethylene particles (P). (Hematoxylin counter-stained, original magnification x10).

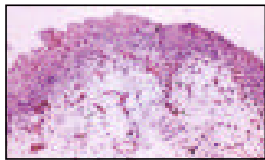


Figure 4 - A section from prosthetic surface of Group II. CD31 expression shows that the membrane tissue is highly vascular (arrow). (Hematoxylin counter-stained, original magnification x10).

so numerous compared to the surfaces and Group I (Figure 2). CD44 is a hyaluronate receptor. Its expression is informed in sites of inflammation and leukocyte aggregation. In Group I, CD44 was strongly expressed around the degraded polyethylene particles in cells and fibers (Figure 3). It may be related to foreign body reaction. CD98 in Group I was mainly observed on cells around the degraded polyethylene particles in the membrane. Some of these particles were surrounded by histiocytes in hematoxylin-eosin stained sections. On the other hand, CD98 expression was observed in cell clusters scattered in the deeper regions of the tissue in Group II. CD31 which is expressed on the endothelial cells is used to show the tissue distribution of the blood vessels. In both groups, the membrane tissue is highly vascular. The blood vessels were present at every level (Figure 4). CD26 is expressed on some large cells, which may be macrophages and multinucleated giant cells. CD71 and ki67 were expressed by the cells surrounding the degraded particles in Group I and on the bone surface in cells forming small aggregates in group II.

Discussion. In chronic local implant reactions, the cellular response consists of monocyte/macrophages, fibroblasts, and endothelial cells.^{1,3,5} The monocyte/macrophage dominant area is showed well-vascularized granulomatous structure and the fibroblast dominant area showed dense collagenous connective tissue. In previous studies of humans who had a loose total hip replacement, the interface tissue was found to be similar to synovial tissue.^{2,3,4} Similar structures were also reported in rabbits and rats.⁵ In our study, an almost similar structure was observed in Group II. The surface of the periprosthetic membrane adjacent to the cement was lined by a synovial-like tissue. The rest of the membrane was highly cellular and vascular indicating an immunological response. In Group I, the histological structure showed the difference; the synovial-like tissue was absent. A thin layer of a cellular material lined the surface adjacent to cement only. The rest of the membrane tissue appeared as a dense, fibrous but well-vascularized connective tissue. The foreign body response was observed around the degraded particles. The immunological aspect of prosthetic loosening is not well known. It was shown in humans that the interface tissue produces prostaglandin E₂.⁴ In a rat model the production of collagenase by the interface cells was also demonstrated. These findings had led to the speculation that the tissue may stimulate bone resorption or the tissue itself may have a bone resorbing capacity. However, the role of various particles released from the loose hip prosthesis (such as polyethylene, methyl methacrylate,

titanium, cobalt-chrome, and surgical steel) on the formation and cellular activity of this tissue is not well documented yet.^{2,6} In our study, distribution of leukocytes is studied by using CD45 antibody. In both groups, CD45(+) cells were distributed almost evenly in layers on the surface adjacent to cement. In deeper layers of Group I, leukocytes were observed to form clusters. Some of these clusters were around blood vessels indicating migration of cells into the tissue. In Group II, clusters were not prominent but single CD45(+) cells were scattered around. Leukocyte clusters were observed also at some regions on the bone surface. The distribution of leukocytes has shown that this tissue is immunologically active. Although the structure of Group I seem to be less cellular and more fibrous, it contains more leukocytes than the highly cellular Group II unexpectedly. In Group I, there were polyethylene particles of varying sizes released from the loose hip prosthesis. As the resolution of light microscopy is limited by the wavelength of visible light (0.4-7 micrometer) objects that are of micrometer size cannot be clearly seen by light microscope. These particles were surrounded by histiocytes showing typical foreign body reaction. Around these region, there was an intense CD44 expression. CD44 is a receptor of hyaluronate. Its expression is informed in sites of inflammation and leukocyte aggregation. Its expression seems to be compatible with an adverse host response. These findings suggested a more aggressive tissue response to the particles released from the prosthesis. In comparison, the fibrous membrane around the prosthesis without a polyethylene interface was looser and more cellular but lymphocytes were less active. CD98, CD71 and ki67 are antigens of activation and proliferation. Their expressions were observed around the particles and in cell clusters in the tissue in Group I. This active proliferation around the particles may be related to the foreign body reaction. In Group II, these antigens were expressed mainly in cell clusters distributed in deeper regions of the membrane and around the bone surface. This was probably a clue of active cell proliferation in the highly cellular membrane unrelated to the cement or metallic particles. CD26 is reported to be expressed by activated T cells, B cells, NK cells and macrophages. In this study, macrophage-like cells and multinucleated giant cells were observed only in Group II. These cells expressed CD26 intensely despite the absence of polyethylene particles. In Group I, however, these cells were not observed. CD26 has different molecular forms in different tissues. These different forms show different immunohistochemical staining properties. It is reported that CD26 has 8 different forms on lymphocytes; but the same gene codes all these different forms. In our samples, 2 types of membranes may be expressing different molecular

forms of CD26 or the presence of a different immunologic process leading to radiographically visible bone loss around the implants may be suggested.

In both groups, the membranes were highly vascular. The distribution of the blood vessels was demonstrated by using CD31, which is specific for the endothelia. It is observed that the distribution did not show any specific localization in both membranes. It appears that all materials used in total hip replacements are capable of inducing an inflammatory foreign-body reaction if the particles are within a certain size-range.^{2,6} Polyethylene particles generated by current designs of total hip arthroplasties are especially prone to cause problems as they are produced in very high numbers and are predominantly of a size within the range of peak biological activity. Polyethylene wear debris and a reaction to particulate metallic wear debris are probably the main initiators of the adverse local host reaction. Despite of intensive research on new materials, polyethylene appears to be a nearly unavoidable material in all total hip replacement designs; it is technically very difficult to find substitutes to polyethylene in the acetabular component gliding layer.^{2,7} However, the reaction to polyethylene particles as shown in this study, requires an increased concern regarding the biocompatibility of the total hip replacements. Clinical observations show that most of the hip prosthesis with or without polyethylene result in loosening. Our results showed a marked difference between the histologic structures, distribution of leukocytes, macrophages, giant cells and other cell types between the membranes formed in 2 groups. There are currently no proven pharmacological measures for the prevention of osteolysis, and often the only treatment option is revision surgery. Several drugs are under investigation to prove their efficacy on blocking osteoclastic bone resorption and to prevent particle-induced osteolysis.¹⁰ Understanding the cellular mechanisms responsible for osteolysis potentially provide benefit greatly from nonoperative treatment alternatives to many patients, particularly those who are poor operative risks.

In conclusion, polyethylene particles appear to be involved with a more aggressive periprosthetic membrane formation characterized by a dense fibrous tissue and lymphocytes that are more active. There is an obvious leukocyte activation and immunologic reaction leading to eventual bone resorption around the prosthesis without a polyethylene interface. These results indicate that there may be some other factors responsible for the loosening or the 2 types of membranes utilize different cellular and molecular mechanisms and further studies are necessary for the clarification of these questions.

References

1. Goldring SR, Schiller AL, Roelke M, Rourke CM, O'Neill DA, Harris WH. The synovial like membrane at the bone-cement interface in loose total hip replacements and its proposed role in bone lysis. *J Bone Joint Surg* 1983; 65-A: 575-584.
2. Kadoya Y, Kobayashi A, Ohashi H. Wear and osteolysis in total hip replacements. *Acta Orthop Scand Suppl* 1998; 69: page number.
3. Goodman SB, Huie P, Song Y, et al. Loosening and osteolysis of cemented joint arthroplasties: A biologic spectrum. *Clin Orthop Rel Res* 1997; 337: 149-163.
4. Santavirta S, Kontinen YT, Bergroth V, et al. Aggressive granulomatous lesions associated with hip arthroplasty. *J Bone Joint Surg* 1990; 72-A: 252-258.
5. Goodman SB, Fornasier VL, Kei J. Quantitative comparison of the histological effects of particulate polymethylmethacrylate versus polyethylene in the rabbit tibia. *Arch Orthop Trauma Surg* 1991; 110: 123-126.
6. Schmalzried TP, Callaghan JJ. Wear in Total Hip and Knee Replacements. Current Concepts Review. *J Bone Joint Surg* 1999; 81: 115-136.
7. Case CP, Langkamer VG, Lock RJ, Perry MJ, Palmer MR, Kemp AJ. Changes in the proportions of peripheral blood lymphocytes in patients with worn implants. *J Bone Joint Surg Br* 2000; 82: 748-754.
8. Jones LC, Frondoza C, Hungerford DS. Immunohistochemical evaluation of interface membranes from failed cemented and uncemented acetabular components. *J Biomed Mater Res* 1999; 48: 889-898.
9. Harris WH, McGann WA. Loosening of the femoral component after use of the medullary-plug cementing technique. Follow-up note with a minimum five-year follow-up. *J Bone Joint Surg Am* 1986; 68: 1064-1046.
10. Millett PJ, Allen MJ, Bostrom MPG. Effects of Alendronate on Particle-Induced Osteolysis in a Rat Model. *J Bone Joint Surg Am* 2002; 84: 236-249.
11. Schlossman SF, Boumsell L, Gilks W, Harlan JM, Kishimoto T, Morimoto C, et al. Leukocyte Typing V. Oxford: Oxford University Press. 1995.
12. Kishimoto T, Kikutani H, Burne A, Goyert SM, Mason DY, Miyasaka M, et al. Leukocyte Typing VI. New York, London: Garland Publishing; 1997.