

Brief Communication

Clinical paradox. *Man versus machine*

Shabih Manzar, MD, FAAP.

In the present era of technological advancement, the clinicians have to rely on investigations in addition to their clinical skills to make an appropriate diagnosis. However, it is still far from practical that machines take over and replace the clinical skills completely. We would like to present a few clinical scenarios illustrating the role of machine and man in making a clinical diagnosis.

Machine versus man. Heart murmurs are not infrequent in the early newborn period. Fortunately, most of the murmurs are due to the closing ductus or non-structural heart problems. However, a murmur could be an early manifestation of congenital heart disease. In that scenario, using echocardiogram (ECHO) may be essential to delineate the exact anatomy of the heart. Even expert clinical cardiologists rely on that. One might try repeated cardiac auscultation, 4 limb blood pressure (4-limb BP) measurements, electrocardiogram (ECG) or chest x-ray (CXR), however, the sensitivity and specificity of these investigations have been questioned.¹⁻⁴ Thus, in a center where ECHO facilities are available readily, the reliance on only clinical examination may be dangerous and time should not be wasted in getting the 4-limb BP, ECG and CXR murmur. A direct ECHO approach seems to be a better alternative.

In this example we saw how technology takes over the clinical skills. Now we will look at the other example where reliance on laboratory parameters

may be deceptive, while clinical expertise reaches the diagnosis.

Man versus machine. Patient 1. A term small for gestational age baby on day 6 of life presented to accident and emergency (A&E) with poor feeding and lethargy. This baby was discharged one day prior from the postnatal ward in healthy condition. The immediate postnatal course was complicated by polycythemia and hyperbilirubinemia treated with partial exchange transfusion and phototherapy. The baby remained stable tolerating ad lib breast feedings and the discharge examination was unremarkable. The antenatal and perinatal history was unremarkable. Mother's serology tests for HIV, syphilis and hepatitis were negative. The high vaginal swab showed normal flora. On presentation to A&E, the baby was noted to be hypoactive and thus, after initial stabilization was immediately transferred to the special care baby unit (SCBU) for further management. In the SCBU, a septic work up was carried out and the baby was started on antibiotics. The white cell count (WBC) was unremarkable (Table 1). Six hours later, the baby threw a convulsion, which was controlled by intravenous phenobarbitone. Microscopy of spinal fluid showed group B streptococcus. The baby was treated with a meningitic dose of penicillin and he responded well. The baby was discharged home after discontinuing the anticonvulsants, and completing the full 21-day course of antibiotics. A follow up in a high-risk neonatal clinic is planned.

Patient 2. A preterm small for gestational age baby who had uneventful postnatal course, on day 14 of life was noted to have frequent desaturations. Examination revealed a temperature of 38.5°C with poor activity. The anterior fontanelle felt full but was

Table 1 - Serial peripheral cell counts in patient 1.

Full blood count	16.7.04 09:00 hr	16.7.04 13:00 hr	16.7.04 15:00 hr*	18.7.04 10:30 hr†	19.7.04 15:00 hr‡
Hemoglobin (g/dl)	22	21	16.2	19.2	17.8
Hematocrit (%)	70	67	49	58	54.5
Platelets (10 ⁹ /L)	178	140	148	195	189
Total white cell count (10 ⁹ /L)	16.4	16.3	11.2	7.5	11.9
Neutrophils (10 ⁹ /L)	11.4	11.8	7.8	3.8	7.5
Lymphocytes (10 ⁹ /L)	3.4	3	2.3	3	3.6
Monocytes (10 ⁹ /L)	1.2	1	0.8	0.4	0.5
Eosinophils (10 ⁹ /L)	0.1	0.2	0.1	0.1	0
Basophils (10 ⁹ /L)	0.1	0.1	0	0	0

*post partial exchange transfusion, †in postnatal ward before discharge, ‡on admission to the neonatal intensive care unit (same specimen grew Group B Streptococcus in blood and same day spinal fluid grew the same organism).

Table 2 - Serial peripheral cell counts in patient 2.

Full blood count	07.7.04*	21.7.04†	30.7.04‡
Hemoglobin (g/dl)	18.8	17.1	13.8
Hematocrit (%)	62	53	43
Platelets (10 ⁹ /L)	195	300	220
Total white cell count (10 ⁹ /L)	11.1	3.4	3.2
Neutrophils (10 ⁹ /L)	4.5	1.8	1.8
Lymphocytes (10 ⁹ /L)	5.3	1.1	1.2
Monocytes (10 ⁹ /L)	1.1	0.2	0.1
Eosinophils (10 ⁹ /L)	0	0.1	0
Basophils (10 ⁹ /L)	0	0	0

*on admission, †routine sampling at 2 weeks of age, clinically the baby was stable, ‡septic episode

soft. The rest of the examination was unremarkable. A septic work was carried out and antibiotics were started. A spinal tap was performed which turned out to be positive for group B streptococcus. The baby was treated with a meningitic dose of Penicillin and he responded well. The WBC was observed to be low but no major changes were noted when compared to previous values (Table 2). The baby remained stable during her stay in the NICU, and was discharged home after completing the 21-day course on antibiotics. A follow up appointment in the high-risk clinic is given and further neuro-developmental assessment is planned.

It is clear from both the cases presented above that reliance on the peripheral WBC, which is the most commonly used laboratory indicator for infection,⁵ could be deceptive. Therefore, WBC alone should not be taken as indicative or exclusive criteria for sepsis or meningitis, and a decision to treat should be based on clinical signs rather than WBC. This statement is further supported by the questionable specificity and sensitivity of WBC.^{6,7}

Received 29th May 2005. Accepted for publication in final form 17th September 2005.

From the Division of Neonatology, John Stroger Jr. Hospital of Cook County, Chicago, Illinois, United States of America. Address correspondence and reprint requests to: Dr. Shabih Manzar, Division of Neonatology, John Stroger Jr. Hospital of Cook County, 1901 W Harrison St, 4th Floor, Room, 4509, Chicago, IL 60612. Tel. +1 (312) 8644010. Fax. +1 (312) 8649943. E-mail: shabihman@hotmail.com

References

- Crossland DS, Furness JC, Abu-Harb M, Sadagopan SN, Wren C. Variability of four limb blood pressure in normal neonates. *Arch Dis Child Fetal Neonatal Ed* 2004; 89: F325-F327.
- Temmerman AM, Mooyaart EL, Taverne PP. The value of the routine chest roentgenogram in the cardiological evaluation of infants and children. A prospective study. *Eur J Pediatr* 1991; 150: 623-626.
- Swenson JM, Fischer DR, Miller SA, Boyle GJ, Etedgui JA, Beerman LB. Are chest radiographs and electrocardiograms still valuable in evaluating new pediatric patients with heart murmurs or chest pain? *Pediatrics* 1997; 99: 1-3.
- Yi MS, Kimball TR, Tsevat J, Mrus JM, Kotagal UR. Evaluation of heart murmurs in children: cost-effectiveness and practical implications. *J Pediatr* 2002; 141: 504-511.
- Madan A, Adams MM, Philip AG. Frequency and timing of symptoms in infants screened for sepsis: effectiveness of a sepsis-screening pathway. *Clin Pediatr* 2003; 42: 11-18.
- Bonsu BK, Chb M, Harper MB. Identifying febrile young infants with bacteremia: is the peripheral blood cell count an accurate screen? *Ann Emerg Med* 2003; 42: 216-225.
- Bonsu BK, Harper MB. Utility of the peripheral blood white blood cell count for identifying sick infants who need lumbar puncture. *Ann Emerg Med* 2003; 41: 206-214.

Prilocaine induced methemoglobinemia

Sahender G. Aygencel, MD, Emine Akinci, MD,
Gul Pamukcu, MD.

Iron contained in hemoglobin is normally in the ferrous (Fe⁺²) form. Oxidation of iron in deoxygenated hemoglobin to the ferric (Fe⁺³) form results in the formation of methemoglobin (MetHb), also known as ferrihemoglobin. Methemoglobin not only is unable to carry oxygen, but also causes a leftward shift in the oxyhemoglobin dissociation curve. This further impairs cellular utilization of oxygen. There are 3 general causes of methemoglobinemia. Both hemoglobinopathies (hemoglobin M) and hereditary enzyme deficiencies (NADH MetHb reductase) are quite rare; most cases are acquired and are due to the exposure to drugs and other agents.¹ Methemoglobinemia is most commonly associated with use of amyl nitrite, nitroglycerin, dapsone, phenacetin, phenytoin, primaquine, sulfonamides, and local anesthetics.^{2,3} Methemoglobinemia is reported frequently as a side effect of benzocaine use, and occasionally with use of lidocaine, tetracaine or prilocaine.^{4,5} We report a case of acquired methemoglobinemia secondary to multiple subcutaneous prilocaine self-injections during epilation therapy of the legs.

A 30-year-old woman was admitted to our emergency department with weakness, dizziness, lightheadedness, and cyanosis 2 hours following epilation of the legs. The past medical history, family history and systems review were noncontributory.

Physical examination revealed a healthy young woman with a blood pressure of 140/80 mm Hg; pulse, 124 beats/minute; temperature, 36.7°C, and respiration, 20/minute. Oxygen saturation measured by pulse oximetry (SpO₂) was 90%. She had acral and perioral cyanosis. The lungs were clear, and heart sounds were normal. The neurologic examination was normal. A 12 lead electrocardiogram and chest x-ray were normal. Complete blood count, electrolytes, and renal function were also normal. Because of the history of a recent epilation procedure and subcutaneous application of local anesthetic, we suspected local anesthetic induced methemoglobinemia, and ordered an arterial blood sample drawn to determine a MetHb level. The result revealed a clinically significant MetHb (20%) level. Later, we learned that prilocaine solution (Citanest®) was used subcutaneously as a local anesthetic for this epilation procedure. Supplemental oxygen therapy was administered with a non-breather mask. The methylene blue treatment or ascorbic acid was not administered due to lack of indication. The cyanosis resolved over 60 minutes. She remained asymptomatic and was discharged with a 1% methemoglobin level after 24 hours observation.

Local anesthetics have been implicated as a cause of methemoglobinemia since 1955; with many reported cases. As with our patient, cases have been reported after application to the pharyngeal, rectal, or vaginal mucosa, and skin. Although benzocaine is the most commonly implicated agent, lidocaine, prilocaine, or tetracaine also has been associated with methemoglobinemia. Prilocaine is an amide local anesthetic, which is derived from toluidine. Orthotoluidine is one of the metabolites of prilocaine and has been found to produce methemoglobinemia. Cyanosis secondary to prilocaine induced toxic methemoglobinemia has been reported by some investigators. The maximum safe dose of prilocaine used with or without epinephrine is 8mg/kg up to maximum of 600 mg as a single injection in a healthy adult.⁴ In our case, the total administered prilocaine dose was 400 mg, and less than the maximum safe dose. Multiple injections and the possibility of systemic absorption during administration may explain the induced toxicity and methemoglobinemia in our case.

The clinical effects of methemoglobinemia are caused by the inability of MetHb to bind oxygen, resulting in a state of functional anemia. Clinical symptoms and signs depend on the level of MetHb. Levels greater than 15% are associated with cyanosis; headache, lethargy, tachycardia, weakness, and

dizziness generally manifest at levels of 20-45%. Dyspnea, acidosis, cardiac dysrhythmias, heart failure, seizures, and coma may occur at levels exceeding 45%. Methemoglobin levels above 70% are associated with a high mortality rate. The diagnosis of methemoglobinemia should be suspected if sudden development of cyanosis occurs after application of oxidizing agents, or the presence of dark brown or chocolate color blood that does not turn red on exposure to air. Methemoglobinemia also should be considered in patients when there is a discrepancy between the pulse oximetry reading and the partial arterial oxygen pressure in the arterial blood gas sample.⁵ For most patients with mild methemoglobinemia, no therapy is necessary other than withdrawal of the offending agent and oxygen administration. In the absence of serious underlying illness, MetHb levels less than 30% usually resolve spontaneously over 15-20 hours without serious consequences. Changes in mental status, ischemic chest pain, and abnormal vital signs should be treated aggressively. The most widely accepted treatment of methemoglobinemia is the administration of methylene blue, 1-2 mg/kg body weight as a 1% solution, infused intravenously over 5 minutes. Improvement should be noted within one hour of methylene blue administration. If cyanosis has not disappeared within one hour of the infusion, a second dose should be given. Methylene blue can be repeated every 4 hours to a maximum total dose of 7 mg/kg. Ascorbic acid can also be used to treat methemoglobinemia, but it works slowly and has no benefit in acute situations. Transfusions, exchange transfusions, and hyperbaric oxygen therapy may be the alternatives for life threatening methemoglobinemia refractory to methylene blue.⁵ In our case, within 60 minutes, the patient showed signs of clinical improvement with oxygen therapy and appeared asymptomatic. Because the degree of methemoglobinemia was less than 30% and the patient's clinical condition was improving quickly, methylene blue was not administered.

In conclusion, local anesthetic drugs are commonly used for numerous procedures performed in or out of the hospital. These agents are also found in several over the counter medications. Although generally safe, in susceptible persons, they may result in methemoglobinemia that is potentially life threatening. The appearance of unexplained cyanosis after use of these compounds should alert the clinician to this possibility.

Received 31st July 2005. Accepted for publication in final form 27th September 2005.

From the Department of Emergency Medicine, Faculty of Medicine, Gazi University, Ankara, Turkey. Address correspondence and reprint requests to: Dr. Sahender G. Aygencel, Department of Emergency Medicine, Faculty of Medicine, Gazi University, Besevler 06510, Ankara, Turkey. Tel. +90 (312) 2025524. Fax. +90 (312) 2230528. E-mail: gencel69@hotmail.com

References

1. Curry S. Methemoglobinemia. *Ann Emerg Med* 1982; 11: 214-221.
2. Coleman MD, Coleman NA. Drug-induced methemoglobinemia. *Drug Saf* 1996; 14: 394-405.
3. Hall AH, Kulig KW, Rumack BH. Drug and chemical induced methemoglobinemia. Clinical features and management. *Toxicology* 1986; 1: 253-260.
4. Scott D, Owen J, Richard J. Methemoglobinemia due to Prilocaine. *Lancet* 1964; 21: 728-734.
5. Wright RO, Lewander WJ, Woolf AD. Methemoglobinemia; etiology, pharmacology and clinical management. *Ann Emerg Med* 1999; 34: 646-656.

Intraligamentary solid-cystic neoplasia with histomorphological features of sclerosing stromal tumor

Zuhal Gucin, MD.

Sex-cord stromal tumors in the ovary and testis include a wide range of tumors consisting of granulosa, Sertoli, theca or Leydig cells and specified fibroblasts that exist in varying proportions.^{1,2} Among these tumors, sclerosing stromal tumor has a specific histological pattern. Pseudo lobular structure composed of cellular and hypocellular areas, edematous and hyalinized collagenous parts, and prominent vasculature are the main histological features.³ Two types of cells are present in these tumors. One is ovoid or spindle shaped and is responsible for the production of collagen. The second one is round shaped and has a vacuolar cytoplasm that contains lipid and is considered as a degenerated lutein cell. Histogenetically, sclerosing stromal tumors are thought to arise from the theca externa, also called perifollicular myoid cells.³ The tumor cells exhibit smooth muscle actin positivity as shown by immunohistochemical studies. Another important feature of these tumors is the expression of alpha-inhibin, which inhibits follicular stimulating hormone, and it is primarily a product of Sertoli and granulosa cells.^{2,4-7} A sclerosing stromal tumor is a rare benign neoplasia of the ovary. More than 80%

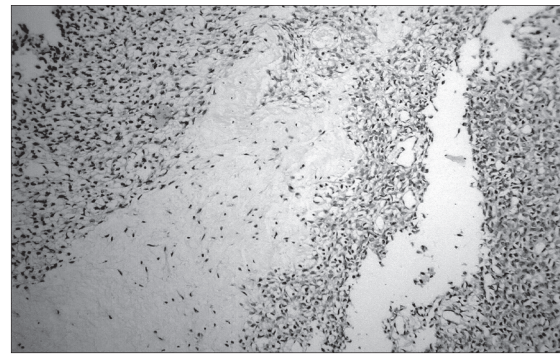


Figure 1 - Pseudo lobular structure composed of cellular and collagenised hypocellular parts (Hematoxylin & eosin x40).

of cases are under 30 years old. The tumor is mostly nonfunctional, and thus, estrogenic and androgenic effects are rarely seen and recurrence has not been reported.³ It should be remembered that ovarian tumors might arise in ectopic gonads and extragonadal structures on rare occasions.³

The presented case is a 70-year-old woman who has been menopausal for 20 years. She complained of pain in her right hypochondrium. An immobile cystic mass, located in right adnexal region was found following gynecological examination. She had an operation for ovarian cyst 10 years ago with no record available. On presentation, she has neither an abnormal hormonal effect nor tumoral markers. The mass was found between the layers of ligamentum latum, without related uterus and adnexa at operation. On gross examination, the material was 8 x 7 cm in diameter, of a cystic nature with serous fluid. The thickness of the wall was 0.2-1.0 cm with smooth inner surface, had gray and white color with yellowish areas, and small cystic spaces were noted in the thickened part of the wall. On histologic sections, mainly cystic and partly solid structures, pseudo lobular in appearance, and a rich hemangiopericytomatous vascular network were seen. No glandular, tubular or trabecular structures or lining epithelial layer of the cystic spaces were seen. Interlobular areas were edematous or richly collagenised (**Figure 1**). Histochemically lipid stain was positive whereas periodic acid-Schiff - Alcian blue stains were negative. Reticulin stain was positive all around the individual cells. Immunohistochemical studies revealed the positivity for vimentin, smooth muscle actin, progesterone, and alpha-inhibin; but negativity for keratins, desmin, sarcomeric actin, LCA, CD34, CD10 and estrogen antibodies. The results confirmed the sex cord stromal origin of the tumor, and the morphologic appearance was consistent with sclerosing stromal tumor of the ovary.

The presented case is the first due to its extragonadal localization of the sclerosing stromal tumor. If the former ovarian cyst of the patient in the past was the same type, the new one should be accepted as the first case of recurrence for sclerosing stromal tumor.

Received 19th February 2005. Accepted for publication in final form 3rd October 2005.

From the Pathology Department, Ministry of Health, Istanbul Education and Research Hospital, Istanbul, Turkey. Address correspondence and reprint requests to: Dr. Zuhal Guçin, Cinar 03-0 I B 16/20, Bahcesehir 34500, Istanbul, Turkey. Tel. +90 (212) 669 3071. E-mail: zgucin@yahoo.com

References

1. Gordon MD, Corless C, Renshaw AA, Beckstead J. CD99, keratin and vimentin staining of sex cord stromal tumours, normal ovary and testes. *Mod Pathol* 1998; 11: 769-773.
2. Steward CJR, Kennedy A. Diagnostic value of inhibin immunoreactivity in ovarian gonadal tumours and their histological mimics. *Histopathology* 1997; 31: 67-74.
3. Andrade LA, Gentilli ALC, Polli G. Sclerosing stromal tumours in an accessory ovary. *Gynaecol Oncol* 2001; 81: 318-319.
4. Mathias GX, Pons C, Prat J. Mullerian inhibiting substance, alpha-inhibin, and CD99 expression in sex cord stromal tumours and endometrioid ovarian carcinomas resembling sex-cord stromal tumours. *Human Pathol* 1998; 29: 840-845.
5. Costa MJ, Ames PF, Walls J, Roth LM. Inhibin immunohistochemistry applied to ovarian neoplasms: A novel effective, diagnostic tool. *Human Pathol* 1997; 28: 1247-1254.
6. Baker RJ, Hildebrandt RH, Rouse RV, Hendrickson MR, Longacre TA. Inhibin and CD 99 (MIC2) expression in uterine stromal neoplasms with sex-cord like elements. *Human Pathol* 1999; 30: 671-679.
7. Choi YL, Kim HS, Ahn G. Immunoreactivity of inhibin - alpha subunit, inhibin/activin BA subunit and CD99 in ovarian tumours. *Arch Pathol Lab Med* 2000; 124: 563-569.

The factors of arteriovenous fistula failure in hemodialysis patient

Abdolhassan Talaiezhadeh, MD, FISS,
Faramarz Paziar, MD.

A large group of patients who suffer from chronic renal failure may require hemodialysis for filtration of blood from harmful agents such as creatinine. Vascular access through an arteriovenous fistula (AVF) is appropriate when frequent access to the vascular system with a high-flow system and tube

ability to withstand needle puncture are required. The most frequently used fistula, and the standard by which all other fistulas are compared, is the Brescia-Cimino fistula. Both physicians and patients encounter frequent problems in AVF implantation. This tiny procedure requires well-experienced surgeons, and ensuring of adequate collateral flow from the ulnar artery by performing Allen test before surgery in order to minimize the problem of hand ischemia. In addition, evaluating superficial veins and distal arteries must be achieved for selecting the best site for the fistula. Although, the 2 main reasons for failure of AVF are the surgeon's inexperience and improper selected vessels. In addition, other factors that led to primary failure are falling blood fistula pressure, post operation hemorrhage, and vascular injury during operation, due to severe atherosclerosis especially in diabetic patients. With regard to the importance of AVF implantation in patients with end-stage renal disease (ESRD), in this study we analyze the patency rate of fistula and etiology of failure.

In this prospective randomized study, we analyzed 75 patients who attended the surgery clinic of Imam-Khomeini General Hospital from January 1996 to December 2000. Initially, individual data, age, gender, and history of diabetes mellitus (DM), vascular disease such as atherosclerosis, vasculitis, and hypertension (HTN) were obtained. After recording blood pressure, and performing Allen test, the best site for fistula creation was chosen. During operation, vascular diameter, intra-vascular thrombosis, arterial wall atherosclerosis and opening of arterial inflow, and venous out flow access were evaluated. If there was no contraindication, an end to side AVF was created. If any patient did not meet the mentioned criteria, they were excluded from the study. All procedures were achieved by our team. After ensuring the patency of fistula and obtaining the thrill, the patient was discharged. The patient was evaluated on the first day, the first week and after the third week to ensure the fistula patency and performing hemodialysis. Fistula complications, such as subcutaneous hematoma, thrombosis, and blood pressure during hemodialysis were recorded.

Seventy-five patients were enlisted for the study. Five patients were excluded for the reasons mentioned previously. One hundred fistulas were created in the remaining of patients, consisting of 42 men (60%) and 28 women (40%) and their age ranged from 18-79 years old. In 43 patients (62%), one fistula creation was appropriate, while a second operation was required in 24 patients (34%), and a third fistula was created in the remaining 3 patients (4%). The reason for repeated fistula creation was failure of the former

fistula. In 53 cases (53%) the fistula was created in the left snuff box, 26 case in the distal left forearm, 17 cases in the antecubital vein to brachial artery fistula of left arm, and the ulnar artery to the basilic vein, and in the remaining 4 cases, the right wrist. The minimum patency duration was 20 months in 47 cases. While in 23 cases, a mean of 7.5 months was reported, and in 30 cases, an early failure occurred during the first 2-3 weeks after insertion before hemodialysis. In 22 patients (73%) of the latest group, a sharp fall in blood pressure (<100/80) was reported especially during dialysis through a subclavian catheter. Nine patients (30%) underwent thrombectomy and venous dilatation of the superficial veins due to small size and inappropriate vein selected for fistula creation. Four out of 9 patients suffered from intermittent blood pressure changes. Twenty-three cases were diabetic and suffered from arteriosclerosis. Hypotension was the most common etiology of the AVF failure, as we had a report of 93% of hypotension at the time of AVF failure. In the early failure group, 20 cases (66%) were in the left wrist, 7 cases (23%) in the left forearm, 2 cases (7%) in the left arm, and one case (4%) in the right forearm. There was no significant difference between the mentioned groups, in the early failure rate when compared with the total number of AVFs on specific site; except significantly lower rate in the arm fistulas. In 70%, the fistulas were patent and functional for hemodialysis. Forty-seven out of 70 cases had active fistula by the end of the study, while in 23 cases it was active for a period of 7.5 months. In this group, 14 cases were in the left wrist. Seven cases in the left forearm and 2 cases in the left arm. In 16 out of 23 cases, hypotension was the reason for AVF failure, 3 of which were diabetic, in the remaining 7 cases, hemorrhage, and hematoma after frequent punctures and ensuing venous thrombosis were the etiologies of AVF failure.

The upper limbs are the gold standard for frequent dialysis in chronic renal failure cases, and distal fistulas are more common as this creates more superficial venous and less complication in comparison with proximal fistulas when greater and major arteries are used.¹ In addition, in cases of impairment, disabling aneurysm formation and bleeding in proximal types of AVF if not required to repair the fistula, ischemia risks of distal limb due to steal syndrome increase. Consequently, despite the failure risk of distal type fistulas, as illustrated in this study, implantation of distal fistulas in the upper limbs is our first choice, except in cases in which it could not be performed due to distal thrombosed vessels.² Although, some research claims that brachial fistula is a good choice if the radiocephalic venous is not accessible, in the present study, we performed brachial fistula in just 7%, and 30% of all operations led to primary failure.

However, by the use of microscopic vascular surgery and new technologies, less complications and higher success rates, an ever-higher probability of fistula repair will ensue. In AVF failure cases with falling blood pressure, diabetes with atherosclerosis were reported in 73% and 23%. Previous studies reported a 55% success rate. The main failure reasons were positive history of cerebrovascular access and ischemic heart disease, in addition to greater age and dependency on dialysis during surgery.³

High dose administration of heparin using bigger venous and mean blood pressure of 8 mm Hg or higher, together with the appropriate technique and ideal operating systems were major etiologies for the success rate of up to 84%.⁴ Although, a duplex ultrasonographic study is suggested for advanced evaluations of diabetic old and peripheral vascular disease cases,⁵ in an ideal situation, the success rate exceeds 74% in children who require dialysis and fistulas implanted in the arm (7% of all cases in our study, had the lowest rate of primary failure in comparison with radiocephalic and snuff box fistulas, ($p<0.05$). In our study, a major portion of AVF failure (primary and secondary) was a fall in blood pressure (70% and 73%). In addition, any factor that led to blood pressure changes increased this probability ($p=0.006$).

Consequently, the most important factor along with good vascular selection is stable blood pressure (100/80 mm Hg). Raised blood pressure, in addition to other complications of HTN, increases the risk of bleeding in the fistula site and AVF failure. However, hypotension can lead to AVF failure due to thrombosis. Finally, it is suggested that in patients who require AVF implantation for dialysis, blood pressure control should be performed by administration of antihypertensive agents and low salt diet. In addition, during dialysis monitoring of blood pressure and preventing hypotension (for example eating salty nuts) should be performed.

Received 25th June 2005. Accepted for publication in final form 26th September 2005.

From the Department of Surgery, Imam Khomeini Hospital Medical School, Ahwaz Jondishapour University of Medical Sciences Ahwaz, Iran. Address correspondence and reprint requests to: Dr. Abdolhassan Talaiezhadeh, Imam Khomeini Hospital Medical School, Ahwaz Jondishapour University of Medical Sciences Ahwaz, Iran. Tel. +98 (611) 3323920. Fax. +98 (611) 2225763. E-mail: ahtalaiezhadeh@ajums.ac.ir/ Talaiezhadeh@yahoo.com

References

1. Fitzgerald JT, Schazer A, Chin AI, MC Vicar JP, Perez RV, Troppmann C. Outcomes of upper arm arteriovenous fistula for maintenance hemodialysis access. *Arch Surg* 2004; 139: 201-208.

2. Kim YO, Yang CW, Yoon SA, Chun KA, Kim NI, Park JS, et al. Access blood flow as a predictor of early failure of native arteriovenous fistula in hemodialysis patients. *Am J Nephrol* 2001; 21: 221-225.
3. Sheth RD, Brandt ML, Brewer ED, Nuchtern JG, Kale AS, Goldstein SL. Permanent hemodialysis vascular access survival in children and adolescents with end-stage renal disease. *Kidney Int* 2002; 62: 1864-1869.
4. Malovrh M. Approach to patients with end-stage renal disease who need an arteriovenous fistula. *Nephrol Dial Transplant* 2003; 18 suppl 5: 50-52.
5. Feldman HI, Joffe M, Rosas SE, Burns JE, Knauss J, Brayman K. Predictors of successful arteriovenous fistula maturation. *AM J Kidney Dis* 2003; 42: 1000-1012.

Dark-lumen magnetic resonance colonography

*Mathias Goyen, MD, PhD, Waleed Ajaj, MD,
Thomas C. Lauenstein, MD.*

With an incidence of 130,000 per year and 50,000 cases of death in the United States alone, colorectal cancer (CRC) has matured into the second most common cancer in both sexes in the Western world.¹ Up to 90% of CRC-cases originate from benign adenomas. Hence, the incidence of CRC could be considerably reduced by more than 80% if polyps were detected and eliminated before their malignant transformation. Despite the availability of several screening options, CRC remains a considerable cause of morbidity and mortality. The main reason is related to poor patient acceptance in current screening programs. Therefore, a real successful strategy has to overcome poor patient acceptance in the future by making the examinations comfortable and noninvasive. Magnetic resonance colonography (MRC) has the potential to be implemented as such a screening tool. Due to its noninvasive character, it is well accepted by patients. Moreover, it is highly accurate for the detection of colorectal polyps.

Similar to contrast-enhanced 3D MR angiography, MRC is based on the principles of ultrafast, T1-weighted 3D gradient-echo acquisitions collected within the confines of a single breath-hold. This requires the use of an MR system equipped with high-performance gradients. Initial approaches of MRC were based on the rectal application of water spiked with paramagnetic contrast. On T1-weighted data sets, the paramagnetic contrast renders the colonic lumen bright. Hence, polypoid colonic masses appear as dark filling defects within the bright colonic lumen. This

appearance may make the differentiation of polyps from residual fecal material or small pockets of air difficult. Furthermore, the technique requires data acquisition in prone and supine patient positions to compensate for the presence of residual air. A recently introduced method of MRC is based on a different contrast mechanism and is referred as dark-lumen MRC.² It has turned out to be more accurate and less time consuming than bright-lumen techniques.

Before the examination, the patient has to be screened for contraindications to MR imaging (MRI) such as severe claustrophobia or the presence of metallic implants or cardiac pacemakers. The presence of hip prostheses, which normally is not regarded a contraindication to MRI, impedes complete analysis of the rectum and sigmoid colon. Therefore, these patients should not be examined. As residual stool impedes appropriate evaluation of the large bowel, patients need to undergo bowel preparation in a manner similar to that required for conventional colonoscopy. To limit patient discomfort related to extended fasting, MRC should be performed in the early morning. Patients should be examined on a 1.5 Tesla or 3 Tesla MR scanner equipped with strong gradient systems. Thus, data acquisition is to be confined to one breath-hold. The examination itself is performed in patients in the prone or supine position. A combination of 2 surface coils should be used for signal reception to permit coverage of the entire colon. To minimize motion artefacts due to bowel peristalsis, a spasmolytic agent is administered intravenously (for example, scopolamine or glucagon). A contrast enema consisting of 2-2.5 L of warm tap water is rectally administered using hydrostatic pressure (1-1.5-m water column). The filling process of the colon can be monitored by using a T2-weighted non-slice select acquisition that collects one image every 3 seconds (for example, TrueFISP; repetition time/echo time, 2.4/1.2 ms; flip angle 60 degrees). Beyond assuring adequate filling, this 2-dimensional overview allows recognition of high-grade stenoses and colonic spasm. Once the water enema has reached the cecum and a sufficient distension is assured, a 3D gradient-echo data set is collected (repetition time/echo time, 3.1/1.1 ms; flip angle, 12 degrees; field of view, 450 x 450 mm; matrix, 168 x 256; and effective slice thickness, 4 mm). Subsequently, paramagnetic contrast is administered intravenously at a dosage of 0.2 mmol/kg body weight and a flow rate of 3.5 mL/s. A second 3D acquisition is acquired in a portal-venous contrast

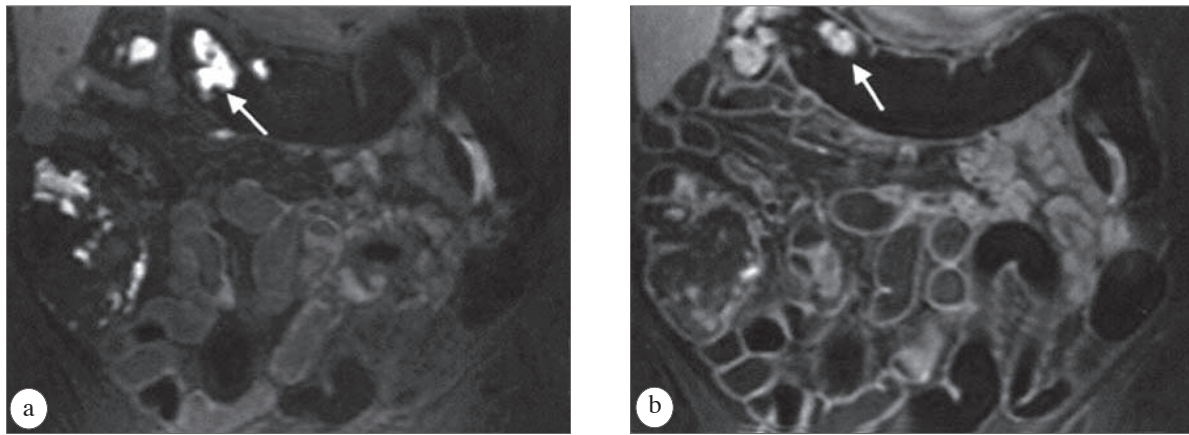


Figure 1 - Dark-lumen magnetic resonance colonography. Tap water is used for bowel distension. **a**) A native coronal T1-weighted 3D VIBE sequence. **b**) The bowel wall is bright due to intravenous application of paramagnetic contrast. Residual stool (arrow) appears bright on pre- and post-contrast phases, and shows no contrast enhancement.

phase. After data acquisition, the enema bag is placed on the floor for facilitated emptying of the colon. This protocol allows completing the examination with an in-room time of 20 minutes.

For data interpretation, the 3D data sets should be post-processed and read in multiplanar reformation mode (MPR). This permits scrolling through the 3D data sets in all 3 orthogonal planes. The diagnostic work-up should start interpreting the contrast-enhanced data. Whenever a mass protruding from the colonic wall is detected, the identical part of the colon should be analyzed on the pre-contrast scan. By measuring signal intensities of the mass in the native and post-contrast scans, a contrast enhancement value can be determined. Hence, the differentiation between small residual stool particles and colorectal lesions is simple: the residual stool does not show contrast enhancement (**Figures 1a & 1b**) whereas colorectal lesions always do. In a second step, the data should be assessed based on virtual endoscopic renderings displaying the inside of the colonic lumen. A virtual endoscopic fly-through enables the radiologist to concentrate on the colon by facilitating the depiction of small structures protruding into the colonic lumen. Furthermore, the 3D depth perception allows discrimination between polyps and haustra. To assure complete visualization of both sides of the haustral folds, the virtual fly-through should be performed in antegrade and retrograde directions with regard to the detection of polyps, virtual endoscopic viewing renders improved sensitivity and specificity values as compared with inspection of the individual cross-sectional images alone.

Dark-lumen MRC was first introduced and evaluated in 2001.² Twelve patients with suspected colorectal lesions were examined. In addition to dark-lumen MRC, all patients underwent conventional colonoscopy performed within 5-14 days. Five polyps ranging in diameter from 7-12 mm were detected. All lesions were confirmed by conventional colonoscopy and subsequent polypectomy was performed. There were no false negative findings. The intravenous administration of paramagnetic contrast resulted in an average signal-to-noise ratio increase within the colonic wall of 170% from 9.2 to 24.8 ± 2.6 . This difference was statistically significant ($p < 0.001$). Polyps showed even more enhancement with signal intensities increasing by 306% from 8.9 ± 1.6 to 36.1 ± 3.9 . Lack of contrast enhancement correctly identified 3 bright "lesions" as residual stool. In addition, dark-lumen contrast-enhanced MRC depicted 4 extra-intestinal lesions: 2 renal cysts in 2 patients, one hepatic hemangioma in one patient, and one aortic abdominal aneurysm measuring 4 cm in diameter in another patient.

A recent study used a larger patient cohort³ of 122 patients undergoing dark-lumen MRC and subsequent conventional colonoscopy. The MRC did not detect lesions smaller than 5 mm. For lesions between 5-10 mm, MRC correctly detected 16 of 18 lesions. Nine of 9 CRCs with lesions larger than 10 mm were seen on MRC images. In addition, conventional endoscopy documented inflammatory wall alterations (Crohn's disease and ulcerative colitis) in 28 patients. The MRC correctly diagnosed inflammatory changes

in 25 patients. In 3 patients with Crohn's disease, inter-intestinal fistulae were detected with MRC and conventional colonography. There were no false positive readings based on the MRC data sets. In addition, dark-lumen MRC permitted the reliable assessment of extra-intestinal organs. Thus, a variety of therapy-relevant and irrelevant pathologies were identified. Hepatic metastases were observed in 4 patients, and the bone metastases were seen in 7 patients. Both studies emphasize that dark-lumen MRC may overcome several limitations inherent to bright-lumen MRI techniques. The intravenous application of paramagnetic contrast technique allows the direct depiction of the colorectal wall. Thus, the bright colonic wall can be easily discriminated from the dark, water-filled colonic lumen. This form of direct visualization of all colorectal pathologies reduces the incidence of false positive findings: residual stool or air bubbles, which might mimic small polyps in the bright-lumen technique, remain dark. Hence, lack of contrast enhancement between the pre- and post-contrast scans to rule out the presence of a colorectal mass. Beyond the identification of colorectal lesions, dark-lumen MRC permits the detection and characterization of colonic wall inflammation. Based on the assessment of bowel wall thickness and bowel wall contrast the enhancement, diverticulitis, Crohn's disease, and ulcerative colitis can be diagnosed with great accuracy. Common to all 3 entities, the colonic wall is thickened and characterized by increased contrast uptake.

Virtual colonography still mandates bowel purgation. As more than 50% of patients undergoing bowel preparation complain regarding negative side effects, patient compliance is negatively affected. If bowel cleansing were avoided, patient acceptance of MRC could be considerably increased. This can be accomplished by fecal tagging; a concept based on altering the signal intensity of stool by adding contrast-modifying substances to regular meals. Thus, fecal tagging may render stool virtually indistinguishable from the distending rectal enema on MR images. In an initial study, barium sulfate was evaluated as a tagging agent in conjunction with dark-lumen MRC.⁴ Two hundred milliliters of a barium sulfate containing contrast agent was ingested with each of 4 principal low-fiber meals. Barium proved

to be a safe and inexpensive tagging agent rendering the stool homogeneously dark and permitting the selective depiction of the contrast-enhancing colonic wall. Due to the low signal intensity of barium-tagged stool, signal differences between the colonic lumen and the colonic wall were high throughout the entire large bowel. However, further studies need to be performed to evaluate the value of barium-based fecal tagging with respect to patient acceptance and diagnostic accuracy.

To date distension of the colonic lumen for MRC has been accomplished predominantly with water or water-based contrast media. Better density properties and the assumption that air provides less discomfort than water has resulted in the predominant use of gaseous agents for CT colonography. Although similar to water with regard to MR signal properties on T1-weighted images, the fear of susceptibility artefacts rendered the use of air or other gases much less intuitive for MRC. Recently, the feasibility of air-distended dark-lumen MRC has been proved.⁵ Fifty patients who had been referred to colonoscopy for suspected colorectal pathology were randomized into water-distension and air-distension groups. Dark-lumen MRC was performed in both groups. Comparative analysis was based on qualitative ratings of image quality and bowel distension and on contrast-to-noise ratio (CNR) measurements for the colonic wall with respect to the colonic lumen. In addition, patient acceptance was evaluated. No significant differences were found between air and water distension with respect to discomfort levels and image quality. The presence of air in the colonic lumen was not associated with susceptibility artefacts. The CNR of the contrast-enhanced colonic wall and bowel distension were superior on air-distended 3D data sets. Hence, dark-lumen MRC can be performed with water or air for colonic distension. Both techniques permit assessment of the colonic wall and identification of colorectal masses.

Received 22nd May 2005. Accepted for publication in final form 27th September 2005.

From the Medical Prevention Center (Goyen, Ajaj), Hamburg University Medical Center, Hamburg and the Department of Diagnostic and Interventional Radiology and Neuroradiology (Lauenstein), University Hospital Essen Hufelandstrasse, Essen, Germany. Address correspondence and reprint requests to: Dr. Mathias Goyen, University Medical Center Hamburg-Eppendorf, Martinistrasse 52, 20246 Hamburg, Germany. E-mail: goyen@uke.uni-hamburg.de

References

1. Landis SH, Murray T, Bolden S, Wingo PA. Cancer statistics, 1998. *CA Cancer J Clin* 1998; 48: 329.
2. Lauenstein TC, Herborn CU, Vogt FM, Gohde SC, Debatin JF, Ruehm SG. Dark lumen MR-colonography: initial experience. *Rofo* 2001; 173: 785-789.
3. Ajaj W, Pelster G, Treichel U, Vogt FM, Debatin JF, Ruehm SG, et al. Dark lumen magnetic resonance colonography: comparison with conventional colonoscopy for the detection of colorectal pathology. *Gut* 2003; 52: 1738-1743.
4. Lauenstein TC, Goehde SC, Ruehm SG, Holtmann G, Debatin JF. MR colonography with barium-based fecal tagging: initial clinical experience. *Radiology* 2002; 223: 248-254.
5. Ajaj W, Lauenstein TC, Pelster G, Goehde SC, Ruehm SG, Debatin JF. MR colonography: How does air compare to water for colonic distension. *J Magn Reson Imaging* 2004; 19: 216-221.

The use of etoricoxib in patients with bronchial asthma associated with aspirin sensitivity

*Ibrahim K. Nahar, FRCPC, ABIM,
Abdulaziz T. Muqim, FRCPC, FCCP,
Bassmah I. Al-Qhouti, BSc,
Adeeba A. Al-Herz, FRCPC, ABIM,
Diaa K. Shehab, BMBCh, FRCPC,
Singh S. Uppal, MD, MRCP,
Mousa E. Khadadah, BMBCh, FRCP.*

Patients with sensitivity to aspirin (ASA) or non-steroidal anti-inflammatory drugs (NSAIDs), may develop an acute asthma attack, thus, limiting the use of such agents. Sensitivity to aspirin may occur in up to 20% of patients with bronchial asthma.¹ Aspirin induced asthma (AIA) usually presents for the first time in the third or fourth decades of life.² The reaction is usually slow in onset, 30-60 minutes following ingestion, manifesting as bronchospasm with profound nasal symptoms, including nasal congestion, rhinorrhea, and tearing. Facial flushing, angioedema, and gastrointestinal symptoms can also occur. This complex reaction is slow to resolve, and often severe and may be life threatening. Furthermore, AIA can be sometimes difficult to treat. Such patients are proven to have airway inflammation, which is resistant to corticosteroids and may require leukotriene receptor antagonists as therapy.² These patients sometimes have associated nasal polyposis or chronic urticaria.² Patients with AIA can react to NSAIDs, which differ in structure from aspirin, therefore, suggesting a non immunological mechanism involved in this disease state.¹ The reason why ASA sensitivity does occur

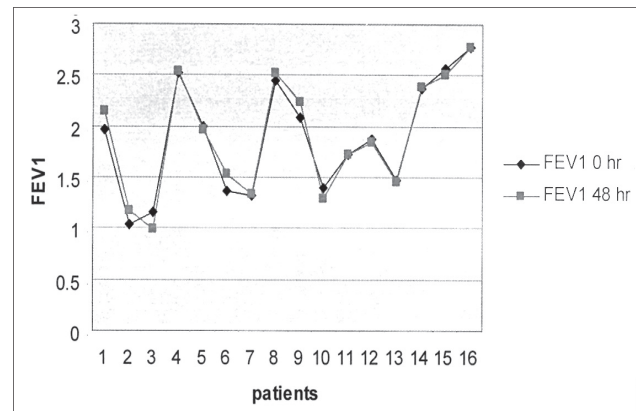


Figure 1 - Comparison of forced expiratory volume (FEV)1 at study entry and on subsequent follow-up of pulmonary function test.

in bronchial asthma is not clear. Two theories were proposed to explain AIA. The first theory suggests that asthma may develop through inhibition of cyclooxygenase 1 (COX-1) resulting in decreased production of prostaglandin E₂, which is important in maintaining bronchodilation.² The second theory suggests an overexpression of leukotriene C₄ synthetase, from blockage of COX by ASA or NSAIDs. The arachidonic acid precursors are shunted down the leukotrienes pathway resulting in excessive production of leukotrienes C, D, E, which can act as potent bronchoconstrictors.² Recently, 2 isoforms of COX have been found, namely, COX-1 and COX-2. Both enzymes catalyze the transformation of arachidonic acid to prostaglandins and thromboxanes. The COX-1 enzyme is expressed constitutively in many healthy tissues of the body where prostaglandins have physiologic effects, including the gastrointestinal tract, kidneys, and platelet, whereas COX-2 enzyme is induced at sites of inflammation.³ The inhibition of COX-1 has been related to the adverse effects of NSAIDs.³ Non-steroidal anti-inflammatory drugs that selectively inhibit COX-2 enzyme (selective COX-2 inhibitors) has been recently developed. These drugs were shown to have a comparable efficacy to traditional NSAIDs and are better tolerated. They have become widely available in the market for the management of a variety of musculoskeletal disorders. Little is known regarding the safety of selective COX-2 inhibitors in patients with AIA. A few recent trials have found some selective COX-2 inhibitors to be safe in patients with AIA.^{4,5} Of these drugs, celecoxib was the first generation selective COX-2 inhibitors that were developed. Par Gyllfors et al,⁴ assessed 33 aspirin sensitive asthmatics, challenged on 2 occasions, one week apart, with increasing doses of celecoxib (total

400 mg daily). Lung function, clinical symptoms, and urinary excretion of leukotriene E4 (LTE4) were monitored during the study period. All 33 patients showed no change in symptoms, lung function, or alteration of urinary LTE4 levels. In another study by Woessner et al,⁵ none of the 60 subjects with asthma developed symptoms nor decline in forced expiratory volume (FEV)₁ following challenge with celecoxib 200 mg. Etoricoxib is a selective COX-2 inhibitor that has been recently available in the market for management of patients with osteoarthritis and rheumatoid arthritis. It has the highest, in vitro, COX-2 selectivity of any other coxib. Its safety in AIA has not been tested before. The objective of this study is to evaluate the safety of etoricoxib in patients with bronchial asthma followed at Mubarak Al-Kabir Hospital, a large teaching hospital in Kuwait City.

From September 2003 to December 2004, patients with musculoskeletal diseases requiring NSAIDs therapy were referred to the rheumatology outpatient department at Mubarak Al-Kabir Hospital, a large University teaching hospital in Kuwait City. Those with a history of bronchial asthma were referred to a qualified respirologist for further assessment. Eligible patients had their initial clinical and functional assessments for bronchial hyperreactivity (defined as a significant improvement in FEV₁ of $\geq 12\%$ and 200 cc following salbutamol inhalation). Patients were categorized into mild, moderate, and severe asthma according to the American Thoracic Society guidelines for the management of asthma.⁶ Only patients with mild to moderate asthma and history of sensitivity to aspirin or NSAIDs were eligible for inclusion into the study. These patients were given etoricoxib (Arcoxia®, MSD) 90 mg once daily and were re-assessed, through the same respirologist, clinically and physiologically 48 hours later. All patients were required to take etoricoxib for at least 3 hours before their clinical and pulmonary function test (PFT) re-assessment. Primary outcome measure was a reduction in FEV₁ by $\geq 15\%$ on their follow up PFT following the drug administration. Secondary outcome measures were self reported asthma symptoms including wheezes, dyspnea, cough and nighttime symptoms, nasal complaints (sneezing, nasal blockage, and rhinorrhea), as well as the objective presence of wheezes on physical examination as evaluated by the pulmonary physician. Eighteen patients were included in the study. Two were subsequently excluded: one patient had biopsy-proven bronchiolitis as the respiratory diagnosis, while the other patient did not complete the clinical

and physiological evaluation on follow up visit. The vast majority of patients (15 out of 16) were females (94%). The average age of studied individuals was (50 years) with a median of 48. Eleven patients (69%) had mild asthma, of which 5 had intermittent (31%) and 6 (38%) had persistent clinical presentation. Five (31%) patients had their asthma severity falling into the moderate persistent category. None of the patients received systemic corticosteroids for a minimum of 3 months before the study, nor were oxygen dependent. Two patients were on inhaled salbutamol metered dose inhaler and 5 patients were on regular and moderate doses of inhaled corticosteroid (500 mic of Fluticasone diskus or equivalent). None of the patients developed deterioration in FEV₁ of $\geq 15\%$ on their follow up PFT (the primary outcome) (**Figure 1**). Of the 16 study patients, none had reported symptoms of bronchial asthma or nasal complaints nor were found to have wheeze on clinical examination performed by the pulmonary physician. Our results have shown etoricoxib to be safe in patients with mild to moderate bronchial asthma, which should encourage further research to establish the safety of selective COX-2 inhibitors, namely, etoricoxib, in patients who are sensitive to ASA or NSAIDs.

Received 14th May 2005. Accepted for publication in final form 27th September 2005.

From the Department of Medicine, Mubarak Al-Kabir Hospital, Al-Jabriya, Kuwait. Address correspondence and reprint requests to: Dr. Ibrahim K. Nahar, Consultant Rheumatologist, Department of Medicine, Mubarak Al-Kabir Hospital, PO Box 43787, Postal Code 32052, Al-Jabriya, Kuwait. Tel. +(965) 5311421. Fax. +(965) 5318525. E-mail: ebrahimmahar@hotmail.com

References

- Jenkins C, John Costello J, Hodge L. Systematic review of prevalence of aspirin induced asthma and its implications for clinical practice. *BMJ* 2004; 328: 434.
- Szczeklik A, Stevenson DD. Aspirin-induced asthma Advances in pathogenesis, diagnosis, and management. *J Allergy Clin Immunol* 2003; 111: 913-921.
- FitzGerald GA, Patrono C. The Coxibs, selective inhibitors of cyclooxygenase-2. *N Engl J Med* 2001; 6: 433-442.
- Gyllfors P, Bockenek G, Overholt J, Drupka D, Kumlin M, Sheller M, et al. Biochemical and clinical evidence that aspirin-intolerant asthmatic subjects tolerate the cyclooxygenase 2-sensitive analgetic drug celecoxib. *J Allergy Clin Immunol* 2003; 111: 1116-1121.
- Woessner KM, Simon RA, Stenvenson DD. The safety of celecoxib in patients with aspirin-sensitive asthma. *Arthritis Rheum* 2002; 46: 2201-2206.
- National Heart, Lung, and Blood Institute. Global initiative for asthma: global strategy for asthma management and prevention; NHLBI/WHO workshop report, March 1993. Bethesda, MD: National Heart, Lung, and Blood Institute, 1995; Publication No. 95-3659

Diagnostic value of MR imaging in meniscal tears of the knee

*Khalilollah Nazem, MD, Khashayar Jabalameli, MD,
Farhad Iranpour, MD.*

Meniscal injuries are one of the most common causes of referral to orthopedics. As timely treatment is extremely important to prevent chronic complications and disabilities, early and appropriate diagnostic evaluation should be respected for all patients with symptoms of meniscal injuries. Currently, the gold standard for evaluating meniscal injuries is arthroscopy. However, the costs and morbidities of arthroscopy have encouraged investigators to find a substitute diagnostic modality, and one of those is magnetic resonance imaging (MRI). The diagnostic accuracy of MRI has been investigated in several studies, but the results are conflicting.^{1,2}

Between May and November 2004, 36 patients were enrolled in the study in the Department of Orthopedics of Alzahra Hospital, Isfahan, Iran. The included patients were suspected of having meniscal injury based on positive McMurray's test established by an orthopedic surgeon. Subjects with prior surgical interventions of the involved knee joint or any contraindication for arthroscopy or MRI were excluded. The MRI was carried out on a 0.5 Tesla unit (Philips NP) with a 256 x 256 matrix. Sagittal T1-weighted, Proton-density and T2-weighted spin-echo sequences, transverse T2-weighted gradient-echo-recalled, and coronal spectral presaturation inversion recovery (SPIR) sequences were obtained on MR imaging examinations of the knee. Spinal echo and gradient echo images were performed with slices of 2-4 mm thickness. Following an average gap of 8 days, an orthopedic surgeon who was unaware of the MRI findings performed arthroscopy. The arthroscopic findings were considered as the standard of reference.

Twenty-one medial meniscal tears and 9 lateral meniscal tears were found at arthroscopy. For medial meniscus tears, the sensitivity of MR imaging was 57.1%, whereas its specificity was 60%. For lateral meniscus tears, MR imaging was 44.4% sensitive and 60% specific. The positive predictive value (PPV) of MR imaging was 66.7% for medial meniscus tears, and only 28.6% for lateral meniscus tears. The negative predictive value (NPV) was 50% for the medial meniscus, and 77.3% for the lateral meniscus. The overall accuracy of MR imaging for medial was 58.3% and for lateral menisci was 58.3%. The overall

Table 1 - Location, zone and type of tearing in medial and lateral menisci.

Variable	Medial meniscus	Lateral meniscus
Location of tearing		
Posterior horn	15 (5)	3 (2)
Middle segment	6 (3)	6 (3)
Zone of tearing		
Peripheral	14 (5)	2 (1)
Nonperipheral	7 (4)	7 (4)
Type of tearing		
Longitudinal	19 (9)	2 (2)
Other	7 (4)	7 (3)
Values in parentheses are the number of false negatives in MRI reports		

values for MRI of the medial and lateral menisci combined were: accuracy 58.3%, PPV 50%, NPV 65%, sensitivity 53.3%, and specificity 61.9%. The location, zone and type of meniscal tearing are shown in **Table 1**.

Most false negative results have been reported in patients with rupture in the posterior part of the meniscus, especially when concurrent injury to adjacent structures, such as the anterior cruciate ligament is present.^{4,5} The reported sensitivity and specificity of MRI for detecting medial meniscal tear ranges from 74-98% for sensitivity and 66-88% for specificity.^{1,3,5} It seems that in the case of lateral meniscus, MRI is less sensitive (50-94%) but more specific (84-98%).^{1,3,5} This finding is also accurate in our study, but false positive and false negative reports in this study were considerably more than most previous surveys. The highest frequency of false negative results was observed in patients with rupture in the posterior horn of the medial meniscus, although the sample size is not large enough for confident generalization.

Multiple factors may be responsible for the low accuracy of MRI in some centers. Performing MR imaging at low-field (0.5T) in comparison with high-field (1.5T) usually leads to less accurate results. Taking additional images such as fat-suppression-echo technique might result in a less false negative rate. At last, a source of pitfall in the diagnostic value of MRI is the interpretation errors due to insufficient familiarity of radiologists with normal variants in the anatomy of the knee. More experience of the radiologists would markedly contribute to more accurate results.

In summary, we conclude that MRI, with the technique used, could neither obviate the need for arthroscopy in patients with normal reports, nor select

patients with need for meniscal surgery. Further investigations to clarify the causes of false positive and false negative reports may contribute to the more appropriate application of MRI in the future.

Received 12th July 2005. Accepted for publication in final form 17th September 2005.

From the Department of Orthopedics, AlZahra Hospital, Isfahan University of Medical Sciences, Isfahan, Iran. Address correspondence and reprint requests to: Dr. Khashayar Jabalameli, Resident, Department of Orthopedics, AlZahra Hospital, Isfahan University of Medical Sciences, Isfahan, Iran. Tel. +98 9131134081. Fax. +98 3116613118. E-mail: farhad2000i@yahoo.com

References

1. Lundberg M, Odensten M, Thuomas KA, Messner K. The diagnostic validity of magnetic resonance imaging in acute knee injuries with hemarthrosis. A single-blinded evaluation in 69 patients using high-field MRI before arthroscopy. *Int J Sports Med* 1996; 17: 218-222.
2. Heron CW, Calvert PT. Three-dimensional gradient-echo MR imaging of the knee: comparison with arthroscopy in 100 patients. *Radiology* 1992; 183: 839-844.
3. Kelly MA, Flock TJ, Kimmel JA, Kiernan HA Jr, Singson RS, Starron RB, et al. MR imaging of the knee: clarification of its role. *Arthroscopy* 1991; 7: 78-85.
4. Imhoff A, Buess E, Hodler J, Fellmann J. Comparison between magnetic resonance imaging and arthroscopy for the diagnosis of knee meniscal lesions. *Rev Chir Orthop Reparatrice Appar Mot* 1997; 83: 229-236.
5. De Smet AA, Graf BK. Meniscal tears missed on MR imaging: relationship to meniscal tear patterns and anterior cruciate ligament tears. *AJR Am J Roentgenol* 1994; 162: 905-911.

Intramuscular artemether in the treatment of uncomplicated *Plasmodium falciparum* malaria in Sudanese patients

Ayda R. Mohammed-Ali, MD,
Musa M. Kheir, MRCP, MD,
Ishag Adam, MD.

Early diagnosis and effective treatment with an appropriate drug forms the main component of the World Health Organization's strategy to reduce malaria related mortality.¹ Malaria almost causes 7.5-10 million cases and 35000 deaths every year in Sudan.² There is high level of *Plasmodium falciparum* (*P. falciparum*) resistance to chloroquine (76%) in Sudan and quinine resistance is emerging as well.³

Artemisinin is a relatively new drug not related to quinolones and has been shown to be effective for

multidrug-resistant *P. falciparum* strains. Artemether is the only registered and available parental formula of the compound in Sudan, it has been shown to be effective and safe than quinine in the treatment of severe malaria in Sudanese children.⁴ However, few published data exist concerning the usage of artemether in Sudan. Furthermore, the injectable forms of antimalarials were preferred by Sudanese patients.⁵

The objective of this study was to examine the safety and efficacy of artemether in the treatment of uncomplicated *P. falciparum* malaria in Sudanese patients.

The study received the ethical clearance of the faculty of medicine, University of Khartoum, and was carried out in Khartoum Teaching Hospital, Sudan, between June-September 2004. Adults (>15 years) febrile patients (temperature >37.5°C) who presented with symptoms of falciparum malaria and confirmed malaria parasite were admitted to the hospital. Pregnant women were excluded. After well-informed written consent, they were enrolled in this study to receive artemether. Full history, physical examinations were performed and data were recorded. Peripheral blood smears were prepared, stained with Giemsa and examined under oil immersion for parasite.

Parasites and leucocytes were counted in the same fields until 200 leucocytes were counted; parasites densities were estimated using an assumed leucocytes count of 6000 leucocytes/mm³ of blood. Baseline investigations (hemoglobin, urine) were performed.

Artemether (Kunming Pharmaceutical Factory, Kunming, People's Republic of China) was given by intramuscular route, 80 mg initially then 80 mg after 12 hours, and then 80 mg daily to complete 8 injections (640 mg) over 7 days. Temperature was recorded every 6 hours until it became normal (<37.5°C) and remained so for at least 24 hours, then recorded daily. Blood films for malaria were carried out every 12 hours until they were negative in 2 consecutive smears and then daily till day 7, and on days 14, 21 and 28. Pulse, blood pressure, respiratory rate were recorded every 6 hours. Patients were kept in the hospital for 7 days, then seen on days 14, 21 and 28. Urine, hemoglobin and blood film for malaria were rechecked.

Data were entered into a computer database and Statistical Package for Social Sciences software (Chicago, IL, USA) was used for statistical analysis. The means of the temperature and parasite clearance times were calculated in hours after initiation of treatment.

Table 1 - Baseline characteristics of the patients treated with artemether for uncomplicated falciparum malaria and completing the 28 days of follow-up.

Variable	Mean \pm SD
Age (years)	37.9 \pm 11.46
Weight (kg)	68.7 \pm 7.6
Temperature ($^{\circ}$ C)	38.01 \pm 0.62
Parasite count, rings/ μ l	15820 \pm 9680, 6750
Hemoglobin, gm/dl	12.16 \pm 1.3

Fifty patients with falciparum malaria were enrolled and completed the 28-days of follow-up. **Table 1** shows the patients' different variables at the time of the admission. All patients presented with fever, backaches, nausea, vomiting, and headache. Giddiness were the symptoms in 24% of the patients and diarrhea in 16% of the patients. Twenty-four (48%) of the patients were females. The mean (SD) fever clearance time was 32.1 (12.1) hours and 37.9 (12.4) hours for the parasites. No patient developed abscess at the site of the injections.

The symptoms of malaria reoccurred in one patient (2%) at day 7 and the blood film for malaria was found positive, namely, artemether efficacy was 98% at day 28. There was no gametocytemia during the follow-up. None of the patients developed adverse effects. The study showed that, intramuscular artemether is safe and effective in the treatment of adults Sudanese patients with uncomplicated falciparum malaria.

Received 18th June 2005. Accepted for publication in final form 17th September 2005.

From the Department of Medicine (Ali, Kheir), and the Department of Obstetric and Gynecology (Adam), Faculty of Medicine, University of Khartoum, Sudan. Address correspondence and reprint requests to: Dr. Ishag Adam, Department of Obstetrics and Gynecology, Faculty of Medicine, University of Khartoum, PO Box 102, Khartoum, Sudan. Tel. +249 912770277. Fax. +249 183476299. E-mail: ishagadam@hotmail.com

References

1. World Health Organization. A global strategy for malaria control. Geneva: WHO, 1993.
2. Malik EM, Khalafalla OM. Malaria in Sudan: past, present and the future. *Gezira Journal of Health Sciences* 2004; 1 (suppl): 47-51.
3. Adam I, Osman ME, EIGHazali G, Ahmed GI, Gustafson LL, Elbashir MI. Efficacy of chloroquine, sulfadoxine-pyrimethamine and quinine for the treatment of uncomplicated *Plasmodium falciparum* malaria in Eastern Sudan. *Ann Trop Med Parasitol* 2004; 98: 661-666.

4. Adam I, Idris H, Mohamed-Ali AA, Alelbasit IA, Elbashir MI. Quinine versus artemether in the treatment of severe falciparum malaria in Sudanese children. *East Afr Med J* 2002; 79: 621-625.
5. Abdel-Humeed AA. Malaria case management at the community level in Gezira Sudan. *Afr J Med Sci* 2001; 30: 43-46.

Validity and reliability of the Turkish version of the ferrans and powers quality of life index diabetes version

Zeynep C. Ozer, PhD, Emine Efe, PhD.

This paper describes the development of a Turkish version of a quality of life (QoL) measure for use in a cross-cultural study of antecedents of QoL amongst patients with diabetes mellitus (DM). Health-related quality of life (HRQoL), refers to the ways in which health, illness, and medical treatment influence an individual's perception of functioning and well being.¹ Both generic measures and illness oriented HRQoL measures have been developed. Increasingly, QoL assessment has been employed to evaluate outcomes among patients with chronic medical conditions. Such chronic illnesses typically are associated with decreased QoL when comparisons are made to healthy individuals. Diabetes mellitus causes marked economic and financial burden to the health care sector and the society and variable amounts of distress in patients everyday life.² Despite improvements in the quality of care, chronic-long term complications of diabetes remain an important and costly problem to the individuals and the society. These people thus endure substantial losses in HRQoL and productivity.² This paper reports the development of a translated Turkish version of the QoL index (QoLI) and preliminary testing for reliability and validity.

The research has been carried out methodologically in order to show the validity and reliability of "ferrans and power's quality of life index" in patients with DM. The research has been conducted on 227 out of 355 patients who were willing to cooperate, who received a questionnaire and were treated at the inpatient clinics in University Medical Hospital, in Turkey between May 1, 2001 and May 30, 2002. The first part of the questionnaire was composed of a personal knowledge form, which includes patients recognized features. Data were collected by personal communications with the patients by the researcher.

Table 1 - Mean and standard deviation (SD) and internal consistency of quality of life index (Turkey) subindexes.

Quality of life index	Number of question	Range	Mean \pm SD	Internal consistency Chronbach's alpha
Total index	35	10-20	15.02 \pm 91.32	0.97
Health and functioning	15	12-19	15.07 \pm 1.37	0.93
Social and economic	8	12-20	15.22 \pm 1.67	0.88
Psychological/spiritual	7	12-19	15.09 \pm 1.41	0.89
Family	5	12-20	15.24 \pm 1.60	0.85

The second part of the questionnaire was composed of a version of ferrans and powers QoLI diabetes version.³ There are 6 choices for each question. The QoLI measures both satisfaction and importance regarding various aspects of life. Importance ratings are used to weight satisfaction responses, so that scores reflect satisfaction with the aspects of life that are valued by the individual. The questionnaire consists of 35 items in 4 subindex, which assess health and functioning, social and economic, psychological/spiritual and family.

Those patients who were willing to cooperate received a questionnaire, beginning with questions on socio-demographic and diabetes data, and followed by the QoLI questionnaires. The investigator visited the patients in hospital and distributed the questionnaire. They finished the questionnaire in the hospital. Permission to translate the QoLI into Turkish was granted by the developer, Ferrans CE and Powers MJ. After permission for access to the patients was granted from the Head of Department and written, informed consent was obtained from all participants. The data collected were statistically analyzed using SPSS 10.1 for Windows in terms of internal consistency reliability and construct validity. Internal consistency of each QoLI dimension was assessed through Cronbach's α on raw data (no missing values imputed). Dimension scores of subgroups with different sociodemographic and health characteristics were compared using the scores between 2 groups independent t-test for normal distributed, between more than 2 groups using one-way ANOVA for normal distributed, between more than 2 groups using Kruskal-Wallis ANOVA non-normal distributed. Two-tailed significance levels $p < 0.05$ were accepted throughout. Parameters of distributions of scores are given as means and standard deviations (SD). Factor analyses were principle components analyses with varimax rotation. The variables are reordered so the rotated factor loading for each factor are grouped. By default, loading less than 0.25 are set to zero. If a variable has 2 loading greater than 0.5, it is ordered according to the longer of the 2.

Patients with DM has been conducted from a university hospital. For Turkish data, 227 patients responded to the QoLI, of whom 166 were men (73.1%) and 61 were women (26.9%). Independent t-test revealed a significant association of sex with psychological/spiritual ($t=2.10$, $p=0.23$); and family ($t=2.08$, $p=0.30$). Ages ranged from 35-72 and the mean age was 64. Age was not found to be significantly related to any of the other subindexes: Social and economic ($F=2.30$, $p=0.78$). In the sample of relatives, 2.6% had literate education, 15.9% had primary school, 33% had middle school, 25.1% had high school, and 23.3% University. The ANOVA reveal a significant association of education with health and functioning ($\chi^2=11.68$, $p=0.20$); Social and economic ($\chi^2=13.15$, $p=0.11$); Psychological/spiritual ($\chi^2=13.54$, $p=0.09$); Family ($\chi^2=10.63$, $p=0.31$). **Table 1** displays mean scores, SD, and internal consistency of QoLI indexes. QoLI subindex suggests, which followed health and functioning, social and economic, psychological/spiritual, family. Note that the alpha coefficient depends on the number of items in the subindex, making it easier to obtain higher values with longer indexes (Cronbach alpha, ranging from 0 to 1) (**Table 1**). A principal component analysis was performed and rotated by the varimax method. The QoLI like the 4-factor structure put forward by ferrans and powers,³ also evaluated 4 factors. The 4 factors together explained 65.2% of the cumulative variation. Factor 1 (explaining 53.2% of the common variance) reflects the "health and functioning". Factor 2 (explaining 4.4% of the common variance) can be labeled "social and economic". Factor 3 (explaining 3.9% of the common variance) is labeled "psychological/spiritual." Factor 4 (explaining 3.6% of the common variance) is labeled "family."

Discussion on meanings of words among an intimate couple of a Turkish native speaker is, as far as we are aware, novel in the formal cross-cultural translation of psychometric indexes and may greatly contribute to the equivalence between the original

and target language versions. Construct validity of the QoLI was supported by strong correlations between the overall (total) QoLI score and measure of life satisfaction ($r = 0.61, 0.65, 0.75, 0.77, 0.80, 0.83, 0.93$).³ Factor analysis of the 4 primary factors revealed one higher order factor, which represented QoL.³ Internal consistency reliability for the QoLI (total index) was supported by Cronbach's alphas ranging from 0.84-0.98 across several studies.^{4,5} Alphas ranged from 0.70-0.93 for the health and functioning subindex, from 0.73-0.89 for the social and economic subindex, and from 0.80-0.93 for the psychological/spiritual subindex, for the family subindex alphas were acceptably.³ All of the QoLI subindex were obtained with sufficient internal consistency. Frequency distributions for all QoLI dimensions were skewed towards good perceived health. As has been discussed, a number of efforts were made to produce a Turkish translation of the QoLI as equivalent as possible, with high internal consistency reliability and construct validity. However, the influence of cultural differences on the experience of QoL cannot be eliminated. What causes QoL would differ, although this is largely eliminated by the measurement's focus on the QoL. The expression of the QoL response may also differ but as the translation process was based on meaning, it identified concepts that were similar to those identified in the original version, and recognized that these concepts were related to QoL in the target culture. However, it is difficult to ensure that the precise valence of these responses (in terms of the amount of QoL experienced) is equivalent.

The QoLI were found to be clearly related to the demographic variables. The relationship between the QoLI responses and demographic variables is not unexpected in light of the results of prior studies in the domain, but it necessitates the use of specific norms for specific groups (for example, separate norms for men and women). One need, however, appeared to be independent from demographic influences. Apparently, information is of such extreme importance for all relatives that there is little between-subject variation in the scores on the items referring to it.

We conclude that the QoLI is a suitable tool for the study of QoL among Turkish patients, and that there is sufficient evidence of the equivalence of the QoLI to consider them as equivalent in cross-cultural studies.

Acknowledgment. We are grateful to all the patients who participated in this study. This study received external funding from Akdeniz University Scientific Research Project Unit.

Received 6th July 2005. Accepted for publication in final form 27th September 2005.

From the Department of Medical Nursing (Ozer) and the Department of Pediatric Nursing (Efe), Akdeniz University School of Health, Antalya, Turkey. Address correspondence and reprint requests to: Dr. Zeynep C. Ozer, Akdeniz University School of Health Antalya 07058, Turkey. (Turizm ve Otelcilik Yuksekokul Binasi Girisi Kat). Tel. +90 (242) 2274343-22118. Fax. +90 (242) 2261469. E-mail: zeynepardaozer@yahoo.com

References

1. Coons SJ, Kaplan RM. Assessing health-related quality of life: Application to drug therapy. *Clin Therap* 1992; 14: 850-858.
2. Songer T. Disability in diabetes. In: Harris MI, Cowie CC, Stern PP, Boyko EJ, Reiber GE, Bennett PH, editors. Diabetes in America. 2nd ed. National Diabetes Data Group: NIH Publication no. 95-1468. Washington, DC: US Government Printing Office, 1995. p. 259-282.
3. Ferrans CE, Powers M, editors. Quality of life index: Development and Psychometric Properties (Updated 2003 September). Available from: <http://www.uic.edu/orgs/QoLI>.
4. Kolz N. Self perceived quality of life following cardiac surgery. *Heart and Lung* 1989; 18: 304.
5. Biley AV, Ferrans C. Quality of life after angioplasty. *Heart and Lung* 1993; 22: 193-199.

Domestic violence experiences among medical students in 2 universities

Serpil Aydin, MD.

Domestic violence (DV) is a worldwide, but least recognized, human rights abuse problem.¹ There is no absolute evidence of symptoms or signs of it,² so it is important for primary care physicians to be able to identify DV. Primary care research shows that DV experience across the life span of a person is changing between 12-46%. However, less than 10% of the cases are identified by primary care doctors.³ Lopez and Heffer⁴ state that 8.6% of university students have experienced childhood physical DV. Physicians, who are educated or trained to recognize DV, are more likely to identify it. Lapidus et al,⁵ reports that prior DV training is the strongest predictor of a physician's ability to diagnose DV during a routine screening. They also suggest that training is important to improve the rate of identification of DV, but in many countries including Turkey, physicians receive no education or training in DV during their medical education. In Turkey, many of the medical school students are employed in primary care just after their graduation,⁶ so it is very important to call

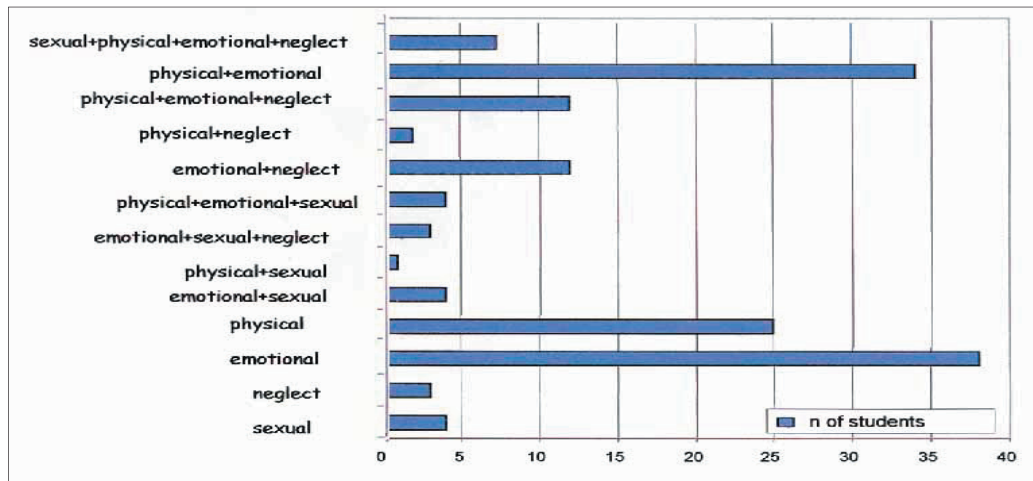


Figure 1 - Violence profile of students.

medical students' attention to this issue. Poverty, substance abuse, family disruption, and past history of abuse can increase the risk for family violence.² If these risk factors can be noticed, then it is easier to identify the abuse or violence. The goals of this study are: 1. to increase our students' awareness and recognition of this issue; 2. to determine the future doctors' approach to recognizing DV; 3. to define DV, neglect, or assaults that these doctors may have experienced, 4. to determine the socioeconomic status of our students in order to identify any child abuse risk factors among our students; and 5. to increase community awareness of DV.

During May-June 2003, voluntary-based anonymous questionnaires, consisting of 30 closed-ended questions, were given to medical students in Suleyman Demirel University (SDU) and Celal Bayar University (CBU). The target population was all medical students in these schools. Although, this project was approved by the Ethics Committee of Suleyman Demirel University, School of Medicine, only volunteers took part. Participation was based on oral informed consent, and confidentiality and anonymity were assured to the students. Both of the schools' curricula do not provide any DV training. Chi-square, ANOVA, and Spearman correlation tests were performed for the statistical analysis. A p -value of <0.05 was considered to be statistically significant.

Of 469 students, 287 (61.2%) completed the questionnaires. The response rate was better among SDU students (65.2%). The mean age was 21.3 ± 0.1 . Females comprised 158 (55.1%), and 52% of the respondents stated that they had been abused at least once in their lives. Of the total respondents, 41

students thought that the violence was deserved; this opinion was more common among those who forced violence on others. Males and substance abusers showed a higher tendency towards domestic violence ($p<0.05$). Students, who were abused physically and emotionally and were neglected, showed a greater inclination to perform violence ($p<0.001$). Generally, the students' fathers were retired, and their mothers were housewives. The students mostly come from families, who had a monthly income of \$300-500. Low incomes showed less physical abuse. Mothers generally graduated from primary school while the fathers had a university level education. The CBU students had a higher socioeconomic status and educational level of their parents. The mean number of brothers/sisters was 2.4 ± 1.1 . One hundred and eighty-eight students had their own room at home; a greater percentage of CBU students had their own room at home. Parents of 152 students had never quarreled. There was no correlation between quarreling and abuse. Parents of only 9 of the students were divorced (0.03%). Only 45 mothers abused substances, while 144 fathers abused substances (including cigarette). Fathers who abuse substances showed more violence. **Figure 1** shows the distribution of students according to the types of violence. Fifty-one (21 females and 30 males) students (17.8%) stated that they abused members of their families, mostly brother/sister and boy/girlfriend. Females generally inflicted emotional abuse, while males physically abused. Students reported that they had been physically abused mostly during their childhood, especially between the ages of 6-12 years old, while the other types of abuses were seen during their adolescent period. Physical violence was mostly performed by their parents

and was equally split between the mothers and fathers. Emotional abuse was mostly performed by fathers. Teachers tended to use physical violence as punishment, especially during primary school. There was no statistically significance among physical abuse, emotional abuse, or neglect according to the school and gender; however, females experienced more sexual abuse ($p < 0.0001$). Physical abuse was commonly seen as beating, punching, and burning. Emotional abuse was seen as insulting, controlling, refusing, and threatening. Sexual abuse was seen as verbal abuse, touching external sexual organs without permission, and penetration. Neglect was seen mostly as neglecting to feed and to buy clothes. Our students' experienced childhood physical abuse at a rate of 26.5%, and sexual abuse at a rate of 35.9%. According to our results, emotional abuse was the most prevalent, while neglect was the least. We found substance abuse and previous history of abuse to be risk factors. According to our results, beating was the most commonly experienced DV behavior.

Our study can serve as a beginning as it identifies socioeconomic levels and substance abuse, thus, bringing an awareness of these risk factors to the DV issue. Further studies can be performed to increase community awareness, and to investigate the knowledge of medical students regarding identifying abuse. As DV experiences of our students are considerable, it is important to conduct further research into this issue. Besides breaking the abuse

chain between generations, decreasing substance abuse and consumption can play a role in decreasing DV.

Acknowledgment. We would like to thank our participants, and Dr. S. Yavuz and Dr. M. Asirdizer for their help in collecting the data and we acknowledge Janice O. Vantrease for her grammatical review.

Received 26th July 2005. Accepted for final publication in final form 27th September 2005.

From the Department of Family Medicine, Adnan Menderes University, School of Medicine, Aydin, Turkey. (Formerly affiliated to Department of Family Medicine, School of Medicine, Suleyman Demirel University, Isparta, Turkey). Address correspondence and reprint requests to: Dr. Serpil Aydin, P.K. 112 09000 Aydin, Turkey. Tel. +90 (256) 2514588. Fax. +90 (256) 2146594. E-mail: serpilden@yahoo.com / serpilaydin@e-kolay.net

References

1. Stewart DE, Robinson GE. A review of domestic violence and women's mental health. *Arch Women Ment Health* 1998; 1: 83-89.
2. Eyler AE, Cohen M. Case Studies in Partner Violence. *Am Fam Physician* 1999; 60: 2569-2576.
3. Bradley F, Smith M, Long J, O'Dowd T. Reported frequency of domestic violence: cross sectional survey of women attending general practice. *BMJ* 2002; 324: 271-275.
4. Lopez MA, Heffer RW. Self-concept and social competence of university student victims of childhood physical abuse. *Child Abuse Negl* 1998; 22: 183-195.
5. Lapidus G, Cooke MB, Gelven E, Sherman K, Duncan M, Banco L. A statewide survey of domestic violence screening behaviors among pediatricians and family physicians. *Arch Pediatr Adolesc Med* 2002; 156: 332-336.
6. Aydin S, Yaris F, Sahin EM, Ozer C, Ozkomur E. Students' perceptions of their undergraduate medical education. *Saudi Med J* 2005; 26: 1484-1486.