

# Co-existence of spontaneous splenic rupture and tuberculosis of the spleen

*Michael C. Safioleas, MD, PhD, Michael C. Stamatakos, MD, Constantin M. Safioleas, MD, Ahmad I. Diab, MD, Emmanuel B. Agapitos, MD, PhD.*

---

## ABSTRACT

A rare case of splenic tuberculosis complicated by splenic rupture is reported. A 73-year-old man, hospitalized for peptic ulcer bleeding, presented in oligemic shock, was transferred to the operating room. Hemoperitoneum, due to rupture of an enlarged spleen was detected. The pathology revealed splenic tuberculosis. He had an uneventful recovery. Postoperatively, he received a combination of anti-tuberculous therapy for 6 months.

Saudi Med J 2006; Vol. 27 (10): 1588-1590

---

Tuberculosis (TB) of the spleen is a rare clinical manifestation in immunocompetent individuals,<sup>1</sup> even rarer is spontaneous splenic rupture in co-existence with TB of the spleen. Recently, we experienced a case of spontaneous splenic rupture and the pathology of the specimen after a successful splenectomy revealed splenic tuberculosis. We also reviewed the relevant literature.

**Case Report.** A 73-year-old man was transferred to the Operating Room after a syncopal episode, due to severe intraperitoneal hemorrhage. He had been hospitalized in the 2nd Department of Surgery, Laikon Hospital for upper gastrointestinal hemorrhage, due to a known peptic ulcer for the preceding 3 days. During the initial 3-day hospitalization, it was discovered that he had a history of pulmonary tuberculosis. However, no history of recent trauma could be elicited. He was tachycardic and hypotensive with diffuse abdominal tenderness and rigidity. As he was not

hemodynamically stable, it was decided to perform an urgent exploratory laparotomy without resorting to a preliminary CT scan, which in retrospect would have confirmed the right diagnosis preoperatively. He underwent an emergency laparotomy, which disclosed the presence of hemoperitoneum, and a lacerated splenic capsule with active bleeding (**Figure 1**). Approximately 1500 ml of fresh blood was evacuated from the abdominal cavity. By gross appearance, the spleen was enlarged, measuring approximately 13 x 10 x 7 cm and weighing 380g. Pathology showed tuberculosis of the spleen. He had a complete recovery. He was administered pneumococcal vaccine after discharge.

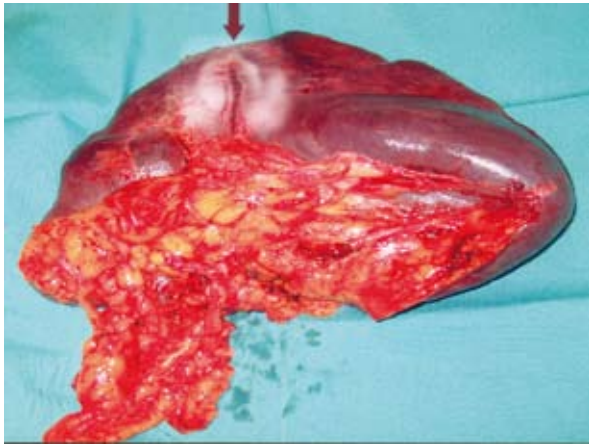
As most patients with splenic tuberculosis may have disseminated disease, although he showed no active pulmonary disease, a 6-month course of anti-tuberculosis treatment appeared to be appropriate and so he received triple therapy, namely, isoniazid and rifampicin for 6 months, and pyrazinamide for the first 2 months.

---

From the 2nd Department of Propedeutic Surgery (Safioleas M, Stamatakos, Safioleas C, Diab), and the Department of Pathology (Agapitos), School of Medicine, University of Athens, Laiko General Hospital, Athens, Greece.

Received 10th October 2005. Accepted for publication in final form 24th April 2006.

Address correspondence and reprint request to: Prof. Michael C. Safioleas, 2nd Department of Propedeutic Surgery, School of Medicine, University of Athens, Laiko General Hospital, 7 Kyprou Avenue, Filothei 152 37, Athens, Greece. E-mail: diabahmad1@yahoo.gr



**Figure 1** - The specimen shows the phymata and the linear rupture of the splenic capsule (arrow).

**Discussion.** Splenic rupture is a well-recognized sequel to blunt left lower chest or abdominal trauma, usually manifested as an acute abdomen with profuse intraperitoneal bleeding. A spontaneous rupture of the spleen is uncommonly a medical oddity with grave consequences if unrecognized and untreated. It has been suggested that the term “spontaneous” is replaced by the term “pathologic” when the ruptured spleen, even without obvious trauma, is diseased.<sup>2</sup> Moreover, the term “occult rupture” has been used also for atraumatic rupture of the spleen.<sup>3</sup> However, the term spontaneous has been often used in the literature in describing rupture of the spleen without history of blunt or penetrating trauma. Spontaneous rupture of the spleen has been described in a series of affections frequently of viral origin.<sup>4</sup> This chronic viral portage may be responsible for spleen damage followed rarely by splenic rupture. Furthermore, bacterial infections including TB, hematological malignancies, coagulation disorders, pregnancy, and tumors of the spleen may be causative factors for spontaneous splenic rupture. Although spontaneous splenic rupture is a rare clinical oddity, several articles, either as case reports or as small series, have been published in the medical literature.

Tuberculosis of the spleen is not a common complication, even in active presence of pulmonary tuberculosis.<sup>1</sup> Bhansali<sup>5</sup> reported that he did not encounter a single case of splenic tuberculosis in the series of 300 cases of abdominal tuberculosis he reviewed. Splenic involvement is possible in miliary or disseminated tuberculosis, especially in AIDS patients with extra-pulmonary tuberculosis.<sup>6-9</sup> The symptomatology of the disease is not specific, particularly in the elderly, and the presenting

symptoms usually include low-grade fever and general malaise. Splenic enlargement is the most common manifestation of the involvement of this organ.<sup>10</sup> Regarding the mechanism of the nontraumatic splenic rupture, in all possibility the subcapsular localization of granulomatous tissue of the tuberculosis infiltrates the red pulp of the spleen (hemorrhagic focus) and predisposes to tearing of the splenic capsule resulting in rupture of the spleen. Although the speed and accuracy of laboratory studies of TB have increased in recent years, by the wider use of rapid culture techniques and nucleic acid detection, these advances do not appear to have improved the diagnostic yield when the localization of TB is unusual. As the spleen is an uncommon site, the diagnosis of splenic TB is difficult. Thus, including the potential risk of spontaneous rupture, splenic TB is associated with high mortality. The favorable outcome with respect to our patient may have been influenced by the circumstances of his hospitalization, such as, prompt surgery, the availability of blood for transfusion, and finally the specialized team for such medical care. Whether postoperative medication may be required or not, is difficult to assess, but it is considered a necessary adjunct when the mesenteric lymph nodes are involved.<sup>11</sup> The patients with splenic TB treated with an effective anti-tuberculosis therapy have a good prognosis. Extra-pulmonary TB should be treated with triple therapy, namely, isoniazid, rifampicin, and pyrazinamide. The use of steroids in abdominal TB is controversial.<sup>12</sup>

In conclusion, apart from the exceptional fact of the spontaneous rupture of the spleen involved in mycobacterial disease and although there is a decline in the incidence of pulmonary tuberculosis, the possibility of splenic TB should be kept in mind when attempting a differential diagnosis.

## References

1. Bastounis E, Pikoulis E, Varelas P, Cirochristos D, Aessopos A. Tuberculoma of the spleen: a rare but important clinical entity. *Am Surg* 1999; 65: 131-132.
2. Debnath D, Valerio S. A traumatic rupture of the spleen in adults. *J R Coll Surg Edinb* 2002; 47: 437-445.
3. McMahon MJ, Lintott JD, Mair WSJ, Lee PWR, Duthie JS. Occult rupture of the spleen. *Br J Surg* 1997; 64: 641-643.
4. Barrier JH, Bani-Sadr F, Gaillard F, Raffi F. Spontaneous rupture of the spleen revealing primary human immunodeficiency virus infection. *Clin Infect Dis* 1997; 25: 336-337.
5. Bhansali SK. Abdominal tuberculosis. Experience with 300 cases. *Am J Gastroenterol* 1997; 67: 324-337.
6. Siavin RE, Walsh TJ, Pollack AD. Late generalized tuberculosis: a clinical pathologic analysis and comparison of 100 cases in the preantibiotic and antibiotic era. *Medicine (Baltimore)* 1980; 59: 352-366.

7. Gonzalez-Lopez A, Drona F, Alonso-Sariz M, Chaves F. Clinical significance of splenic tuberculosis in patients infected with human immunodeficiency virus. *Clin Infect Dis* 1997; 24: 1248-1251.
8. Pedro-Botet J, Maristany MT, Miralles R, Lopez-Collomes JL, Rubies-Prat J. Splenic tuberculosis in patients with AIDS. *Rev Infect Dis* 1991; 13: 1069-1071.
9. Wolff MJ, Bitran J, Novthaland RG, Levy IL. Splenic abscesses due to Mycobacterium tuberculosis in patients with AIDS. *Rev Infect Dis* 1991; 13: 373-375.
10. Lundstedt C, Nyman R, Brismar R. Imaging of tuberculosis. II. Abdominal manifestations in 112 patients. *Acta Radiol* 1996; 37: 489-495.
11. Agarwala S, Bhatnagar V, Mitra DK. Primary tubercular abscess of the spleen. *J Pediatr Surg* 1992; 27: 1580-1581.
12. Dooley DP, Carpenter JL, Rademacher S. Adjunctive corticosteroid therapy for tuberculosis: a critical re-appraisal of the literature. *Clin Infect Dis* 1997; 25: 872-887.