

# Fate of bulk autografts in uncemented total hip arthroplasty

## *Evaluation by bone scintigraphy*

Aykin Simsek, MD, Erdal Cila, MD, Ertugrul Sener, MD, Alpaslan Senkoylu, MD, Serkan Sipahioglu, MD, Ozgur Akdemir, MD, Tamer Atasever, MD.

---

### ABSTRACT

**Objective:** To review short term results of uncemented cup implantation and the fate of bulk femoral head autografts in patients with acetabular bone deficiency due to dysplasia of the hip. We used bone scintigraphy to assess the viability of the grafts.

**Methods:** We treated 19 hip joints of 17 patients with osteoarthritis due to developmental dysplasia of the hip with uncemented total hip arthroplasty between 1997-2003 in the Department of Orthopedics and Traumatology, Gazi University, Ankara, Turkey. The average age was 49.1 (31-72 years), and the average follow up period was 36 months. We used femoral head autografts to reconstruct superolateral segmental deficiencies of the acetabuli. We evaluated the patients clinically and radiologically to assess acetabular loosening, and we used three-phase bone scintigraphy to evaluate the viability of the autograft.

**Results:** There was no acetabular component revision throughout the follow up period. There was no radiological evidence of graft resorption or graft displacement in any of the patients. In bone scintigraphy, we observed hyperemia in the blood pool phase, and the osteoblastic activity of the bone graft was at the level of the neighboring iliac bone.

**Conclusion:** The application of a non-cemented acetabular component with femoral autograft in superolateral acetabulum deficiency increases the stability of the implant and increases the bone stock. It is not easy to evaluate the viability of the graft by the use of radiological methods. Bone scintigraphy gives sufficient information about the viability of the graft as a non-invasive method.

Saudi Med J 2006; Vol. 27 (12): 1835-1838

---

Total hip arthroplasty in patients with developmental dysplasia of the hip (DDH) is a difficult procedure for orthopedic surgeons. A severe deficiency in the anterolateral acetabular bone stock impairs adequate coverage and stable fixation of the acetabular component. Various techniques have been described for reconstruction of the deficient acetabulum, including the method of reconstruction by placing the socket in the true acetabulum and

augmenting the superolateral aspect of the ilium with a bulk femoral head autograft, as advocated by Harris and Crothers.<sup>1-8</sup> Cemented or cementless acetabular components may be implanted with this technique. Early results of cemented cups augmented with bone grafting of acetabular deficiencies have been encouraging, with high rates of graft incorporation. With longer follow-up, however, increasing rates of graft resorption, collapse and acetabular loosening

---

From the Department of Orthopedics and Traumatology (Simsek, Cila, Sener, Senkoylu, Sipahioglu), Department of Nuclear Medicine (Atasever), Gazi University Medical Faculty Besevler, and the Department of Nuclear Medicine (Akdemir), Positron Nuclear Medicine Center, Siihiye, Ankara, Turkey.

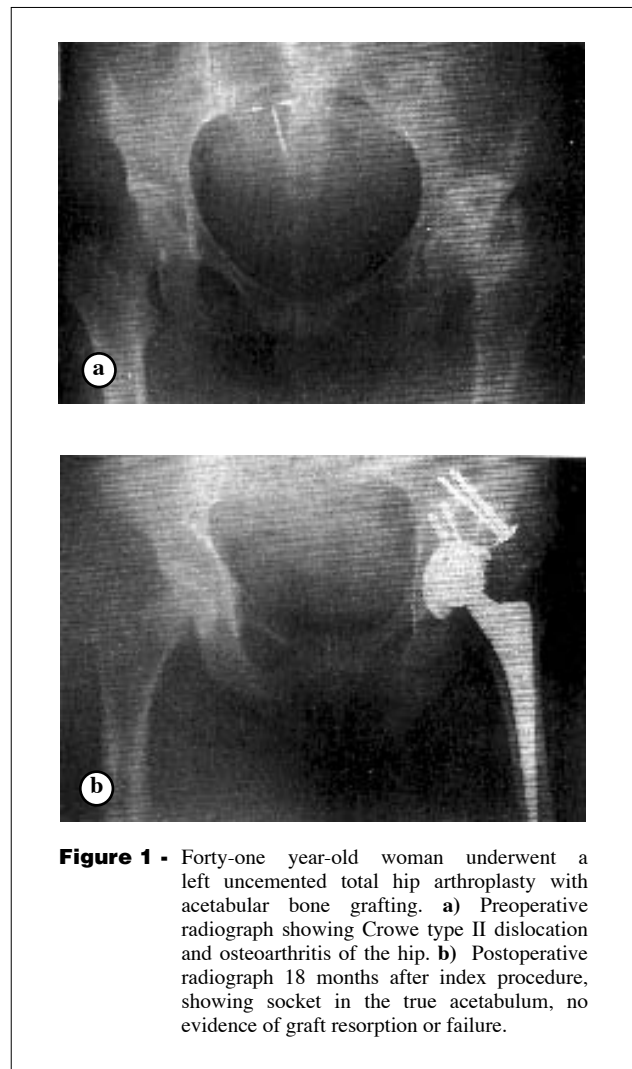
Received 18th March 2006. Accepted for publication in final form 27th August 2006.

Address correspondence and reprint request to: Dr. Aykin Simsek, Associate Professor of Orthopedics and Traumatology, Gazi University Medical Faculty, Department of Orthopaedics and Traumatology, Besevler, Ankara 06500, Turkey. Tel. +90 (312) 2025502. Fax. +90 (312) 2129008. E-mail: ayk@gazi.edu.tr

are of concern.<sup>9-12</sup> We know little about the durability of uncemented cups, and the fate of bulk femoral head autografts used for reconstruction of acetabular deficiencies in patients with DDH. The most common method for assessing the fate of the autografts used in this method has been conventional radiograms. However, they have been unreliable because of the difficulty in accurately visualizing the complex geometry of the pelvis-graft interface. A definite method for proving the vitality of the graft would be obtaining a biopsy, however, its impracticality limits this method.<sup>13</sup> Radionuclide imaging is a more reliable technique compared with conventional radiology for assessing the graft.<sup>14,15</sup> The purpose of this study is to review short term results of uncemented cup implantation and the fate of bulk femoral head autografts in patients with acetabular bone deficiency due to DDH. For this purpose, we used bone scintigraphy to assess the viability of the grafts.

**Methods.** We treated 19 hips of 17 patients with degenerative joint disease secondary to DDH with total hip arthroplasty between 1997-2003 in the Department of Orthopaedics and Traumatology, Gazi University, Ankara, Turkey. We did not include patients with primary osteoarthritis and secondary arthritis due to reasons other than the DDH in this study. Twelve of the 17 patients were female and 5 were male. The average age at the time of the index arthroplasty was 49.1 (range, 31-72). The mean duration of clinical and radiographic follow-up was 36 months (range, 24-96 months). None of the hips had been operated previously. We classified preoperative radiographs according to the classification system of Crowe et al.<sup>16</sup> None of the hips were in group I; 3 (18%) were in group II; 9 (53%) were in group III, and 5 (29%) were in group IV. We used the uncemented technique to fix all the acetabular components (**Figures 1a & 1b**). The implanted hemispherical acetabular components with roughened surfaces (Sulzer Medica, Switzerland) had an average 48 mm (range, 46-52) outside diameter, and were matched with 28 mm femoral heads. Superolateral segmental deficiencies of the acetabuli, which would leave more than 1.5 cm of the socket uncovered, were reconstructed with ipsilateral femoral head autografts, as proposed by Spangehl et al.<sup>17</sup> We screwed the autografts to the pelvis prior to final reaming and filled the interface between the grafts and host bone with morselized grafts to enhance union. We used the press-fit technique to insert the acetabular sockets, and fixed these to the host bone with 2 screws. We clinically evaluated the patients one year after the index procedure, and obtained radiograms to assess the acetabular cups for loosening.

We also used the radiograms to assess visible signs of graft resorption and collapse, according to the criteria of Gerber and Harris.<sup>9</sup> Again, one year after the arthroplasty, we performed scintigraphic imaging after obtaining informed consents from the patients. We obtained dynamic blood flow, blood pool and delayed static anterior and posterior views of pelvises after intravenous injection of 740 MBq Tc-99m-methylene diphosphonate (MDP). We used a dual-head gamma camera with high-resolution collimators (Maxxus, GE Medical Systems, Milwaukee-USA) to acquire all the images, and obtained delayed static images 3 hours after the injection and in a preset time of 10-minutes. Two experienced nuclear medicine physicians, blinded to the clinical status of the patients, assessed the images visually. We considered the presence of hyperemia on blood pool images and/or radioactivity uptake equal to or greater than the adjacent iliac bone in the acetabular area corresponding to the autograft



**Figure 1** - Forty-one year-old woman underwent a left uncemented total hip arthroplasty with acetabular bone grafting. **a)** Preoperative radiograph showing Crowe type II dislocation and osteoarthritis of the hip. **b)** Postoperative radiograph 18 months after index procedure, showing socket in the true acetabulum, no evidence of graft resorption or failure.

positive for the patency of anastomosis and the viability of the graft.

**Results.** Clinical evaluation demonstrated a marked decrease in pain and improvement in function following total hip replacement. All patients but one had excellent clinical results without hip pain. One patient suffered from symptomatic deep-vein thrombosis and superficial wound infection and was treated conservatively. Four of the 17 patients had a limb-length discrepancy of more than 15 millimeters. Harris hip score demonstrated a significant change compared with the preoperative status. The average preoperative status was 53 (range 48-66), while the average postoperative score was 87 (range 67-96). At the final radiographic follow-up, none of the cups showed evidence of probable or definite signs of loosening as radiolucent signs  $\geq 2$  mm in any zones. All of the grafts were seen to be united with the host bone, without collapse or discernible bone resorption. However, 3 patients had minor resorption adjacent to washers and screw heads used to secure the graft to host bone and were considered as inconsequential as they were in the lateral unstressed areas of the grafts. Scintigraphic examination demonstrated that all of the hips presented hyperemia on blood pool images and/or osteoblastic activity on the bone phase images in the acetabular area. We interpreted this as viability of the grafts and progression of angiogenesis into the grafts.

**Discussion.** Anterolateral acetabular bone deficiency is a technical problem that we must deal with when we use total hip arthroplasty to treat DDH. We can use bulk femoral autografts, or bone deficiencies of varying severity in order to provide additional anterolateral support for the socket and augmentation of bone stock.<sup>13,18-20</sup> Studies report variable results with cemented sockets with autologous femoral head bone grafts for the treatment of DDH.<sup>10,21-24</sup> Harris and Crothers advocated this procedure, however, the prevalence of aseptic loosening of the socket in their patients increased substantially with longer follow up. Although early results are favorable, the results deteriorate because of socket loosening and graft collapse in the long term. Gerber and Harris<sup>9</sup> reported loosening and a revision rate of 21% at 7.1 years follow up; Mulroy and Harris<sup>11</sup> reported that failure rate had increased to 46% at 11.8 years follow up. Lee et al<sup>10</sup> found that the rate of mechanical failure increased from 6% at 5 years to 39% at 10 years. However, Inao et al<sup>21</sup> found that no revision in the 20 cups followed for 5.2 to 12.9 years after reconstruction with a graft. The amount

of resorption of the graft with time also varied in series of cemented sockets.<sup>13</sup> However, even as they reported high rates of failure with time, most authors agree that autografts contribute valuable pelvic bone stock that facilitates subsequent revision. There are limited reports of uncemented sockets in combination with autogenous bone grafts for the treatment of secondary osteoarthritis due to acetabular deficiency. Uncemented sockets in combination with autogenous femoral head grafts provided good acetabular fixation in developmental hip dysplasia patients in our study at 18.5 months follow-up. Barrack and Newland<sup>2</sup> noted no failures in 10 hips within 3 years. Anderson and Harris<sup>1</sup> reported that, of the 20 dysplastic hips followed for at least 5 years after reconstruction with use of an uncemented cup, none had mechanical failure. Morsi et al<sup>25</sup> had to revise only one in 17 hips at a mean follow up of 6.6 years related with and uncemented cups and autogenous grafts.<sup>25</sup> When implanting uncemented cups into acetabuli reconstructed with autogenous grafts, we were concerned for the lack of primary stability provided by the use of cement. This might have caused fixation problems for the cup and have an adverse effect on the graft by exerting large forces on the graft and cause complications. In this study, clinical results in terms of pain and functional status and radiological findings were favorable in the short-term period. The autografts provided good augmentation for the structure of the pelvic bone. This is important as most of these patients are young and active, they may require additional hip operations in the future, and having a bone stock meeting those demands is an advantage. We did not observe graft failure with radiological examination in this study. However, it is difficult to determine graft union and resorption only with anteroposterior radiographs as they only provide a 2-dimensional representation of a 3-dimensional reconstruction. Conventional roentgenograms proved unreliable in evaluating bone graft reconstitution because of overlapping trabecular bone patterns of the graft and iliac wing, making an accurate assessment difficult. Bone scintigraphy offers dynamic physiologic monitoring of the incorporation process; whereas a roentgenogram of a bone graft may appear united even when avascular necrosis or lack of bony union has occurred. In this study, we presented a non-invasive way of addressing the fate of bulk autografts. Bone scintigraphy has been used for diagnosing bone lesions, following new bone formation and metabolic diseases with an incredibly safe margin. The most commonly used agent for these purposes has been <sup>99m</sup>Tc-MDP. The diphosphonate agents concentrate in the mineral phase of bone with particular affinity for sites of new bone formation. It is

thought that diphosphonate uptake on bone, primarily reflects osteoblastic activity, but it is also dependent on skeletal vascularity.<sup>14</sup> Thus, bone scintigraphy provides a functional display of skeletal activity, vascularity of bone, and new bone formation.<sup>15,17</sup> In our study, bone scintigraphy demonstrated a significant amount of radioactivity accumulation, which is an indicator of bone remodeling and revascularization of the autograft. With this knowledge, we judged that bone scintigraphy with <sup>99m</sup>Tc-MDP would be a good choice for evaluation of the viability of the femoral head autograft.

In conclusion, we observed good short-term results after use of an uncemented porous-coated socket fixed with screws in conjunction with a bulk femoral head autograft at the true anatomical acetabular level. The autografts used for reconstruction of the acetabuli united with the host bone, as demonstrated by bone scintigraphy, which is a useful and non invasive method for this purpose.

## References

- Anderson MJ, Harris WH. Total hip arthroplasty with insertion of the acetabular component without cement in hips with total congenital dislocation or marked congenital dysplasia. *J Bone Joint Surg* 1999; 81: 347-354.
- Barrack RL, Newland CC. Uncemented total hip arthroplasty with superior acetabular deficiency. Femoral head autograft technique and early clinical results. *J Arthroplasty* 1999; 5:159-167.
- Dorr LD, Tawakkol S, Moorthy M, Long W, Wan Z. Medial protrusion technique for placement of a porous-coated, hemispherical acetabular component without cement in a total hip arthroplasty in patients who have acetabular dysplasia. *J Bone Joint Surg* 1999; 81: 83-92.
- Gross AE, Allan DG, Catre M, Garbuz DS, Stockley I. Bone grafts in hip replacement surgery. The pelvic side. *Orthop Clin North Am* 1993; 24: 679-695.
- Harris WH, Crothers O, Oh I. Total hip replacement and femoral-head bone-grafting for severe acetabular deficiency in adults. *J Bone Joint Surg* 1977; 59: 752-759.
- Kobayashi S, Saito N, Nawata M, Horiuchi H, Iorio R, Takaoka K. Total hip arthroplasty with bulk femoral head autograft for acetabular reconstruction in DDH. *J Bone Joint Surg* 2003; 85: 615-620.
- Kobayashi S, Saito N, Nawata M, Horiuchi H, Iorio R, Takaoka K. Total hip arthroplasty with bulk femoral head autograft for acetabular reconstruction in DDH. Surgical technique. *J Bone Joint Surg* 2004; 86: 11-17.
- McQueary FG, Johnston RC. Coxarthrosis after congenital dysplasia. Treatment by total hip arthroplasty without acetabular bone-grafting. *J Bone Joint Surg* 1988; 70: 1140-1144.
- Gerber SD, Harris WH. Femoral head autografting to augment acetabular deficiency in patients requiring total hip replacement. A minimum five-year and an average seven-year follow-up study. *J Bone Joint Surg* 1988; 68: 1241-1248.
- Lee BP, Cabanela ME, Wallrichs SL, Ilstrup DM. Bone-graft augmentation for acetabular deficiencies in total hip arthroplasty. Results of long-term follow-up evaluation. *J Arthroplasty* 1977; 12: 503-510.
- Mulroy RD Jr, Harris WH. Failure of acetabular autogenous grafts in total hip arthroplasty. Increasing incidence: a follow-up note. *J Bone Joint Surg* 1990; 72: 1536-1540.
- Shinar A, Harris WH. Bulk structural autogenous grafts and allografts for reconstruction of the acetabulum in total hip arthroplasty. *J Bone Joint Surg* 1997; 79: 159-168.
- Shetty AA, Sharma P, Singh S, Tindall A, Kumar SV, Rand C. Bulk femoral-head autografting in uncemented total hip arthroplasty for acetabular dysplasia. Results at eight to eleven years follow-up. *J Arthroplasty* 2004; 19: 706-713.
- Gordon SL, Binkert BL, Rashkoff ES, Britt AR, Esser PD, Stinchfield FE. Assessment of bone grafts used for acetabular augmentation in total hip arthroplasty. A study using roentgenograms and bone scintigraphy. *Clin Orthop* 1985; 201: 18-25.
- Wilson M. Musculoskeletal System. In: Wilson M, editor. Textbook of nuclear medicine. Philadelphia: Lippincott-Raven; 1998.
- Crowe JF, Mani VJ, Ranawat CS. Total hip replacement in congenital dislocation and dysplasia of the hip. *J Bone Joint Surg* 1979; 61:15-23.
- Spanghel MJ, Berry DJ, Trousdale RT, Cabanela ME. Uncemented acetabular components with bulk femoral head autograft for acetabular reconstruction in developmental dysplasia of the hip: results at five to twelve years. *J Bone Joint Surg* 2001; 83:1484-1489.
- Gross AE, Catre MG. The use of femoral head autograft shelf reconstruction and cemented acetabular components in the dysplastic hip. *Clin Orthop* 1994; 298: 60-66.
- Hartofilakidis G, Stamos K, Karachalios T, Ioannidis TT, Zacharakis N. Congenital hip disease in adults. Classification of acetabular deficiencies and operative treatment with acetabuloplasty combined with total hip arthroplasty. *J Bone Joint Surg* 1996; 78: 683-692.
- Trancik TM, Stulberg BN, Wilde AH, Feiglin DH. Allograft reconstruction of the acetabulum during revision total hip arthroplasty. Clinical, radiographic and scintigraphic assessment of the results. *J Bone Joint Surg* 1986; 68: 527-533.
- Inao S, Gotoh E, Ando M. Total hip replacement using femoral neck bone to graft the dysplastic acetabulum. Follow-up study of 18 patients with old congenital dislocation of the hip. *J Bone Joint Surg* 1994; 76: 735-739.
- Pagnano W, Hanssen AD, Lewallen DG, Shaughnessy WJ. The effect of superior placement of the acetabular component on the rate of loosening after total hip arthroplasty. *J Bone Joint Surg* 1996; 78: 1004-1014.
- Rodriguez JA, Huk OL, Pellicci PM, Wilson PD Jr. Autogenous bone grafts from the femoral head for the treatment of acetabular deficiency in primary total hip arthroplasty with cement. Long-term results. *J Bone Joint Surg* 1995; 77: 1227-1233.
- Russotti GM, Harris WH. Proximal placement of the acetabular component in total hip arthroplasty. A long-term follow-up study. *J Bone Joint Surg* 1991; 73: 587-592.
- Morsi E, Garbuz D, Gross AE. Total hip arthroplasty with shelf grafts using uncemented cups. A long-term follow-up study. *J Arthroplasty* 1996; 11: 81-85.