

## Brief Communication

### Multiple daily insulin regimen using insulin glargine in type 1 diabetic Saudi children

Bassam S. Bin-Abbas, MD, Abdulmoein E. Al-Agha, MD,  
Nadia A. Sakati, MD, Abdullah A. Al-Ashwal, MD.

Glargine (Lantus®) is a recently approved, long acting insulin analog that is increasingly being used in children with diabetes. It has no pronounced peak, and lasts for 24 hours, which allows once-daily administration as basal insulin. Several studies showed that glargine-based multiple daily insulin (MDI) therapy can reduce nocturnal hypoglycemia and improve hemoglobin A1c (HbA<sub>1c</sub>) without jeopardizing the glycemic control.<sup>1-3</sup> The aim of this study was to assess the effectiveness and feasibility of MDI in type 1 diabetic Saudi children, and to compare it with conventional insulin (CI) therapy.

Ten Saudi children (7 male, 3 female) with type 1 diabetes mellitus were selected and started on glargine-based MDI therapy. Selection criteria included diabetic children with poor diabetic control (HbA<sub>1c</sub> above 8.5%) who had recurrent daytime and nocturnal hypoglycemic episodes (more than 8 episodes per month). These patients were willing to monitor blood glucose regularly and frequently, motivated to improve blood glucose control, willing to quantify food intake and count carbohydrates. They had adequate family support and were interested in preventing short and long-term diabetic complications. All patients were followed at The Diabetes Clinics at King Faisal Specialist Hospital and Research Center and King Abdul-Aziz University School of Medicine. All patients were on CI therapy that included 2 injections of insulin per day; neutral protamine Hagedorn (NPH) (intermediate-acting) and regular (short-acting) insulin before shifting them to MDI. All patients were trained by a diabetic dietitian on carbohydrate counting and food nutrition label reading. Fifty percent of their total caloric intake was from carbohydrates. Total daily carbohydrate intake calculated as grams of carbohydrates were distributed into 3 meals and 3 snacks. The glargine dose was initially calculated as 50% of the total pre-MDI dose. One unit of lispro insulin was required to cover for 10-15 grams of carbohydrates (meal insulin bolus). Additional lispro insulin doses for high blood glucose correction were required. One unit of lispro insulin was needed to correct for 50-100 mg/dl above 120 mg/dl (correction insulin bolus). All patients were initially instructed to check blood glucose 8 times per day; pre and post-meals, at bedtime and in the early morning

for the first few days of MDI initiation, and then 5 times of blood glucose monitoring were required. All children were told to fax their blood glucose record sheet to the health care team or phone for consultation whenever having difficulties in controlling blood glucose levels. All children had weekly clinic visits, and every 2 months HbA<sub>1c</sub> monitoring. Statistical analyses were performed using the paired comparison t-test to evaluate the differences between MDI and CI treatment levels of HbA<sub>1c</sub>, blood glucose levels, and hypoglycemic episode rate. The tests were 2-tailed, and *p*-value of <0.05 was chosen to indicate significant deviation from the null hypothesis. All patients had type 1 diabetes mellitus for a mean duration of 6 years (range from 2-8 years). The age of the children ranged from 8-14 years (mean 12.8). They were followed on MDI therapy for a mean duration of 8 months (range from 6-9 months). All children had normal thyroid function tests, anti-celiac disease antibodies, urine microalbumin and lipid profile. During the 6 months prior to MDI therapy initiation and on CI therapy, the mean hemoglobin A1c was 10.6 ± 1.2% (range from 9-13.1%), the mean blood glucose level was 251 ± 39 mg/dl (range from 171-320 mg/dl), the frequency of hypoglycemic episodes (defined as a blood glucose level of 40 mg/dl or less) ranged from 8-12 episodes per month (mean 8.8 ± 1.1). There were no reports of hypoglycemic convulsive or diabetic ketoacidosis (DKA) episodes (Table 1). Post MDI therapy, the mean hemoglobin A1c was 8.6 ± 0.7% (range from 8-9.2%), the mean blood glucose level was 174 ± 32 mg/dl (range from 124-222 mg/dl) and the frequency of hypoglycemic episodes ranged from 2-5 per month (mean 3 ± 0.6). The HbA<sub>1c</sub> level improved significantly during MDI treatment in the study group (*p*<0.001). Mean blood glucose level was significantly lower during MDI compared with CI therapy (*p*<0.001). A significant decrease in the frequency of hypoglycemic episodes was observed (*p*<0.001). There was no significant difference in body mass index (BMI) pre and post MDI therapy. There were no reports of hypoglycemic convulsion or coma or DKA in children on MDI regimen. A tremendous amount of data suggests that near-normal glycemic control prevents or delays complications of diabetes, which has led to dramatic increase in use of different modalities of intensive insulin therapy such as insulin pump therapy or MDI regimen.<sup>1-3</sup> However, the number of Saudi children on MDI therapy is still small. Lack of patient and family motivation and health care team enthusiasm are among the contributing factors for that. This article reports our experience with 10 Saudi children on MDI therapy that proves that this modality of intensive insulin therapy is

**Table 1** - Reported HbA<sub>1c</sub>, blood glucose level, rate of hypoglycemic episodes before and after the MDI.

Patients	Pre MDI			Post MDI		
	Mean HbA <sub>1c</sub> (%)	Mean blood glucose level (mg/dl)	Rate of hypoglycemic episode/month	Mean HbA <sub>1c</sub> (%)	Mean blood glucose level (mg/dl)	Rate of hypoglycemic episodes/month
1	(9)	201	8	(8)	176	4
2	(8.8)	171	8	(8)	143	2
3	(11)	259	9	(9.2)	188	5
4	(12.1)	276	8	(9.1)	222	3
5	(10)	245	10	(8.8)	189	3
6	(9.5)	201	8	(8.1)	188	4
7	(11.1)	261	12	(8.9)	177	2
8	(12)	301	9	(9.1)	156	2
9	(13.1)	320	8	(8.3)	184	3
10	(9.3)	279	8	(8.2)	124	2
Mean	(10.6)	251	8.8	(8.6)	174	3
SD	(1.5)	47.5	1.3	(0.5)	27.5	1.1

MDI - multiple daily insulin, HbA<sub>1c</sub> - hemoglobin A<sub>1c</sub>

extremely effective in treating type 1 diabetic Saudi children. Family and psychosocial support is needed for this modality of insulin therapy to succeed. Intensive diabetes management with MDI provides better glycemic control than CI therapy. In our group of children, although it is small, the blood glucose level, blood glucose variability, the HbA<sub>1c</sub> level and the rate of hypoglycemic episodes are significantly improved. In a multicenter, open-label, randomized study involving 349 children with type 1 diabetes, fasting blood glucose decreased significantly in the insulin glargine group of children and the incidence of severe hypoglycemia and nocturnal hypoglycemia was less compared with the NPH group.<sup>4</sup>

Hypoglycemia is a serious risk associated with intensive therapy. Early studies suggested that the risk of hypoglycemia with insulin pump therapy was greater or similar to that of conventional diabetes management.<sup>5</sup> More recently, however, reports have suggested that severe hypoglycemia may be reduced by MDI with no reduction in glycemic control.<sup>1,3</sup> Reduced frequency of daytime and nocturnal hypoglycemia was observed in our patients on MDI therapy and none of them developed hypoglycemic coma or convulsion. The effectiveness of intensive insulin therapy including MDI appears to decrease with a decreased frequency of blood glucose self-monitoring (BGSM) and insulin dose adjustment.<sup>6</sup> Our patients were instructed to check their blood sugar at least 8 times per day, and the majority of them were checking their blood sugar more than 10 times per day. The favorable results achieved in this study may have been promoted by high frequency of BGSM. The most common metabolic adverse effect of improved glycemic control is weight gain.

Participants in the diabetes control and complication trial who used intensive management gained approximately 4.5 kg more than the conventional treatment group.<sup>5</sup> Our MDI patients were instructed not to exceed the recommended total caloric intake per day to avoid excessive weight gain. There was no significant change in BMI in the studied children pre and post MDI therapy. Meal boluses for carbohydrate coverage ranged from one unit of Lispro insulin for every 10-15 grams of carbohydrates. Younger children required less insulin to carbohydrate ratio coverage (1 unit to 15 grams carbohydrates) and older children required higher doses (1 unit to 10 grams carbohydrates). One of the advantages of MDI therapy that provides eating flexibility. Children can eat freely and cover what they ate with lispro insulin. This advantage can be misused and lead to overeating and weight gain. One of the advantages of lispro insulin is that it can be given after meals especially in young children in whom their eating habit is inconsistent.<sup>7</sup> The present study showed that MDI therapy is effective in improving the metabolic control in type 1 diabetic Saudi children. The results of this local experiment are encouraging to implement this mode of intensive insulin therapy in all candidate diabetic Saudi children.

Received 19th March 2005. Accepted for publication in final form 23rd October 2005.

From the Department of Pediatrics (Bin-Abbas, Sakati, Al-Ashwal), King Faisal Specialist Hospital and Research Center and the Department of Pediatrics (Al-Agha), King Abdul-Aziz University School of Medicine, Kingdom of Saudi Arabia. Address correspondence and reprint requests to Dr. Bassam S. Bin-Abbas, Section of Pediatric Endocrinology, Department of Pediatrics, MBC 58, King Faisal Specialist Hospital and Research Center, PO Box 3354, Riyadh 11211, Kingdom of Saudi Arabia. Tel. +966 (1) 4427763. Fax. +966 (1) 4427784. E-mail: benabbas@kfshrc.edu.sa

## References

1. Chase HP, Dixon B, Pearson J, Fiallo-Scharer R, Walravens P, Klingensmith G, et al. Reduced hypoglycemic episodes and improved glycemic control in children with type 1 diabetes using insulin glargine and neutral protamine hagedorn insulin. *J Pediatr* 2003; 143: 737-740.
2. Tan CY, Wilson DM, Buckingham B. Initiation of insulin glargine in children and adolescents with type 1 diabetes. *Pediatr Diabetes* 2004; 5: 80-86.
3. Jackson A, Ternand C, Brunzell C, Kleinschmidt T, Dew D, Milla C, et al. Insulin glargine improves hemoglobin A1c in children and adolescents with poorly controlled type 1 diabetes. *Pediatr Diabetes* 2003; 4: 64-69.
4. Schober E, Schoenle E, Van Dyk J, Wernicke-Panten K; Pediatric Study Group of Insulin Glargine. *J Pediatr Endocrinol Metab* 2002; 15: 369-376.
5. Diabetes Control and Complication Trial Research Group. Implementation of treatment protocols in the Diabetes Control and Complication Trials. *Diabetes Care* 1995; 18: 361-376.
6. Schiffrin A, Belmonte M. Multiple daily self-glucose monitoring: its essential role in long-term glucose control in insulin-dependent diabetic patients treated with pump and multiple subcutaneous injections. *Diabetes Care* 1982; 5: 479-484.
7. Heller S. Insulin lispro: a useful advance in insulin therapy. *Expert Opin Pharmacother* 2003; 4: 1407-1416.

---

## Evidence that curcuma longa possesses an active hypolipidemic effects in rabbits

*Nabil A. Khouri, MD, PhD.*

Hyperlipidemia comprises common metabolic disorders of plasma lipoproteins, which are often associated with an increased risk of atherosclerosis and vascular diseases. The increased interest in atherosclerosis prevention and the identification of hyperlipidemia as a risk factor for ischemic heart disease, has stimulated interesting studies with a focus in blocking atherosclerosis pathology. In the last 2 decades, both retrospective and prospective studies have shown a strong correlation between levels of circulating lipids and mortality rates from coronary atherosclerotic heart diseases. Synthetic drugs used as antihyperlipidemic agents showed serious side effects. Therefore, attention was directed to the ayurvedic medicine to find out drugs with hypolipidemic activity that could reduce the unwanted side effects. Preliminary studies in rats in our laboratory showed that curcuma longa [50% ethyl alcohol (EtOH)] extract possesses a lipid lowering

action. This encouraged us to undertake a systematic study of the hypolipidemic effects of curcuma longa (50% EtOH) extract in cholesterol fed rabbits. Curcuma longa, a perennial herb, is a member of the zingiberaceae (ginger) family. This plant grows to a height of 3-5 feet, and is cultivated extensively mainly in Asia, India, China, as well as other countries with a tropical climate. It has oblong, pointed leaves and bears funnel-shaped yellow flowers. The rhizome is the portion of the plant used medicinally. This portion of the plant is usually cleaned, boiled, dried, and minced, yielding a yellow powder. Dried curcuma longa powder is the source of the spice turmeric, this ingredient gives curry powder its characteristic yellow color, which is used extensively in food to give both flavor and color. Turmeric has a long tradition use in Chinese and Ayurvedic medicine, particularly as an anti-inflammatory agent, and for its therapeutic effects in flatulence, jaundice, menstrual difficulties, hematuria, hemorrhage, and colic. Turmeric can also be applied topically in poultices to relieve pain and inflammation. Current research has focused on turmeric's use as an antioxidant, hepatoprotective, anti-inflammatory, anticarcinogenic, and antimicrobial agent. In addition, its use in cardiovascular diseases and gastrointestinal disorders has gained vast interest in research. The active principle of curcuma longa is curcumin (diferuloyl methane).

Adult healthy albino rabbits weighing 1.6-1.7 kg were housed individually in metallic cages in an air-conditioned room ( $26 \pm 2^\circ\text{C}$ ) and were fed control diet (standard pellets). This diet was supplemented with green leafy vegetables and water ad libitum. The average consumption of diet for rabbits was calculated as 200 g/day/rabbit. A fresh curcuma longa rhizome was obtained from a local market and was dried and minced. The "powered" was extracted in 50% ethanol in a soxhlet. Ethanol was removed to get the brown solid compound used in this experiment. An atherogenic diet was prepared by mixing wheat flour, milk powder and dried egg yolk. Hydrogenated fat, butter, sodium chloride, and vitamins were added in the given proportion. In addition to the atherogenic diet, rabbits were fed with cholesterol (400 mg/kg body weight/ day), which was dissolved in 5 ml coconut oil. The plant extract was dissolved in distilled water that was orally administered to the animals at a dose of 1.2 g/kg body weight/day. During the experiment, blood serum was collected and analyzed for lipid profile. The rabbits were divided in the following groups containing 6 animals each. Group A - control vehicle (5 ml distilled water) (120 days). Group B - atherodiet + cholesterol feeding (120 days, 400 mg cholesterol/kg body weight/day in

## Hypolipidemia effect of curcuma longa

**Table 1** - Change in tissue and serum analysis lipids after cholesterol/curcuma longa (50% EtOH) extract feeding in rabbits (6 animals per treatment).

Serum analysis	Treatment			
	Group A	Group B	Group C	Group D
<b>Cholesterol</b>				
Liver (g)	10.6 ± 0.12	16.1 ± 0.32 <sup>c</sup>	11.1 ± 0.5 <sup>c</sup>	10.8 ± 0.1 <sup>c</sup>
Heart (g)	6.9 ± 0.20	8.7 ± 0.20 <sup>c</sup>	10.9 ± 0.5 <sup>c</sup>	8.6 ± 0.4 <sup>c</sup>
Serum total cholesterol (mg/dl)	98.2 ± 7.0	940.7 ± 210.3 <sup>c</sup>	230.4 ± 50.10 <sup>b</sup>	119.2 ± 21.78 <sup>c</sup>
<b>Triglycerides</b>				
Liver (g)	3.7 ± 0.03	5.4 ± 0.10 <sup>c</sup>	5.4 ± 0.12 <sup>b</sup>	4.1 ± 0.312 <sup>c</sup>
Heart (g)	4.2 ± 0.12	12.9 ± 0.12 <sup>c</sup>	4.5 ± 0.67 <sup>d</sup>	4.12 ± 0.03 <sup>c</sup>
Serum triglycerides (mg/dl)	64.1 ± 5.2	326.4 ± 24.2 <sup>c</sup>	109.3 ± 30.1 <sup>c</sup>	86.6 ± 11.21 <sup>c</sup>
<b>Phospholipids</b>				
Liver (mg/g)	7.9 ± 0.20	12.9 ± 0.12 <sup>c</sup>	9.78 ± 0.35 <sup>c</sup>	8.7 ± 6.05 <sup>c</sup>
Heart muscles (mg/g)	9.9 ± 0.07	10.8 ± 0.02 <sup>c</sup>	9.12 ± 0.01 <sup>c</sup>	8.7 ± 0.02 <sup>c</sup>
Serum phospholipids (mg/dl)	170.2 ± 11.9	425.1 ± 79 <sup>c</sup>	209.4 ± 43.2 <sup>b</sup>	120.7 ± 18.7 <sup>c</sup>
Serum HDL cholesterol (mg/dl)	35.5 ± 3.36	235 ± 12 <sup>c</sup>	60.1 ± 2 <sup>c</sup>	36.71 ± 1.2 <sup>c</sup>

<sup>b</sup> $p \leq 0.01$ , <sup>c</sup> $p \leq 0.001$ , <sup>d</sup>not-significant, group B-compared with group A, group C-compared with group B, group D-compared with group B, HDL - high-density lipoprotein

5 ml coconut oil). Group C - atherodiet + cholesterol feeding (120 days, atherodiet withdrawn + high concentration curcuma longa (5% EtOH) extract, dose of 1.2 g/kg body weight/day (120-150 days). Group D - atherodiet + cholesterol feeding (120 days, atherodiet withdrawn + curcuma longa (50% EtOH) extract, dose of 1.2 g/kg body weight/day (120-180 days). All the animals were sacrificed, and the heart and the liver were removed, cleaned from the fat and adhering connective tissue and kept at -20°C until assayed. Biochemical analysis of blood serum and tissue (liver and heart muscle) levels were carried out for cholesterol,<sup>1</sup> phospholipids,<sup>2</sup> and triglyceride.<sup>3</sup> In addition, blood serum was analyzed further for high density lipoprotein cholesterol.<sup>4</sup> All the results were statistically analyzed using students t-test.

A non-significant reduction in the body weights was noticed in rabbits fed with cholesterol diet and later treated with curcuma longa extract (groups C and D) in comparison with their initial body weights. A non-significant change in heart weight was also observed. However, the liver weight was significantly increased in cholesterol fed rabbits. Curcuma longa (50% EtOH) extract feed for both groups C and D resulted in a significant lowering of total cholesterol, triglycerides and phospholipids in both the liver and the heart ventricular muscles if compared with cholesterol fed rabbits only (Table 1). A 9-fold increase was observed in blood serum cholesterol in treated rabbits fed with atherogenic diet ( $p \leq 0.001$ ). In addition, a significant reduction in the blood serum cholesterol was recorded in both curcuma longa

treatment group C and D rabbits. Serum triglyceride increased significantly ( $p \leq 0.001$ ) after cholesterol feed rabbits, but was subsequently reduced after curcuma longa extract treatment. An increase in phospholipids and high-density lipoprotein (HDL) cholesterol followed by cholesterol diet could be corrected by curcuma longa extract feeding (Table 1).

The level of cholesterol in lipoprotein fractions has been shown to be a good indicator of atherosclerosis risk in rabbits. Significant lowering of cholesterol after curcuma longa feeding indicates a risk reduction action. Plasma triglycerides and cholesterol carry the highest risk for ischemic heart disease, HDL and low-density lipoprotein cholesterol are significant variables and indicators for coronary heart disease. It is reported that HDL is inversely related to total body cholesterol. Treatment with curcuma longa extract reduces serum cholesterol by 75.7% and triglycerides by 66.6%. The HDL alters the balance of unspecified cholesterol between plasma and cells by increasing its utilization in the lecithin cholesterol acyltransferase system to form a cholesterol ester that moves rapidly into the cells. Decreased total cholesterol and phospholipids after curcuma longa extract feeding indicates the anti-atherogenic or hypolipidemic nature of the plant product. Further reduction in total cholesterol, triglycerides and phospholipids of liver and ventricular heart muscle may be suggestive of a beneficial role of curcuma longa in hyperlipidemic subjects. The possible mechanism of lipid alteration might be the cholestatic effect of curcuma longa in liver enhanced removal or catabolism of lipoproteins,<sup>5</sup>

or the inhibition of lysosomal lipid hydrolytic enzymes secreted by the liver, or both.

In conclusion, curcuma longa possesses active hypolipidemic constituents. Further, chemical and pharmacological investigations are in progress.

Received 6th July 2005. Accepted for publication in final form 25th October 2005.

From the Department of Anatomy, Faculty of Medicine, Jordan University of Science and Technology, Irbid, Jordan. Address correspondence and reprint requests to: Dr. Nabil A. Khouri, Department of Anatomy, Faculty of Medicine, Jordan University of Science and Technology, PO Box 3030, Irbid 22110, Jordan. Tel. +962 (2) 7201000. Fax. +962 (2) 7205010. E-mail: nabeelkhouri@yahoo.com

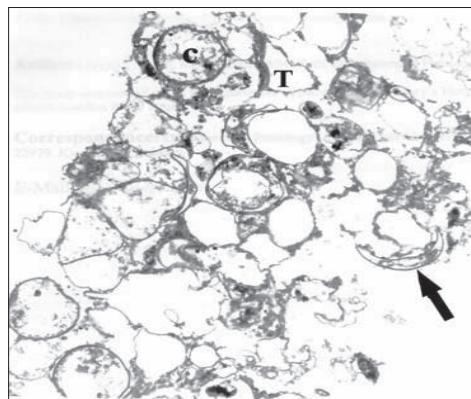
## References

1. Zlatks A, Zak B, Boyle AJ. A new method for the direct determination of serum cholesterol. *J Lab Clin Med* 1953; 41: 486-492.
2. Zilversmit DB, Davis AK. Microdetermination of plasma phospholipids by trichloroacetic acid precipitation. *J Lab Clin Med* 1950; 35: 155-160.
3. Gottfried SP, Rosenberg B. Improved manual spectrophotometric procedure for determination of serum triglycerides. *Clin Chem* 1973; 19: 1077-1078.
4. Burnstein M, Scholnic HR, Morfin R. Rapid method of isolation of lipoprotein from human serum by precipitation with polyanion. *J Lipid Res* 1970; 11: 583-587.
5. Sherlock S. Overview of chronic cholestatic conditions in adults: terminology and definitions. *Clin Liver Dis* 1998; 2: 217-233.

## Ultrastructural studies of *Pneumocystis carinii jiroveci*

Javed F. Wazir, PhD, MRCPATH.

*Pneumocystis carinii (jiroveci)* is a eukaryotic microorganism and is found worldwide. The taxonomic position of *Pneumocystis jiroveci* is still uncertain and is sometimes referred as an orphan organism. Its phylogenetic position has not yet been established, perhaps due to lack of generally accepted criteria for the classification of fungi and protozoa.<sup>1</sup> Initially, *Pneumocystis carinii* was thought to be a protozoan in view of its association with *Trypanosoma cruzi* and *Trypanosoma lewisi*. However, some ultrastructural studies failed to demonstrate the cytoskeletal elements and complex organelle systems, peculiar to protozoa.<sup>2</sup> Furthermore, similarities between *Pneumocystis carinii* and a fungus *Saccharomyces cerevisiae* were



**Figure 1** - Ultrastructure of *Pneumocystis jiroveci* by transmission electron microscopy. Cysts (C), trophozoites (T) and a crescent shaped collapsed cyst (arrow). (Magnification x 5,400)

demonstrated consistently with a close evolutionary linkage between pneumocystis and the fungus at a molecular level.<sup>3</sup> Several hypotheses exist regarding the life cycle of *Pneumocystis jiroveci*. Most studies are based on the morphological evaluation of the organisms in infected human<sup>4</sup> or animal<sup>5</sup> lungs, and some workers claim studies in vitro of rat derived *Pneumocystis carinii*.<sup>6</sup> Only few ultrastructural studies of *Pneumocystis carinii* have been published in the English literature. This study was carried out at the Department of Pathology, UK. Four bronchoalveolar lavage specimens from AIDS cases were centrifuged at 1500 rpm for 10 minutes. A cell pellet was prepared and fixed in 1% glutaraldehyde for transmission electron microscopy. The cell pellet was processed and thin sections were stained with lead citrate and uranyl acetate. Sections were examined by transmission electron microscopy for morphology. In 7 specimens, the sediment was spread on thermanox coverslips fixed in 1% glutaraldehyde and processed for scanning electron microscopy. Morphology of the cyst and trophozoite was noted. Transmission electron microscopy was carried out on 4 cases to investigate the life cycle of *Pneumocystis carinii*. In this study, cysts, precysts, and trophozoites of *Pneumocystis carinii* were observed (**Figure 1**). The cysts appeared either as crescents or cup shaped organisms. The crescent shaped cysts were collapsed and empty, whereas the cup shaped cysts had intracellular material. The cyst wall (pellicle) measured 80-110 nm in thickness. It consists of an outer electron dense layer, middle electron lucent layer, and an inner electron dense thin membrane. The cyst wall exhibited coffee bean shaped thickening approximately 350 nm in thickness. This thickened area is represented by electron dense material, which corresponds to

the black dot in methenamine silver nitrate stained preparations under light microscopy. This focal thickened portion of the cyst wall exhibited a rounded pore, which is thought to be an opening for sporozoite release. The surface projections of the cysts appeared as vesicular dilatations of the cyst wall. The precysts appeared in the non-collapsed form and of smaller size and had slightly thinner pellicle (30-60 nm) as compared with the cysts. The pellicle is composed of an outer electron dense layer and an inner electron lucent layer. The precysts contained intracystic bodies (sporozoites). The intracystic bodies were round and regular in outline on one occasion, while at another they were irregular and filled the cysts completely. The precysts had an internal delimiting membrane, which partitioned the cyst cytoplasm and connected the cyst wall to the wall of an intracystic body. A few surface projections were also observed on the precysts, which were few in number as compared with the mature cyst. The intracystic bodies did not exhibit any surface projections. The trophozoites of *Pneumocystis carinii* were seen in intimate association with cysts and were of relatively smaller size. They had a thin electron dense pellicle (25-50 nm) with thin long membranotubular extensions (MTE) and electron dense bodies on its outer surface. The trophozoites were more numerous than the cysts and appeared to be attached to neighboring cysts and other trophozoites by MTE. Trophozoites had a distinct nucleus and cytoplasmic organelles (**Figure 1**). The space between the cysts and trophozoites was filled by MTE, which appeared as surface projections of the trophic form of *Pneumocystis carinii*. In contrast, surface projections of the cysts appeared shorter, ultrastructurally different, and sparsely distributed. It was also possible to identify trophozoites and cystic forms of the organism under scanning electron microscopy. Trophozoites were of relatively smaller size than cysts and had a rough surface with numerous MTE. The cysts were identified as convex or concave, oval to round structures. They had a relatively smooth surface as compared with the trophozoites with few attached fragments of MTE from their trophozoite counterparts. The short stubby projections of the cyst wall were also observed, but were not clearly identified.

Both sexual and asexual life cycles have been proposed by different observers. The sexual life cycle is based on observation of synaptonemal complexes at the precyst stage. Synaptonemal complexes appear in the prophase in a variety of eukaryotes. This leads to the development of haploid sporozoites in the cyst of *Pneumocystis jiroveci*. When the cyst wall ruptures the haploid sporozoites develop into haploid

trophozoites, which may function as isogametes and copulate to complete the cycle.<sup>7</sup> Vavra and Kucera<sup>5</sup> and Cushion et al<sup>6</sup> found trophozoites adhering to each other in vivo and in vitro and thought this might be a reflection of the beginning of copulation. Based on these observations, it was hypothesized that this type of copulation might complete the cycle. The asexual life cycle is based on observations that infected lungs contain a very large number of trophozoites in relation to the number of cysts. Nuclear division has often been observed in trophozoites,<sup>5,6</sup> suggesting binary fission or budding. Therefore, it has been postulated that asexual multiplication of trophozoites by binary fission or budding might occur under favorable conditions such as immunosuppression, whereas the sexual cycle is induced by unfavorable conditions.<sup>5</sup> In this study, a focal coffee bean shaped thickening of the cyst wall with a pore was observed under electron microscopy. The thickened portion of the cyst wall with an opening for the release of intracystic bodies (sporozoites) on electron microscopy represents the dark spot in the cyst, seen in methenamine silver nitrate stained smears under light microscopy.

In conclusion, ultrastructural studies of *Pneumocystis jiroveci* show the trophic and cystic forms with precystic stage in its life cycle. The demonstration of a pore in the thickened portion of the cyst wall contributes towards the sexual life cycle of the organism.

Received 17th May 2005. Accepted for publication in final form 24th October 2005.

From the Department of Pathology, Arabian Gulf University, Kingdom of Bahrain. Address correspondence and reprint requests to: Dr. Javed F. Wazir, Department of Pathology, Arabian Gulf University, PO Box 22979, Kingdom of Bahrain. E-mail: javedfw@agu.edu.bh

## References

1. Editorial. Pneumocystis: An orphan organism? *Lancet* 1985; 1: 676-677.
2. Bedrossian CWM. Rapid cytologic diagnosis of pneumocystis: A comparison of effective techniques. *Semin Diagn Pathol* 1989; 6: 245-261.
3. Edman JC, Kovacs JA, Masur H, Santi DV, Elwood HJ, Sogin ML. Ribosomal RNA sequence shows *Pneumocystis carinii* to be a member of the fungi. *Nature* 1998; 334: 519-522.
4. Campbell WG Jr. Ultrastructure of pneumocystis in human lung: Life cycle in pneumocystosis. *Arch Pathol* 1972; 93: 312-324.
5. Vavra J, Kucera K. *Pneumocystis carinii* delanoe, its ultrastructure and ultrastructural affinities. *J Protozool* 1970; 17: 463-483.
6. Cushion MT, Ruffolo JJ, Walzer PD. Analysis of the developmental stages of *Pneumocystis carinii*, in vitro. *Lab Invest* 1988; 58: 324-331.
7. Matsumoto Y, Yoshida Y. Sporogony in *Pneumocystis carinii*: Synaptonemal complexes and mitotic nuclear divisions observed in precysts. *J Protozool* 1984; 31: 420-428.