

The double deep gluteal muscles

Ercan Tanyeli, MD, Turan Pestemalci, MD, Mehmet Uzel, MD, PhD, Mehmet Yildirim, MD.

ABSTRACT

During routine dissections on a 65-year-old male cadaver, we encountered double piriformis, double gemelli superior and inferior, double quadratus femoris muscles in the left gluteal region. The sciatic nerve passed between the lower piriformis and the upper superior gemelli muscles (infrapiriform foramen) as usual. No other variation was found in the region. This rare variation may be of importance in the radiology and surgery of this region.

Saudi Med J 2006; Vol. 27 (3): 385-386

The gluteal region is an area for plenty of surgical procedures. Surgery for nerve entrapment syndromes, orthopedic and traumatologic interventions can be applied at this region.^{1,3} Therefore, it is important to be familiar with the normal structures of the region during surgery or radiologic examinations. A surgeon or radiologist should also be familiar with the variations of structures of this region for a better understanding of the pathologic and normal conditions or for a better application of the surgical procedure. In the medical literature, it is possible to find reports regarding double muscles at the gluteal region.^{1,3}

Case Report. During our routine dissections, as part of the curriculum for students in the 2004-2005 term, we encountered double piriformis, double superior gemellus, double inferior gemellus, and double quadratus femoris muscles in the left gluteal region of a 65-year-old male cadaver. All of these muscles had superior and inferior parts. The sciatic nerve passed between the inferior part of the piriform muscle and superior part of the superior gemellus (infrapiriform foramen). After emerging from infrapiriform foramen, the sciatic nerve was posterior to the superior gemelli, obturator internus, inferior

gemelli and quadratus femoris and went towards the posterior part of the thigh. The tendon of the obturator internus was between the inferior part of the superior gemelli and superior part of the inferior gemelli. The origin of the superior part of the piriform muscle was on the anterior surface of the sacrum while the origin of the lower part was on the sacrotuberous ligament; these 2 parts joined each other near the greater trochanter and attached to it. The superior part of the superior gemelli originated from the corpus of the ischium and the inferior part from ischial spine. The superior part of the inferior gemelli originated from ischiadic spine and the inferior part from ischial tuberosity. All gemelli and obturator internus attached to the medial side of the greater trochanter. Superior and inferior parts of the quadratus femoris originated from ischial tuberosity and attached to intertrochanteric crest.

Discussion. Although the deep gluteal muscles are generally found to be single, they sometimes can be seen to be doubled.⁴⁻⁶ The most common variation of the piriformis muscle is its duplication.⁵ Each part of the duplicated piriformis can attach to the femur together or separately.⁷ Usually the common fibular

From the Department of Anatomy (Tanyeli, Pestemalci, Yildirim), Cerrahpasa Medical Faculty, and the Vocational School of Health Services (Uzel), Istanbul University, Istanbul, Turkey.

Received 18th July 2005. Accepted for publication in final form 12th November 2005.

Address correspondence and reprint request to: Associate Professor Ercan Tanyeli, Department of Anatomy, Cerrahpasa Medical Faculty, Istanbul University, Kocamustafapasa, Istanbul, Turkey. Tel. +90 (212) 4143057. Fax. +90 (212) 4143059. E-mail: tanyeli@istanbul.edu.tr

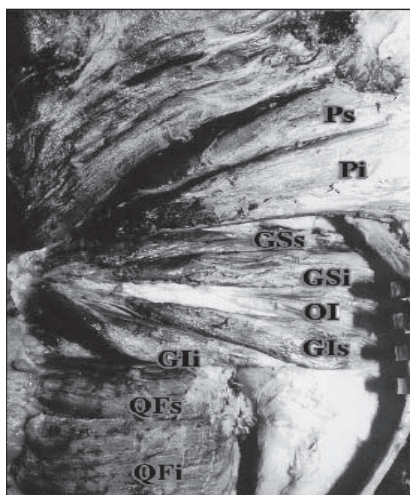


Figure 1 - Photograph of the double muscles at the gluteal region. Ps - superior part of the piriformis, Pi - inferior part of the piriformis, GSs - superior part of the superior gemellus, GSi - inferior part of the superior gemellus; OI - obturator internus, GIs: Superior part of the inferior gemellus, GII - inferior part of the inferior gemellus, QFs - superior part of the quadratus femoris, Qfi - inferior part of the quadratus femoris.

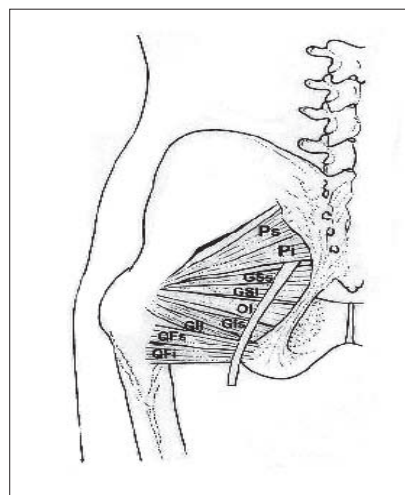


Figure 2 - Schematic drawing of the double muscles at the gluteal region. Ps - superior part of the piriformis, Pi - inferior part of the piriformis, GSs - superior part of the superior gemellus, GSi - inferior part of the superior gemellus, OI - obturator internus, GIs - superior part of the inferior gemellus, Gii - inferior part of the inferior gemellus, QFs - superior part of the quadratus femoris, Qfi - inferior part of the quadratus femoris.

nerve^{5,7,8} or, rarely, tibial or ischiadic nerve⁵ may pass through the duplicated piriformis. But sometimes, as in our case, it is possible that no nerve may pass through. Duplication of the piriformis muscle may be alone⁷ or together^{1,8} with duplication of the other muscles in the region. It may be fused with the gluteus medius, gluteus minimus, superior gemellus or, rarely, obturator internus.^{4,5} The superior gemellus may be small, absent⁹ or double; it may be also found to be fused with piriformis or gluteus medius.⁴ Its duplications may be alone or with duplications of the other muscles (namely, piriform muscle) in the region. The absence of the superior gemellus may be found in 8% of Caucasians and 6% of the black population, but not in the Japanese population.¹

The inferior gemellus may be found to be fused with the quadratus femoris⁴ but, reports on double inferior gemelli are lacking. The quadratus femoris may be absent⁹ or in 2 parts; it may be fused with the inferior gemellus or adductor magnus.⁶ Duplicity of the quadratus femoris, which has an importance in surgery as a muscle pedicle-bone graft in cases of transcervical femoral fractures^{2,3} is also undocumented. Duplicated deep muscles of the gluteal region may cause conflict in radiologic views. The gluteal region has been a subject to many studies regarding the piriformis syndrome and different variations of the muscles in this region have been recorded.^{1,7,8} However, such a case with 4 double muscles on the same side has not been documented. We found this case worth publishing due to the clinical importance

of the region and the very close relationship of the muscles with the nerves and vessels around them.

References

1. Arifoglu Y, Surucu HS, Sargon MF, Tanyeli E, Yazar F. Double superior gemellus together with double piriformis and high division of the sciatic nerve. *Surg Radiol Anat* 1997; 19: 407-408.
2. Delima DF, Tanna DD. The quadratus femoris graft in old transcervical femoral fractures. *J Postgrad Med* 1989; 35: 152-156.
3. Morwessel R, Evarts CM. The use of quadratus femoris muscle pedicle bone graft for the treatment of displaced femoral neck fractures. *Orthopedics* 1985; 8: 972-976.
4. Bergman RA, Afifi AK, Miyauchi R. Gemelli and Obturator Internus. Available from: URL: <http://www.vh.org/adult/provider/anatomy/AnatomicVariants/MuscularSystem/Text/G/02Gemelli.html>
5. Bergman RA, Afifi AK, Miyauchi R. Piriformis. Available from: URL: <http://www.vh.org/adult/provider/anatomy/AnatomicVariants/MuscularSystem/Text/P/24Piriformis.html>
6. Bergman RA, Afifi AK, Miyauchi R. Quadratus Femoris. Available from: URL: <http://www.vh.org/adult/provider/anatomy/AnatomicVariants/MuscularSystem/Text/Q/01Quadratus.html>
7. Kirici Y, Yazar F, Ozan H. The neurovascular and muscular anomalies of the gluteal region: an atypical pudendal nerve. *Surg Radiol Anat* 1999; 21: 393-396.
8. Kirici Y, Ozan H. Double gluteus maximus muscle with associated variations in the gluteal region. *Surg Radiol Anat* 1999; 21: 397-400.
9. Williams PL, Warwick R, Dyson M, Bannister LH, editors. *Gray's Anatomy*. 37th ed. New York: Churchill Livingstone; 1989. p. 641-644.