

# Osteoarthritis models after anterior cruciate ligament resection and medial meniscectomy in rats

## *A histological and immunohistochemical study*

Abmet Piskin, MD, Mustafa Y. Gulbahar, DVM, Yilmaz Tomak, MD, Birol Gulman, MD, Murat Hokelek, MD, Servet Kerimoglu, MD, Bulent Koksak, MD, Taner Alic, MD, Yonca B. Kabak, DVM.

### ABSTRACT

**Objectives:** To compare the amount of degeneration based on the time spent, using 2 different methods of surgically induced osteoarthritis (OA) that frequently used in treating OA.

**Methods:** We undertook this research in Ondokuz Mayıs University, Surgical Research Center between April 2006 and July 2006. In this study, 55 rats were used, 7 as the control group, and 12 in each of 4 groups. We compared the amount of OA formed by the medial meniscectomy (MMx) and anterior cruciate ligament transection (ACLT) at 8 and 16 weeks according to the Modified Mankin Score and histologically and immunohistochemically due to their response to Matrix metalloproteinase 13 expression (MMP13).

**Results:** We observed the highest degeneration in the MMx model at 8 weeks, and this situation continued until 16 weeks. However, the degeneration in the ACLT model was lower at 8 weeks compared with the MMx group, however, it reached the same amount as the MMx group at 16 weeks.

**Conclusion:** The OA model formed by the ACLT method was better than the MMx model when degeneration and time were taken into consideration and should be used when researching drugs on an experimental basis in OA.

*Saudi Med J 2007; Vol. 28 (12): 1796-1802*

*From the Departments of Orthopaedics and Trauma Surgery (Piskin, Tomak, Gulman, Koksak, Alic), Pathology (Gulbahar), Medical and Surgical Research Centre (Hokelek), Faculty of Medicine, Department of Pathology (Kabak), Faculty of Veterinary Medicine, University of Ondokuz Mayıs, and the Department of Orthopaedics and Trauma Surgery (Kerimoglu), Faculty of Medicine, University of Kardeniz Technical, Samsun, Turkey.*

*Received 16th April 2007. Accepted 24th July 2007.*

*Address correspondence and reprint request to: Dr. Servet Kerimoglu, University of Kardeniz Technical, Faculty of Medicine, Department of Orthopaedics and Trauma Surgery 61080, Trabzon, Turkey. Tel. +90 (462) 3775486. Fax. +90 (462) 3252270. E-mail: serkerim70@yahoo.com*

Osteoarthritis (OA) is a degenerative joint disease generally characterized by progressive cartilage degeneration, subchondral bone changes, osteophyte formation and low grade synovitis.<sup>1</sup> A disease modifying treatment for OA is not available.<sup>2</sup> Ideally, therapies to prevent progression should be applied early in the course of OA and for this reason studying early changes in OA is important. Several animal models of OA have been developed to study the biochemical and histological changes associated with cartilage degeneration in early stages of OA in vivo.<sup>3,4</sup> Surgically induced instability models of OA have been described in various animal species. Traumatic OA does occur in humans and therefore these models may mimic aspects of the pathogenesis and pathology.<sup>5</sup> Among the surgically induced animal models of OA, the anterior cruciate ligament transection (ACLT) in dogs and the partial menisci resection model in rabbits have been widely used.<sup>6</sup> These models continue to be investigated in dogs and rabbits as well as others such as sheep, rats, and guinea pigs.<sup>7,8</sup> However, current understanding of the metabolism of cartilage and bone in dogs and rabbits is rather limited. In addition, the size of these animals and relative lack of availability of biochemical reagents to study molecular dynamics in affected joints has severely restricted the usefulness of these models in evaluating potential disease-modifying agents.<sup>9</sup> For these reasons and other circumstances in our country, we preferred to use rats in our studies. The aim of this study is to compare the amount of degeneration based on the time spent, using 2 different models of surgically induced OA in rats.

**Methods.** In this study, we examined 2 different models of surgically induced OA in the rat, either the ACLT model or resection of medial meniscectomy (MMx). We stopped the disease progression in these models with sacrificing rats at the 8th and 16th weeks post-surgery in order to examine the sequential pathological changes in articular cartilage. All procedures were carried out according to the Institutional Animal Care and Use Committee Guide in Merck Research Laboratory. Fifty-five 10-week-old male Sprague-Dawley rats were used in the following experiments. The ACLT model was induced as previously described.<sup>10</sup> Each rat was anesthetized with isoflurane and after being shaved and disinfected, the right knee joint was exposed through a medial parapatellar approach. The patella was dislocated laterally and the knee was placed in full flexion followed by ACL transection with micro-scissors. The second model (MMx) was induced resection of the medial meniscus as previously described.<sup>11</sup> Each rat was anesthetized with isoflurane and after being shaved and disinfected, the right knee joint was exposed through a medial parapatellar approach. The patella was dislocated laterally and the knee was placed in full flexion. The medial meniscus was grasped with a hemostat and reflected proximally toward the femur. The meniscus was transected with scalpel or small surgical scissors. After surgery, the joint surface was washed with sterile saline solution, and both capsule and skin were sutured using Vicryl 4-0 (Ethicon, Edinburgh, UK) absorbable suture and monofilament 4-0 nylon threads (Ethicon, Edinburgh, UK). In sham animals, surgery was not applied. All groups (ACLT at 8 weeks; n=12, ACLT at 16 weeks; n=12, MMx at 8 weeks; n=12, MMx at 16 weeks; n=12) and sham group (n=7) were allowed to move freely in plastic cages until necropsies at 8 and 16 weeks post-surgery.

All rats were sacrificed with high dose anesthesia. The knee joints taken from all the rats were dissected and immediately fixed in 10% neutral buffered formalin for 2 days, and decalcified in formic acid solution for 4 weeks. The tissues were dehydrated through graded alcohol, cleared with xylene, and embedded in paraffin. Coronal sections of the joints were cut at 6  $\mu$ m and mounted on aminoalkylsilane-treated slides. The sections were then stained with Safranin-O (SO) and hematoxylin-eosin (HE).

Additional sections were prepared using a commercial streptavidin-biotin peroxidase system (Zymed Laboratories, Inc., CA) for immunostaining of matrix metalloproteinases 13 (MMP-13). All sections were pretreated for antigen retrieval by heating in a microwave using sodium citrate buffer, pH 6.0 for 20 min and preincubated in 10% normal goat serum (Zymed Laboratories, Inc., CA) at room temperature

for 10 min to block non-specific binding of second step antibody (Zymed Laboratories, Inc., CA). Sections were reacted with primary mouse anti-MMP13 (Collagenase-3) monoclonal antibody, clone SPM292 (Spring Bioscience, CA) overnight at 4°C and then rinsed with phosphate buffer solution of pH 7.4 at room temperature. Following that, the sections were reacted with biotin-conjugated second step antibody (Zymed Laboratories, Inc., CA) for 10 min at room temperature, and then rinsed in PBS. To inactivate the endogenous peroxidase, sections were incubated in 0.3% H<sub>2</sub>O<sub>2</sub>/methanol for 60 min. The sections were again rinsed with PBS and reacted with the streptavidin-biotin-peroxidase complex (SABC) (Zymed Laboratories, Inc., CA) for 10 min at room temperature. After another washing with PBS, sections were incubated with diaminobenzidine (DAB) (Zymed Laboratories, Inc., CA) for 15 min and then counter stained with Mayer's hematoxylin. Four negative controls were prepared, firstly by omitting the primary antibodies, and then by replacing them with PBS, normal rabbit serum, and unrelated mouse monoclonal antibodies. Histological assessments of sections were evaluated using a modified Mankin grading system<sup>12</sup> and the intensity of MMP13 immunostaining was scored as seen in Table 1.

**Statistical analysis.** Differences between subcategories were calculated using Spearman's rank correlation. All data were analyzed in SAS statistical program. Differences were considered significant for *p*-values of <0.01.

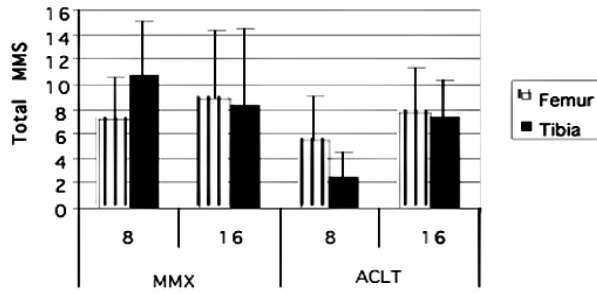
**Results.** Histopathological changes in MMx models do not seem to occur in a time-dependent manner. However, the histopathologic changes in ACLT groups show an increase in time has been observed. The degenerative lesions in MMx groups started severely during the 8th weeks and lasted until the 16th weeks. Yet, the degenerative changes in the ACLT groups started mildest during the 8th-week compared to the 8th-week MMx group and showed an increase towards the 16th-week. This increase is statistically significant for the tibial plateau (*p*<0.05). Although there was a similar degenerative increase in the femur condylus, it is not statistically significant. The modified Mankin score in both OA models was significantly higher than the control group at the 8th and 16th weeks post-surgery (data not shown). As determined by total modified Mankin score, the ACLT models generally showed milder OA changes relative to the MMx models for both tibial plateau and femoral condylus (Table 2) (Figure 1). The cartilage of tibial plateau had more evident findings than femoral condylus for subcategories of modified Mankin scoring system, especially at the 8th-week post-surgery in MMx groups (*p*=0.001). Although

**Table 1** - Modified Mankin grading system for histologic evaluation and scoring of MMP13 immunostaining intensity

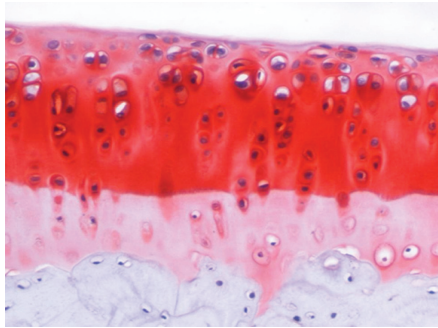
Modified Mankin grading system	
<i>Safranin O-fast green staining</i>	
0	= uniform staining throughout articular cartilage
1	= loss of staining in the superficial zone for less than one-half of the length of the condyle or plateau
2	= loss of staining in the superficial zone for one-half or more of the length of the condyle or plateau
3	= loss of staining in the superficial and middle zones for less than one-half of the length of the condyle or plateau
4	= loss of staining in the superficial and middle zones for one-half or more of the length of the condyle or plateau
5	= loss of staining in all 3 zones for less than one-half of the length of the condyle or plateau
6	= loss of staining in all 3 zones for one-half or more of the length of the condyle or plateau
<i>Chondrocyte loss</i>	
0	= no decrease in cells
1	= minimal decrease in cells
2	= moderate decrease in cells
3	= marked decrease in cells
4	= very extensive decrease in cells
<i>Structure</i>	
0	= normal
1	= surface irregularities
2	= 1-3 superficial clefts
3	= 3 superficial clefts
4	= 1-3 clefts extending into the middle zone
5	= 3 clefts extending into the middle zone
6	= 1-3 clefts extending into the deep zone
7	= 3 clefts extending into the deep zone
8	= clefts extending to calcified cartilage
<i>Chondrocytes clustering</i>	
0	= normal
1	= minimal ( $\leq 4$ )
2	= moderate ( $>4$ but $\leq 8$ )
3	= marked ( $>8$ )
<i>Tidemark (TM) integrity</i>	
0	= intact
1	= disruption to TM and multiple TM
<i>Intensity of MMP-13 immunostaining</i>	
0	= no signal
1	= weak signal
2	= moderate signal
3	= dense signal
MMx - medial meniscectomy, ACLT - Anterior cruciate ligament transection, MMP13 - Matrix metalloproteinase 13 expression	

**Table 2** - Total Mankin scoring system and MMP13 immunostaining Score

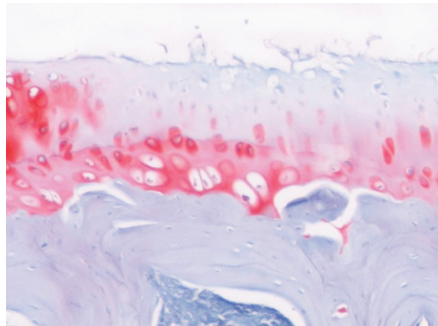
Surgery (weeks)	Total Mankin scoring system		MMP13 immunostaining score	
	Femoral condylus	Tibial plateau	Femoral condylus	Tibial plateau
<i>MMx</i>				
8	7.16 $\pm$ 3.37*	10.75 $\pm$ 4.39 <sup>a,c</sup>	1.72 $\pm$ 0.19 <sup>c</sup>	1.90 $\pm$ 0.19 <sup>c</sup>
16	8.83 $\pm$ 5.56 <sup>c</sup>	8.33 $\pm$ 6.08 <sup>a</sup>	0.81 $\pm$ 0.19 <sup>d</sup>	0.81 $\pm$ 0.19 <sup>d</sup>
<i>ACLT</i>				
8	5.50 $\pm$ 3.50 <sup>a,c</sup>	2.50 $\pm$ 1.97 <sup>b,d</sup>	1.16 $\pm$ 0.18 <sup>c</sup>	1.16 $\pm$ 0.18 <sup>c</sup>
16	7.72 $\pm$ 3.66 <sup>c</sup>	7.27 $\pm$ 3.13 <sup>a</sup>	0.66 $\pm$ 0.26 <sup>c</sup>	0.66 $\pm$ 0.26 <sup>d</sup>
<sup>a,b</sup> The difference between the lines beginning with the same letter is significant, <sup>c,d</sup> The difference between the columns beginning with the same letter is significant, MMx - medial meniscectomy, ACLT - anterior cruciate ligament transection, MMP13 - Matrix metalloproteinase 13 expression				



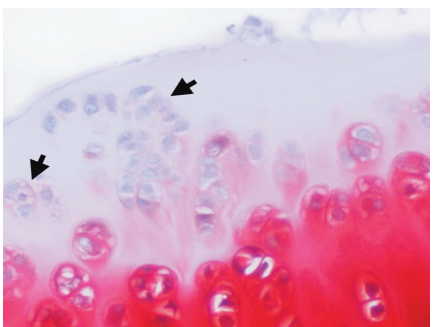
**Figure 1** - Total modified Mankin scores (MMS) of the anterior cruciate ligament transection and meniscectomized (MMX) groups.



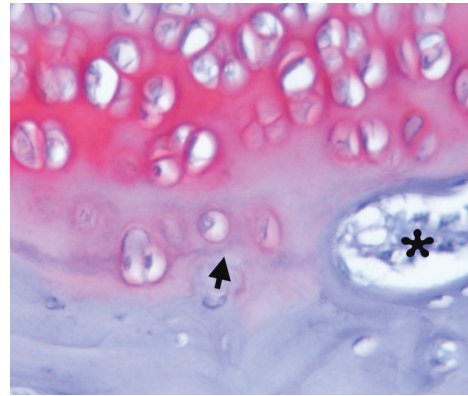
**Figure 2** - Normal appearance of tibial plateau in control group. Safranin-O staining, x150.



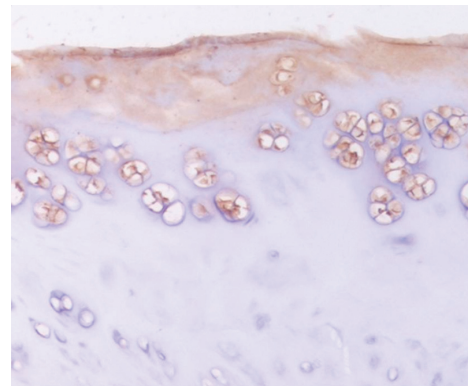
**Figure 3** - The loss of proteoglycan matrix with surface irregularity and fibrillation in tibial cartilage. Safranin-O staining, x150.



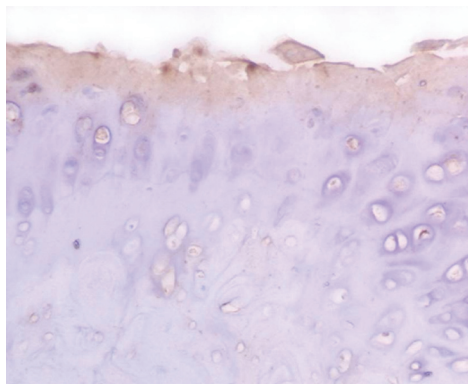
**Figure 4** - Some foci of chondrocyte clustering (arrows) with irregular surface of cartilage and loss of proteoglycan matrix in tibial cartilages, (16-week anterior cruciate ligament transection groups), Safranin-O staining, x300.



**Figure 5** - Irregular tidemark (arrow) crossed by a vascular vessel (\*) in tibial cartilage. 16-week meniscectomized. Safranin-O staining, x300.



**Figure 6** - Strong Matrix metalloproteinase 13 expression in clustering chondrocytes and irregular surface of the tibial cartilage in 8-week meniscectomized group. Streptavidin-biotin-peroxidase complex method, diaminobenzidine chromogen, hematoxylin counterstain, x150.



**Figure 7** - Mild positive signal for Matrix metalloproteinase 13 expression in chondrocytes and cartilage matrix of tibial plateau compared with 8-meniscectomized group (Figure 6). Streptavidin-biotin-peroxidase complex method, diaminobenzidine chromogen, hematoxylin counterstain, x150.



structural changes and chondrocytes clustering shows no significant feature between the groups in terms of surgical method or periods, it was more evident in the tibial plateau of the 8-week MMx group, yet it was considered not statistically significant ( $p>0.05$ ). At this point, the initial changes in cartilage were irregularities of the articular cartilage surface and progressed into fibrillation with loss of both proteoglycan matrix and chondrocyte number. Loss of SO staining was observed generally in the superficial and middle zones for less than one-half of the length of the condyle or plateau. In some cases, cartilages unstained or stained with only territorial matrix of chondrocytes were also observed in the superficial and middle zones. Chondrocytes loss was generally seen together with loss of SO staining in many cases of the surgical groups (Figures 2 & 3).

In most of the meniscectomized specimens at the 8th-week post-surgery individually, the presence of some splits between the calcified and non-calcified cartilage were noticed and these cases also had high scores for some other criteria of cartilage damage, including loss of SO staining, decreased chondrocyte number and structural changes of deep layers. The other parameter, chondrocytes clustering, occurred especially in the superficial layer of both cartilages, with proteoglycan loss and structural deformities (Figure 4). The numbers of chondrocytes clustering statistically did not change with both the surgical method and post-surgical time. However, statistically tide mark (TM) integrity score significantly increased in the ACLT method for the cartilage of both bones at 16 weeks post-surgery ( $p<0.01$ ). In the surgical groups, TM was irregular and multiple, and disappeared in some cases at the 16-week post-surgical time. A few cases showed TM crossed by a vascular vessel (Figure 5). In the specimens of control cartilage from femoral condylus and tibial plateaus, territorial and intercellular matrices were unstained or the superficial layers of cartilage were weakly stained for MMP13. In the surgical groups, a large number of individual and clustering chondrocytes were positive for MMP13, and intercellular matrix in the degenerated superficial layer and sometimes deep layer were also expressed MMP13. The percentage of MMP13 positive cells increased compared with control cartilage. Statistically, both ACLT and MMx groups demonstrated significant increases in MMP13 expression at 8 weeks post-surgical than 16 weeks ( $p<0.05$ ) (Figures 6 & 7). However the increase in the 8-week MMx group was more than that in the 16-week ACLT group.

**Discussion.** Connective tissues tend to heal naturally and successfully only if the injury is minor. If the damage is more severe, then a good functional

result can be achieved only if nature is assisted by surgical intervention. The efficacy of such measures has been established in the cases of bone and tendon injuries but not in the cases of cartilage damage.<sup>13</sup> In the latter situation, we are still prejudiced by Hippocrates' opinion that "ulcerated cartilage is universally allowed to be a troublesome disease". For this reason, in order to reduce the development of cartilage damage or reduce the period, a lot of therapeutic drugs have been developed currently. During the developmental phase of these drugs, the experimental animals and surgical methods chosen are of various kinds. In our study, we histologically and immunohistochemically compared the 2-frequently-used different methods for cartilage degeneration in easily available experimental rats. In this study, we demonstrated that OA changes, including cartilage degradation, develop sequentially and progressively with time in ACLT models of OA in rats based on surgically induced joint instability, however in MMx models it does not develop. The first degenerative changes in both surgical-induced OA models in rats were found in the superficial zone of cartilage. These changes consisted of loss of proteoglycan and focal surface damage, including focal fibrillation of the articular surface and decreased chondrocyte cell number. However, statistically TM integrity score significantly increased in the ACLT model for cartilage of both bones at 16 weeks postoperatively. This finding shows that the lesion, with time increase, has reached to a deeper cartilage tissue; thus, there will be no any cause in the MMx group. Matrix metalloproteinases (MMPs) are thought to be major mediators of cartilage degradation.<sup>14</sup> Three MMP collagenases have been identified and collagenases activity has been found in osteoarthritic cartilage.<sup>15,16</sup> They are collagenase 1 (MMP1), collagenase 2 or neutrophil collagenase (MMP8) and collagenase 3 (MMP13). Collagenase 3 has a higher level of activity against type II collagen, characteristically found in cartilage, than MMP13.<sup>17</sup> In our immunohistochemical study, in the 8-week MMx group, a severe MMP13 response was found, yet this response was lower in other groups. We found that in the 8-week MMx group, at an early stage a more severe degeneration develops when compared with other groups. In the advanced stage of OA between 8 weeks and 16 weeks postoperatively, which is consistent with previous histological changes, we observed the ACLT or MMx models in dogs, rabbits and guinea pigs.<sup>5,11,18,19-21</sup> When the groups have been compared with each other, in the 8-week MMx group, the degeneration is much higher than slightly the other groups, although it decreased a little bit, again in the 16th week it continued to be severe. However, the degeneration formation in the rats in the ACLT groups, although mild in the

8th week, was the same as in the MMx model at the 16th week. Recent studies characterized cartilage degradation in the rat ACLT and meniscectomized OA models at advanced stages of the disease.<sup>10,11,22</sup> In this study, we analyzed 2 time points following surgery for cartilage degradation. In this study, we found that the disease progression in ACLT joints is milder with less cartilage damage than that observed in the joints with meniscectomy. Cartilage degeneration in rat or rabbit MMx models with partial meniscectomy and medial collateral ligament (MCL) transection has been reported to develop surface cartilage damage within 3-6 weeks postoperatively.<sup>5</sup> In the present study, we observed that the rat MMx model seems too aggressive to develop surface cartilage damage within 8 weeks postoperatively. The severity of the MMx model could have resulted from the higher degree of joint instability, as compared to that in the ACLT models, although this explanation seems to be contradictory with the knee instability seen in humans. The results obtained make us think that the positions of the rats may lead to different results than those in humans. A recent study in dogs in which knee instability was formed through ACLT method; the results showed a progressive increase in total quantity and thickness of articular cartilage of the unstable knee.<sup>23</sup> Rapid progression of cartilage degeneration makes the MMx model an extremely high hurdle test for detecting protective effect, thus, we suggested that the ACLT model may be more suitable for the evaluation of disease-modifying therapeutic agents for OA. Of all surgical models, radiographic, morphologic and biochemical changes have been best characterized in dogs or rabbits with the ACLT transaction as well as in rabbits with medial meniscectomy. Pathological changes documented in the rat AO models are closely comparable with the surgically induced models of OA described in the other species.<sup>5,11,18,19</sup> On the other hand, while significant cartilage loss and osteophyte formation take more than a year to develop in ACLT dogs, disease progresses at a faster rate in the rat models, similar to that in rabbits.<sup>19</sup> Thus, in addition to the advantages of the relatively small size and low cost, our results suggest that the use of rat OA models will significantly shorten the time frame required for future pharmacological intervention studies. Ideally, an animal model of human disease, especially one used for drug testing, should have a similar pathogenesis and progression as a naturally occurring disease. The pathogenesis of primary OA is not clearly defined; however, it is known that secondary OA develops following meniscectomy or ACLT.<sup>24</sup> Therefore, the results using surgical models in animals are probably adequate for extrapolation to man, at least in the case of secondary OA where a predisposing cause is known. However, in MMx surgical models, the lesion in the cartilage is usually severe by

8 weeks postoperatively. Therefore, with respect to its use for pharmaceutical testing of compounds designed to affect the degenerative process, it would likely be a very difficult model in which to achieve efficacy since chemicals with less than spectacular ability to enhance cell survival or prevent matrix degeneration would probably be missed.

For these reasons, we encourage researchers to use ACLT resection model in rats in developing drugs in an experimental model of osteoarthritis.

## References

1. Lohmander LS. What can we do about osteoarthritis? *Arthritis Res* 2000; 2: 95-100.
2. Marijnissen AC, van Roermund PM, TeKoppele JM, Bijlsma JW, Lafeber FP. The canine groove model, compared with the ACLT model of osteoarthritis. *Osteoarthritis Cartilage* 2002; 10: 145-155.
3. Warskyj M, Hukins DW. Animal models for osteoarthritis-ensuring experimental validity. *Br J Rheumatol* 1990; 29: 219-221.
4. Pritzker KP. Animal models for osteoarthritis: processes, problems and prospects. *Ann Rheum Dis* 1994; 53: 406-420.
5. Bendele AM. Animal models of osteoarthritis. *J Musculoskelet Neuronal Interact* 2001; 1: 363-376.
6. Laurent GA, and Marian FY. Animal models of osteoarthritis: lessons learned while seeking the 'Holy Grail'. *Current Opinion in Rheumatology* 2006; 18: 537-547.
7. Oakley SP, Lassere MN, Portek I, Szomor Z, Ghosh P, Kirkham BW, et al. Biomechanical, histologic and macroscopic assessment of articular cartilage in a sheep model of osteoarthritis. *Osteoarthritis Cartilage* 2004; 12: 667-679.
8. Kamekura S, Hoshi K, Shimoaka T, Chung U, Chikuda H, Yamada T, et al. Osteoarthritis development in novel experimental mouse models induced by knee joint instability. *Osteoarthritis Cartilage* 2005; 13: 632-641.
9. Hayami T, Pickarski M, Zhuo Y, Wesolowski GA, Rodan GA, Duong le T. Characterization of articular cartilage and subchondral bone changes in the rat anterior cruciate ligament transection and meniscectomized models of osteoarthritis. *Bone* 2006; 38: 234-243. Epub 2005 Sep 26.
10. Stoop R, Buma P, van der Kraan PM, Hollander AP, Clark Billingham R, Robin Poole A, et al. Differences in type II collagen degradation between peripheral and central cartilage of rat stifle joints after cranial cruciate ligament transection. *Arthritis Rheum* 2000; 43: 2121-2131.
11. Janusz MJ, Bendele AM, Brown KK, Taiwo YO, Hsieh L, Heitmeyer SA. Induction of osteoarthritis in the rat by surgical tear of the meniscus: Inhibition of joint damage by a matrix metalloproteinase inhibitor. *Osteoarthritis Cartilage* 2002; 10: 785-791.
12. Mankin HJ, Dorfman H, Lippiello L, Zarins A. Biochemical and metabolic abnormalities in articular cartilage from osteoarthritic human hips. II. Correlation of morphology with biochemical and metabolic data. *J Bone Joint Surg Am* 1971; 53: 523-537.
13. Buckwalter JA, Hunziker EB. Orthopaedics. Healing of bones, cartilages, tendons, and ligaments: a new era. *Lancet* 1996; 348 Suppl 2: s118.

14. Martel-Pelletier J, Pelletier JP. Neutral metalloproteases and age related changes in human articular cartilage. *Ann Rheum Dis* 1987; 46: 363-369.
15. Freije JM, Diez-Itza I, Balbin M, Sanchez LM, Blasco R, Tolivia J, et al. Molecular cloning and expression of collagenase-3, a novel human matrix metalloproteinase produced by breast carcinomas. *J Biol Chem* 1994; 269: 16766-16773.
16. Freemont AJ, Byers RJ, Taiwo YO, Hoyland JA. In situ zymographic localisation of type II collagen degrading activity in osteoarthritic human articular cartilage. *Ann Rheum Dis* 1999; 58: 357-365.
17. Mitchell PG, Magna HA, Reeves LM, Lopresti-Morrow LL, Yocum SA, Rosner PJ, et al. Cloning, expression, and type II collagenolytic activity of matrix metalloproteinase-13 from human osteoarthritic cartilage. *J Clin Invest* 1996; 97: 761-768.
18. Brandt KD. Animal models of osteoarthritis. *Biorheology* 2002; 39: 221-235.
19. Hashimoto S, Creighton-Achermann L, Takahashi K, Amiel D, Coutts RD, Lotz M. Development and regulation of osteophyte formation during experimental osteoarthritis. *Osteoarthritis Cartilage* 2002; 10: 180-187.
20. Pastoureau P, Leduc S, Chomel A, De Ceuninck F. Quantitative assessment of articular cartilage and subchondral bone histology in the meniscectomized guinea pig model of osteoarthritis. *Osteoarthritis Cartilage* 2003; 11: 412-423.
21. Pelletier JP, Boileau C, Brunet J, Boily M, Lajeunesse D, Reboul P, et al. The inhibition of subchondral bone resorption in the early phase of experimental dog osteoarthritis by licofelone is associated with a reduction in the synthesis of MMP-13 and cathepsin K. *Bone* 2004; 34: 527-538.
22. Karahan S, Kincaid SA, Kammermann JR, Wright JC. Evaluation of the rat stifle joint after transection of the cranial cruciate ligament and partial medial meniscectomy. *Comp Med* 2001; 51: 504-512.
23. Adams ME, Brandt KD. Hypertrophic repair of canine articular cartilage in osteoarthritis after anterior cruciate ligament transection. *J Rheumatol* 1991; 18: 428-435.
24. Bendele AM. Progressive chronic osteoarthritis in femorotibial joints of partial medial meniscectomized guinea pigs. *Vet Pathol* 1987; 24: 444-448.

## Supplements

---

- \* Supplements will be considered for work including proceedings of conferences or subject matter covering an important topic
- \* Material can be in the form of original work or abstracts.
- \* Material in supplements will be for the purpose of teaching rather than research.
- \* The Guest Editor will ensure that the financial cost of production of the supplement is covered.
- \* Supplements will be distributed with the regular issue of the journal but further copies can be ordered upon request.
- \* Material will be made available on Saudi Medical Journal website