

Urofacial syndrome

Hamdan H. Al-Hazmi, MD, Ayman A. Hammad, MD, Roman Jednak, MD, Mohamed T. El-Sherbiny, MD.

ABSTRACT

The urofacial or Ochoa syndrome is a rare disease. We report on 2 patients of middle-eastern origin, with a review of the current literature to further document the existence of this syndrome, and to increase the general awareness of the classical facial characteristics, which facilitates diagnosis.

Saudi Med J 2007; Vol. 28 (12): 1895-1897

From the Division of Pediatric Urology (Al-Hazmi, Jednak, El-Sherbiny), Montreal Children's Hospital, McGill University Health Centre, Montreal, Canada, and the Urology and Nephrology Center (Hammad), Mansoura, Egypt.

Received 24th January 2007. Accepted 30th April 2007.

Address correspondence and reprint request to: Dr. Hamdan H. Al-Hazmi, The Montreal Children's Hospital, C529, 2300, rue Tupper, Montreal, Quebec H3H 1P3, Canada. Tel. +1 (514) 412 4366. Fax. +1 (514) 412 4384. E-mail: drhamdanbh@hotmail.com

In 1987, Ochoa and Gorlin¹ reported on 36 children having a syndrome of urinary tract infections, enuresis, and constipation, which was associated with a wide spectrum of urinary tract damage due to non-neurogenic bladder dysfunction. Interestingly, these patients all had a characteristic facial feature, which was the inversion of facial expression with laughing. They suggested the term urofacial syndrome (UFS) for this disorder. Subsequently, Teebi et al,² and Teebi and Hassoon³ reported the first 2 cases outside the USA. As a result of an increased awareness of the characteristic facial expression, Ochoa⁴ reported an additional 14 cases. Gracia-Minaur et al⁵ later reported 3 European cases. Recently, Nicanor et al⁶ reported the first case diagnosed in a newborn. Herein, we report an additional 2 patients of middle-eastern origin. Our aim is to further document the existence of this syndrome, and to increase the general awareness of the classical facial characteristics to facilitate the diagnosis.

Case Report. Patient 1. A 12-year-old boy from Syria, whose parents were first cousins, and with 2 brothers and 4 healthy sisters. One brother had similarly been affected and died of uremia at 10 years of age. He was examined at 5 years of age with recurrent febrile urinary tract infections, diurnal enuresis, and bilateral vesicoureteral reflux. There was no history of constipation. Antireflux surgery was performed, however, it failed. Bilateral urinary diversion in the form of high cutaneous ureterostomies was eventually performed as a result of progressively deteriorating renal function. Physical examination revealed the characteristic inversion of facial expression with smiling (**Figure 1**). The serum creatinine was normal. Both the neurological examination and MRI results of the lumbosacral spine were normal. Renal ultrasound showed no hydronephrosis with normal size kidneys. Renal scan showed symmetrical function with multiple bilateral renal scars. Voiding cystourethrography revealed an irregular bladder of small capacity, with narrowing of the urethra at the level of the external sphincter and right vesicoureteral reflux (**Figure 2**). Grading of reflux could not be determined due to the high ureterostomy. A left antegrade ureterogram showed no obstruction. Cystometry revealed small bladder volume (110 mL, normal range: 350-400 mL), poor compliance, and large post-void residual (65 mL, normal range: <30 mL [$<10\%$ normal capacity for age]). Voiding was characterized by poor flow and sphincter dis-coordination. Cystoscopy excluded an anatomic urethral obstruction. The patient underwent a right-to-left transureteroureterostomy and ileocystoplasty. A Mitrofanoff was created to facilitate intermittent catheterization. Six months postoperatively, the serum creatinine was 80 $\mu\text{mol/L}$, and he was dry on intermittent catheterization. Both kidneys remained normal on follow up ultrasound.

Patient 2. A 9-year-old boy from Egypt, whose parents were healthy first cousins. He presented with complaints of nocturnal enuresis resistant to imipramine hydrochloride. He also complained of urgency with

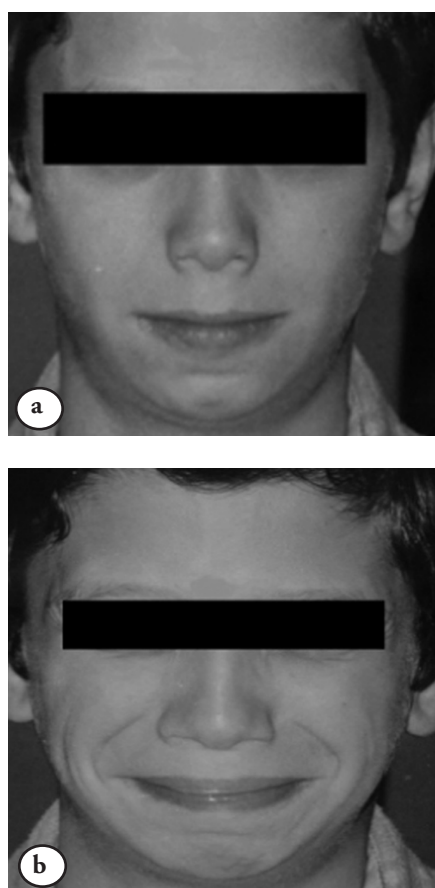


Figure 1 - Facial expression of patient one showing a) normal and b) inversion of facial expression when laughing.

associated urge incontinence. Bowel movements were occurring every 4 days. The family history was negative for a similar condition. Clinical examination revealed the characteristic inversion of facial expression with smiling. Serum creatinine and renal ultrasound were normal. Voiding cystourethrography showed a smooth bladder with narrowing of the urethra at the level of the external sphincter (**Figure 3**). Uroflowmetry with electromyography demonstrated a dis-coordinated voiding. Voided volume was 90 mL (minimal voided volume accepted 120 ml, estimated functional bladder capacity=250-330 ml) and the post-void residual was 145 mL (normal range: <22 mL [$<10\%$ normal capacity for age]). Cystoscopy excluded an anatomic urethral obstruction. A bladder rehabilitation program was started, and the constipation was treated. Six months into therapy, a marked symptomatic improvement was noted. Day symptoms have recovered completely. Nocturnal enuresis has decreased to less than 3 times per month. Follow up flow study showed increased voided volume to 325 mL and decreased post void residual to 45 mL. The curve was slightly prolonged with minimal dis-coordination.

Discussion. The UFS or Ochoa syndrome is a rare disease with characteristic symptomatology consisting of recurrent urinary infections, incontinence, constipation, dysuria, frequency, and enuresis. These problems stem from a non-neurogenic neurogenic form of bladder dysfunction. Voiding cystourethrography typically reveals bladder trabeculation and vesicoureteral reflux. These patients have no apparent neurological or

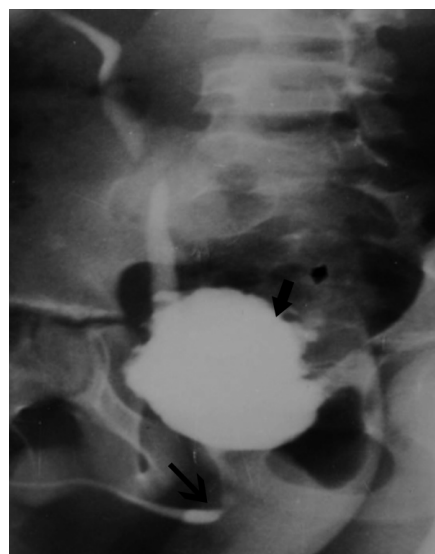

Figure 2 - Voiding cystourethrography showed an irregular bladder of small capacity with narrowing of the urethra at the level of the external sphincter and right reflux.

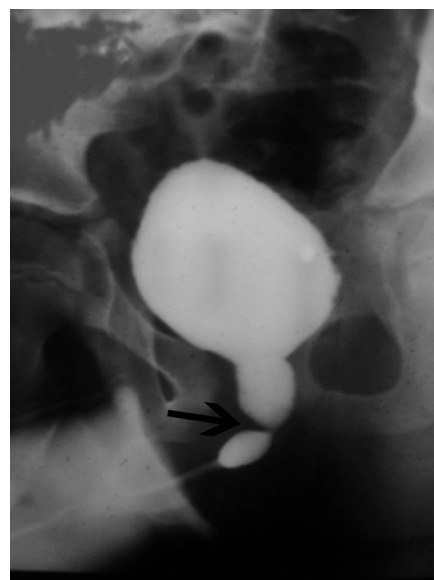


Figure 3 - Voiding cystourethrography showed smooth bladder with narrowing of the urethra at the level of the external sphincter.

obstructive abnormality and classically exhibit a unique facial expression, whereby attempted smiling produces facial inversion and they appear to be grimacing. Ochoa syndrome usually occurs in children and adolescents, and equally affects both genders. The syndrome may represent a subgroup of the nonneurogenic neurogenic bladder patients as described by Hinman and Bauman⁷ in 1973. Ochoa syndrome is transmitted in an autosomal recessive fashion.¹ Wang et al⁸ were able to place the UFS gene to within a 1-cM interval on chromosome 10q23-q24 using a combination of homozygosity mapping and DNA pooling-strategies. The parents of both patients described here were consanguineous and healthy, which supports an autosomal recessive pattern of inheritance. As the name implies, UFS patients have both urinary and facial abnormalities. Bladder dysfunction in the form of severe detrusor-sphincter dis-coordination underlies the urinary tract abnormalities. Both our patients suffered from dis-coordination during voiding as demonstrated on uroflowmetry and electromyography. Early diagnosis and biofeedback training was useful in preventing upper urinary tract deterioration in the second patient.

Patients with Ochoa syndrome may develop urinary tract pathology having a wide spectrum of severity. Mild cases may simply present with the characteristic facial findings and mild, or at times no urinary tract issues. Severe bladder dysfunction with a significant functional obstruction may in other cases lead to, poor bladder emptying with high residual urine, hydroureteronephrosis with vesicoureteral reflux and potentially renal failure. Urinary tract symptomatology can also be quite variable, and patients may present with urinary tract infection, urgency, frequency, incontinence, polyuria, and polydipsia. Moreover, many patients may have associated elimination dysfunction including constipation (60%) and encopresis (33%).^{5,6}

Patients with UFS have a pathognomonic inversion of facial expression. When attempting to laugh or smile, their facial musculature inverts and they appear to be grimacing or crying. Interestingly, patients demonstrate emotionally congruent facial expression when sad or crying. The laughing and crying centers are located in upper pons of the midbrain lying in close proximity to the micturition center. It has been speculated that a subtle neurologic lesion may simultaneously affect both regions therefore resulting in this clinical association.¹

The characteristic facial expression can facilitate early detection of this disorder. The early institution of

prophylactic treatment in these cases may prevent the subsequent development of urinary tract deterioration. Failure to recognize patients with this disorder may lead to an unnecessarily complicated clinical course as was evident with our first patient. The incorrect diagnosis in this case resulted in unnecessary and ill advised surgery with the patient eventually going on to develop renal dysfunction. In addition, the positive family history for obstructive uropathy should have also raised suspicion for a possible hereditary form of bladder dysfunction. The basic therapeutic goals for cases detected early are the restoration of balanced bladder emptying and the prevention of upper urinary tract deterioration. Biofeedback is the mainstay of treatment in such patients. Drug therapy is usually guided by urodynamic findings. Laxatives are sometimes indicated in cases associated with constipation. Failure to adhere to these therapeutic principles may eventually put the child at risk for renal deterioration. Urinary diversion or bladder augmentation may provide the only alternative to prevent an ongoing deterioration of renal function.

In conclusion, UFS is more common than presently realized. Physicians dealing with voiding dysfunction should be aware of this syndrome and its features to facilitate early recognition. Early diagnosis and prompt treatment may prevent upper urinary tract deterioration. Further efforts are required in order to determine the specific neurologic lesion.

References

- Ochoa B, Gorlin RJ. Urofacial (ochoa) syndrome. *Am J Med Genet* 1987; 27: 661-667.
- Teebi AS, Farag TI, El-Khalifa MY, Bessiso MS, Al-Ansari AG. Urofacial syndrome. *Am J Med Genet* 1989; 34: 608.
- Teebi AS, Hassoon MM. Urofacial syndrome associated with hydrocephalus due to aqueductal stenosis. *Am J Med Genet* 1991; 40: 199-200.
- Ochoa B. The urofacial (Ochoa) syndrome revisited. *J Urol* 1992; 148: 580-583.
- Garcia-Minaur S, Oliver F, Yanez JM, Soriano JR, Quinn F, Reardon W. Three new European cases of urofacial (Ochoa) syndrome. *Clin Dysmorphol* 2001; 10: 165-170.
- Nicanor FA, Cook A, Pippi-Salle JL. Early Diagnosis of the urofacial syndrome is essential to prevent irreversible renal failure. *Int Braz J Urol* 2005; 31: 477-481.
- Hinman F, Baumann FW. Vesical and ureteral damage from voiding dysfunction in boys without neurologic or obstructive disease. 1973. *J Urol* 2002; 167: 1069-1074.
- Wang CY, Hawkins-Lee B, Ochoa B, Walker RD, She JX. Homozygosity and linkage-disequilibrium mapping of the urofacial (Ochoa) syndrome gene to a 1-cM interval on chromosome 10q23-q24. *Am J Hum Genet* 1997; 60: 1461-1467.