

# Minimally invasive retroperitoneal adrenalectomy

Hussam M. BinYousef, SBIS, ABIS, Mohammed A. Al-Zaben, FRCS, Essam M. Murshid, MD, FRCR (UK),  
Mona A. Al-Shahid, FRCR.

## ABSTRACT

The minimally invasive (MI) approach has become the gold standard in removing the adrenal gland. Both transperitoneal and retroperitoneal techniques were reported safe and effective. The retroperitoneal approach has the advantage of direct access to the gland, easy access to retrocaval tumors, carries no cardiovascular or pulmonary risk of carbon dioxide insufflation to a high intra-abdominal pressure, and is not affected by previous abdominal surgery or radiation. We report a case of MI retroperitoneal adrenalectomy for right adrenal incidentaloma in a recently diagnosed breast cancer patient with multiple medical problems, and emphasize the advantage of this approach over the MI transperitoneal approach in the presence of patient's co-morbidity.

*Saudi Med J 2007; Vol. 28 (12): 1901-1903*

*From the Departments of Surgery (BinYousef, Al-Zaben), Clinical Oncology (Murshid), and Radiology (Al-Shahid), Riyadh Military Hospital, Riyadh, Kingdom of Saudi Arabia.*

*Received 27th December 2006. Accepted 15th April 2007.*

*Address correspondence and reprint request to: Dr. Hussam M. BinYousef, Department of Surgery (567), Riyadh Military Hospital, PO Box 7897, Riyadh 11159, Kingdom of Saudi Arabia. Tel. +966 (1) 4777714 Ext. 25705. Fax. +966 (1) 4764265. E-mail: binyousef@hotmail.com or hbinyousef@rmb.med.sa*

Since the first report of adrenalectomy in 1889, this procedure continued to be of particular interest to surgeons. Initially, the surgical approach was anterior transperitoneal before the posterior retroperitoneal approach was introduced in 1932, and thereafter several open approaches were described.<sup>1</sup> When the minimally invasive (MI) started, adrenalectomy was first performed by Snow<sup>2</sup> in 1991, however, it was reported a year later by Gagner et al<sup>3</sup> and Higashihara et al<sup>4</sup> as the transperitoneal approach. Thereafter, the MI approach has become the gold standard for removing the adrenal gland. Gaur<sup>5</sup> performed MI lateral retroperitoneal approach, and Mercan et al<sup>6</sup> in 1993 performed MI posterior approach that was not described before 1995.

Both transperitoneal and retroperitoneal techniques were reported safe and effective. The choice between the 2 techniques depends mainly on the surgeon's preference and experience. In previous studies, the retroperitoneal approach has the advantage of direct access to the gland, easy access to retrocaval tumors, carries no cardiovascular or pulmonary risk of carbon dioxide (CO<sub>2</sub>) insufflation to a high intra-abdominal pressure, and is not affected by previous abdominal surgery or radiation.<sup>7-10</sup> In the Kingdom of Saudi Arabia (KSA), MI surgery has been well practiced since 1991. Laparoscopic transperitoneal adrenalectomy was reported in the literature,<sup>11-13</sup> however, there are no reports of MI retroperitoneal adrenalectomy from KSA. We report a case of MI retroperitoneal adrenalectomy for right adrenal incidentaloma in a recently diagnosed breast cancer patient with multiple medical problems, to emphasize the advantage of this approach over the MI transperitoneal approach in the presence of cardiovascular and pulmonary co-morbidity.

**Case Report.** A 57-year-old postmenopausal female presented with a painless right breast mass of 4 months duration that was increasing in size, without nipple and other associated symptoms. She has insulin-dependent diabetes mellitus (IDDM), hypertension on Amlodipine 5mg on demand (OD) and Atenolol 50mg OD, hyperlipidemia on Atorvastatin 40mg OD, and chronic obstructive pulmonary disease (COPD) on salbutamol and seretide inhaler. On physical examination, she is in fair general condition, blood pressure is stable, neck exam revealed no enlarged thyroid or lymph nodes, had bilateral wheezes, however, chest findings were all normal including cardiovascular, abdominal, and other systemic examinations. Local breast examination revealed a normal left breast and axilla, with a 4x4cm right breast mass at the upper inner quadrant that was mobile, non-tender, associated with skin tethering without nipple changes. There was a small mobile right axillary lymph node without supraclavicular lymph node.

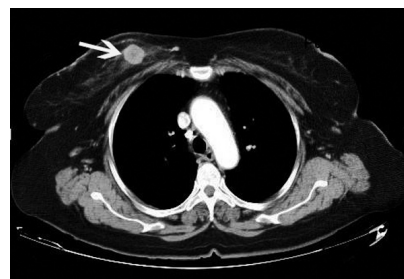**Investigations.** The general profile, liver, renal and thyroid function, and tumor markers (Cancer antigen (Ca) 19-9, Ca 125, Ca 15-3, and carcino-embryonic-antigen (CEA) were all in the normal

range. Bilateral mammogram and breast ultrasound showed a 2x2cm focal right breast mass suspicious for malignancy (**Figure 1**), the findings are in consistent with breast imaging-reporting and data system IV. Bone scan did not show any skeletal metastasis. The computed tomography (CT) scans of the chest and abdomen did not show any visceral metastasis, however, there was an incidental right adrenal mass (**Figure 2**), which is well defined and measured 2.5x2.5cm and has foci of calcification. Random serum cortisol level and 24-hour urinary catecholamine were normal. Right breast core needle biopsy reported as invasive ductal carcinoma, estrogen and progesterone receptor negative, while Her2 receptor positive.

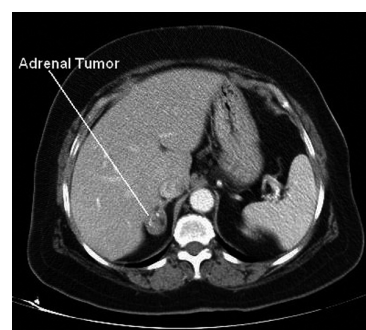
**Impression.** Two different pathologies, the presenting complaint is in the form of locally advanced breast cancer that has a clinical T2 N1 M0, and a right adrenal non-functioning incidentaloma. Although it is possible that the right adrenal mass is a metastatic lesion from breast cancer, a second pathology in the adrenal was more likely.

In view of her multiple medical problems (IDDM, hypertension, obesity, and COPD) and after a combined discussion between the clinical oncologist, endocrinologist, and surgeons the decision was to treat the primary breast malignancy according to the breast cancer guidelines, and to remove the right adrenal tumor to confirm the diagnosis of a second pathology or a metastatic disease. The options of performing additional tests such as MRI or image guided biopsy were also discussed, however evidence is not enough to support that additional tests will answer the question of metastatic lesion versus a harmless adrenal pathology. She underwent simultaneously a right breast conserving surgery and MI retroperitoneal right adrenalectomy.

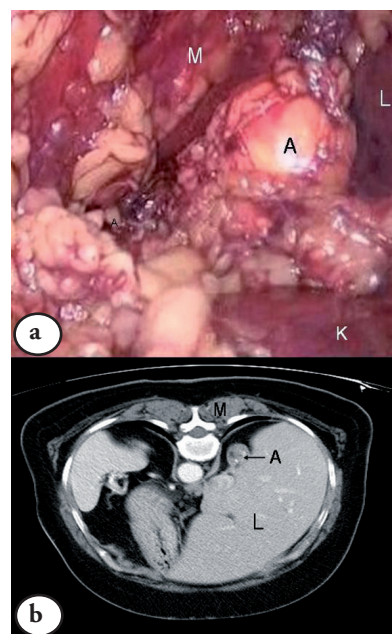
**Surgical procedure.** She was positioned prone with flexion of the thighs at 90°. The MI retroperitoneal right adrenalectomy was performed utilizing 2 ports sized 10mm and one port sized 5mm, a blunt dissection was initially used to create a retroperitoneal space under the 11th rib. The space is insufflated with CO<sub>2</sub> to a pressure of 20 mm Hg. A 30° scope was used for better visualization, and a 5 mm LigaSure vessel sealing and dividing instrument (Valleylab, Tyco, USA) to control the blood supply including the main vein; no clips or drains were used (**Figure 3**). The dissection starts by opening the Gerota fascia, the upper pole of the right kidney is identified inferiorly in the view, the vena cava is identified laterally, and the paraspinous muscle is identified medially. The adrenal gland with the surrounding fat is retracted upward and dissected away from the superior pole of the right kidney; the vascular pedicles are identified and controlled. The gland is then extracted from the abdomen in an endo-catch bag. She had simultaneously right breast conserving surgery (lumpectomy + axillary dissection).



**Figure 1** - Contrast enhanced computerized tomography of the chest showing a well defined enhancing mass in the right breast measuring 2 x 2 cm (arrow) consistent with the known primary breast tumor.



**Figure 2** - Contrast enhanced computerized tomography of upper abdomen showing a well defined right supra renal mass measuring 2.5 x 2.5 cm with foci of calcification.



**Figure 3** - Laparoscopic operative view a) A - right adrenal gland, K - right kidney, L - liver, M - erector spinaeus muscle, and b) corresponding axial computed tomography image (prone position), L - peritoneum covering the liver, M - erector spinaeus muscle, A - right adrenal gland.

She had a minimal postoperative pain, recovered well, and was discharged home the next day. The histopathology of the right adrenal was benign adenoma. She completed her treatment for breast cancer, and had no complications after one year of follow up.

**Discussion.** The dilemma in this case, was not the treatment of the primary pathology (breast cancer) rather the incidental right adrenal mass that was non-functional, and of uncertain nature. In the era of open surgery, such lesions were either biopsied or observed, and the risk of disseminating a malignant adrenal lesion by biopsy or having uncertain biopsy result may overcome the benefit. At present, such lesions can be easily removed following safe surgical oncology principles by MI surgery. We concluded that the presence of numerous co-morbid conditions particularly morbid obesity, hypertension, and pulmonary compromise make the retroperitoneal approach better than the transperitoneal approach, as it has the advantage of direct access to the gland and carries no cardiovascular or pulmonary risk as compared to the high intraperitoneal pressure and CO<sub>2</sub> absorption associated with the transperitoneal approach. A well-designed prospective study comparing both approaches to provide an evidence-based preference of either approach is needed.

## References

1. RB Webourn, editor. The History of Endocrine Surgery. New York (NY): Praeger; 1990.
2. Snow L, editor. 1st Laparoscopic Adrenalectomy. Mobile: Al Laser; 1991.
3. Gagner M, Lacroix A, Bolte E. Laparoscopic adrenalectomy in Cushing's syndrome and pheochromocytoma. *N Engl J Med* 1992; 327: 1033.
4. Higashihara E, Tanaka Y, Horie S, Aruga S, Nutahara K, Homma Y, et al. [A case report of laparoscopic adrenalectomy]. *Nippon Hinyokika Gakkai Zasshi* 1992; 83: 1130-1133. Japanese
5. Gaur DD. Laparoscopic operative retroperitoneoscopy: use of a new device. *J Urol* 1992; 148: 1137-1139.
6. Mercan S, Seven R, Ozarmagan S, Tezelman S. Endoscopic retroperitoneal adrenalectomy. *Surgery* 1995; 118: 1071-1076.
7. Rubinstein M, Gill IS, Aron M, Kilciler M, Meraney AM, Finelli A, et al. Prospective, randomized comparison of transperitoneal versus retroperitoneal laparoscopic adrenalectomy. *J Urol* 2005; 174: 442-445.
8. Gockel I, Kneist W, Heintz A, Beyer J, Junginger T. Endoscopic adrenalectomy: an analysis of the transperitoneal and retroperitoneal approaches and results of a prospective follow-up study. *Surg Endosc* 2005; 19: 569-573.
9. Chiu AW. Laparoscopic retroperitoneal adrenalectomy: clinical experience with 120 consecutive cases. *Asian J Surg* 2003; 26: 139-144.
10. Viterbo R, Greenberg RE, Al-Saleem T, Uzzo RG. Prior abdominal surgery and radiation do not complicate the retroperitoneoscopic approach to the kidney or adrenal gland. *J Urol* 2005; 174: 446-450.
11. Yousef HB, Al Zahrani A, Ahmed M, Al Arifi A, Mahfouz A, Hussain R, et al. *Ann Saudi Med* 2003; 23: 36-38.
12. Khairy GA, Fouda M, Abdulkarim A, Al-Saigh A, Al-Kattan K. A new era in laparoscopic surgery. Evaluation of robot-assisted laparoscopic procedures. *Saudi Med J* 2005; 26: 777-780.
13. Kadamba P, Habib Z, Rossi L. Experience with laparoscopic adrenalectomy in children. Experience with laparoscopic adrenalectomy in children. *J Pediatr Surg* 2004; 39: 764-767.

## Case Reports

Case reports will only be considered for unusual topics that add something new to the literature. All Case Reports should include at least one figure. Written informed consent for publication must accompany any photograph in which the subject can be identified. Figures should be submitted with a 300 dpi resolution when submitting electronically or printed on high-contrast glossy paper when submitting print copies. The abstract should be unstructured, and the introductory section should always include the objective and reason why the author is presenting this particular case. References should be up to date, preferably not exceeding 15.