

Aggressive primary thyroid non Hodgkin's lymphoma with pregnancy

Khaled B. Soliman, MD, Mohamed M. Abbas, ABOG, Mahmoud A. Seksaka, MD, Sherief Wafa, MD, Ahmed S. Balah, MD.

ABSTRACT

We present here a multigravida patient who presented with a huge neck swelling, severe respiratory distress together with dysphagia and hoarseness of voice while she was pregnant \pm 30 weeks of gestation. She was diagnosed as an aggressive non-Hodgkin lymphoma of the thyroid gland. She was treated by 6 cycles of chemotherapy, with dramatic response after receiving the first cycle. She had 3 cycles of 4 chemotherapeutic agents before successful, elective and scheduled induction of labor at 36 weeks of gestation with favorable outcomes.

Saudi Med J 2007; Vol. 28 (4): 634-636

From the Department of Obstetrics and Gynecology, Maternity and Children Hospital, Buraidah, Qassim, Kingdom of Saudi Arabia.

Received 15th May 2006. Accepted 27th August 2006.

Address correspondence and reprint request to: Dr. Khaled B. Soliman, Department of Obstetrics and Gynecology, King Abdul-Aziz Specialist Hospital, PO 10127, Taif, Kingdom of Saudi Arabia. Tel. +966 508219100. Fax. +966 (2) 7310801. E-mail: khaled_b_s@yahoo.com

The overall incidence of non-Hodgkin's lymphoma (NHL) complicating pregnancy has not been accurately determined. There is a speculation that there is a hormonal influence on this form of cancer in pregnant patients. Others speculate that there is a relation between the physiological state of immunosuppression during gestation and the aggressive nature of these tumors. Lymphomas are highly chemotherapy sensitive malignancies. New researches reported that, there is no increased risk of preterm delivery, and chemotherapy seems to be safe if started after the first trimester of pregnancy. The late effects of in-utero exposure to chemotherapy during pregnancy has been studied without evidence of congenital malformations at birth. Termination of pregnancy might make the cancer easier to treat, because the case becomes less complicated, but it is not thought to improve prognosis.

Case Report. A 35-years-old woman, gravida 4, para 3, unbooked, presented with severe dyspnea, dysphagia,

hoarseness of voice together with a huge anterior neck swelling. By date she was 30 weeks and 2 days of gestation. Her medical and obstetric histories were unremarkable. The swelling started as a small nodule 2 x 2cm, increased slowly over 2 months, then rapidly increased in size over the past 2 weeks. The swelling was associated with hoarseness of her voice, generalized weakness, anorexia and marked weight loss. Generally, she had severe dyspnea, agitation and with marked stridor, (pulse 120/min, blood pressure 110/70 mm Hg, temperature 37.5°C, RR 30/min). There was a huge thyroid mass of >25 x 15cm, firm, not tender, lobulated surface with multiple superficial dilated veins and it was moving with deglutition. The lower border reached the suprasternal notch with no palpable cervical lymph nodes. Abdominal examination, the fundal level was \pm 28 weeks of gestation with positive fetal heart sounds. She was admitted in the intensive care unit (ICU), for stabilization, evaluation, diagnosis and further management. In ICU she was intubated and ventilated. Laboratory investigations were, Oxygen saturation 95%, hemoglobin 10.3 g/dl, white blood cells $11.1 \times 10^9/l$, platelets $193 \times 10^9/l$, blood urea nitrogen 7.3 mmol/l, creatinine 100 mmol/l, protein 7.2 g/dl, S.Ca 2.42 mmol/l, thyroid-stimulating hormone (n) 3.26 un/l, thyroxine 10.45 ug/dl, triiodothyronine (low) 1.95 pmol/l and lactate dehydrogenase (high) 530 IU/l]. X-ray chest, was normal with deviation of the trachea to the left side. Abdominal ultrasonography revealed a singleton, alive fetus 28 weeks \pm 4 days. Liver, spleen and both kidneys were normal. Ultrasonography of thyroid gland revealed a homogenous mass, involving both lobes neither hemorrhage nor cysts were found, with areas of necrosis. Fine needle aspiration, revealed a high grade, diffuse large B-cell NHL of the thyroid gland (**Figure 1**). After 2 days in ICU, she became stable and shifted to the high dependence unit.

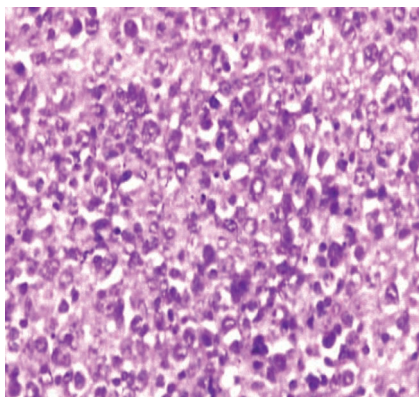


Figure 1 - Modified view showing neoplastic lymphoma cells with pleomorphism with mitotic figures (Hematoxylin & eosin stain x400).

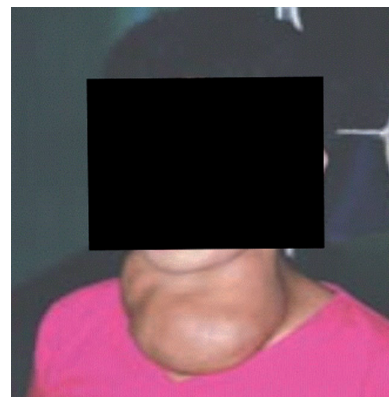

Figure 2 - Clinical improvement of the case after the first cycle of 6 cycles of chemotherapy.

The oncologist, obstetrician and surgeon decided an immediate plan of chemotherapy of cyclophosphamide, doxorubicin, vincristine, and prednisone (CHOP), 6 cycles, 3 weeks apart. She agreed and tolerated the first cycle well. She had an about 50% reduction in the size of the mass within 48 hours with complete disappearance of dyspnea and dysphagia but the hoarseness of voice showed little improvement (**Figure 2**). The patient was discharged after 10 days of hospitalization, in a fair condition with a plan of antenatal care and scheduled 5 cycles of chemotherapy. She had uneventful antenatal visits at a weekly basis. Before delivery, she received 2 more cycles of chemotherapy. She had an induction of labor, at completed 36 weeks of gestation by using prostaglandin E₂, as in our protocol. She delivered normally, a healthy baby girl 2.4 kg without congenital anomalies. She was discharged in the second postpartum day in a good condition and the thyroid mass was almost 5x5 cm. She was advised to complete the scheduled chemotherapeutic cycles, to prevent breast-feeding and to have contraception for life. She received her fourth cycle of chemotherapy, 2 weeks after delivery. Eight weeks after delivery, she was doing well and an IUCD was inserted. Six months after delivery, she remained in clinical and radiological complete response and the thyroid mass was almost 1x2 cm.

Discussion. To the best of our knowledge, we describe for the first time, a unique presentation of an aggressive primary NHL of the thyroid gland during pregnancy, successfully treated by chemotherapy with favorable outcomes. The incidence of NHL has been steadily increasing worldwide over the past 50 years. Although some cases are associated with immunodeficiency, autoimmunity, or viral infections, in most cases the causes of NHL are not understood.¹ Non-Hodgkin's lymphoma occurring during pregnancy

is rare, it has a grim prognosis, because it is most often associated with disseminated disease and aggressive tumor characteristics.² Worldwide, men are reported to have a higher incidence of NHL than women.³ The reasons for the lower NHL rates among females are not known, and few epidemiologic studies have examined factors that might explain this difference in risk. The information currently available suggests that oral contraceptive use may decrease the risk, and estrogen replacement therapy may increase the risk.⁴ Whether parity affects risk or not, is unclear. Olsson et al,⁵ found that late age at first full-term pregnancy was associated with increased risk of NHL, whereas Adami et al,⁶ observed no such relationship, while also noting a weak negative association with increasing parity. A relationship between immune function and reproductive hormones is well established and may also serve to influence the development of cancer in pregnant patients.⁷ Others speculate that there is a connection between the physiological state of immunosuppression during gestation and the aggressive nature of these tumors.⁸ Thus, multiple changes in immune reactivity have been described in women during pregnancy⁹ and also in the nonpregnant state.¹⁰ It is possible that, during pregnancy, higher, release of cytokines, interleukin-10 levels, which are known to be a potent growth factor for high and intermediate grade NHL,¹¹ may cause a transient increase in risk of lymphoma during gestation; however, interleukin-10 may also inhibit the synthesis of IL-6, thus serving to diminish the potential for any relationship between pregnancy and development of NHL.¹² Diffuse large cell NHL lymphomas are highly chemotherapy-sensitive malignancies. Treatment with conventional combination chemotherapy produces complete remission, cure rates of 50-70% and disease-free survival rates of approximately 50%.¹³ When cancer is diagnosed during pregnancy, the mother-to-be

faces a difficult choice between treating the cancer at once, having a termination, or risking both her's and her unborn child's life, by choosing to wait until the baby is delivered. However, there is no increased risk of preterm delivery, and chemotherapy seems to be safe if started after the first trimester of pregnancy. Timing of treatment is also important as a woman should not give birth within 3 weeks of chemotherapy.¹⁴ Moreover, long-term outcomes of NHL, treated aggressively with combination chemotherapy during pregnancy are favorable.¹⁵ There is an urge for the oncologists and obstetricians to work together in caring for pregnant patients with cancer.

Acknowledgement. The authors acknowledge with deep gratitude the patient and staff who cared for her. We are also indebted to Ms Maria Luisa C. David for her valuable secretarial help.

References

1. Lens NB, Newton JA. Association between cutaneous melanoma and non-Hodgkin's lymphoma: pooled analysis of published data with a review. *Ann Oncol* 2005; 16: 460-465.
2. Ward FT, Weiss RB. Lymphoma and pregnancy. *Semin Oncol* 1989; 16: 397-409.
3. Scherr PA, Mueller NE. In: Schottenfeld D, Fraumeni JF, editors. Non-Hodgkin's lymphomas, Cancer Epidemiology and Prevention. New York (NY): Oxford University Press; 1996. p. 920-945.
4. Rebecca AN, Alexandra ML, Leslie B. Reproductive factors and risk of intermediate- or high-grade B-cell non-Hodgkin's lymphoma in women. *J Clin Oncol* 2001; 19: 1381-1387.
5. Olsson H, Olsson ML, Ranstam J. Late age at first full-term pregnancy as a risk factor for women with malignant lymphoma. *Neoplasms* 1990; 37: 185-190.
6. Adami HO, Tsaih S, Lambe M, Hsieh C, Adami J, Trichopoulos D, et al. Pregnancy and risk of non-Hodgkin's lymphoma: A prospective study. *Int J Cancer* 1997; 70: 155-158.
7. Ioachim HL. Non-Hodgkin's lymphoma in pregnancy: Three cases and review of the literature. *Arch Pathol Lab* 1985; 109: 803-809.
8. Valemzuela PL, Montalban C, Matorras R, Nieto A, Gonzales A, Perera S. Pregnancy and relapse of peripheral T cell lymphoma. *Gynecol Obstet Invest* 1991; 32: 59-61.
9. Glassman AB, Bennett CE, Christopher JB, Self S. Immunity during pregnancy: lymphocyte subpopulations and mitogen responsiveness. *Ann Clin Lab Sci* 1985; 15: 357-362.
10. Helgason S, von Schoultz B. Estrogen replacement therapy and the mixed lymphocyte reaction. *Am J Obstet Gynecol* 1981; 141: 393-397.
11. Janet S. Chemotherapy safe in pregnancy. *Lancet Oncol* 2002; 3: 128.
12. Aviles A, Diaz-Maqueo JC, Torras V, Garcia EL, Guzman R. Non-Hodgkin's lymphomas and pregnancy: Presentation of 16 cases. *Gynecol Oncol* 1990; 37: 335-337.
13. Rodriguez J, Caballero MD, Gutierrez A, Solano C, Arranz R, Lahuerta JJ, et al. Autologous stem-cell transplantation in diffuse large B-cell non-Hodgkin's lymphoma not achieving complete response after induction chemotherapy: the GEL/TAMO experience. *Ann Oncol* 2004; 15: 1504-1509.
14. Shipp MA, Yeap BY, Harrington DP, Klatt MM, Pinkus GS, Jochelson MS, et al. The m-BACOD combination chemotherapy regimen in large-cell lymphoma: Analysis of the completed trial and comparison with the M-BACOD regimen. *J Clin Oncol* 1990; 8: 84-93.
15. Guglielmi C, Amadori S, Martelli M, Dragoni F, Mandelli F. The F-MACHOP sequential combination chemotherapy regimen in advanced diffuse aggressive lymphomas: Long-term results. *Ann Oncol* 1991; 2: 365-371.