

# Effects of intraarticular contrast media on synovial membrane and cartilage

## *An electron microscopic evaluation in rabbit knees*

Nusret Kose, MD, Ulukan Inan, MD, Cengiz Baycu, PhD, Hakan Omeroglu, MD, Sinan Seber, MD.

### ABSTRACT

**Objectives:** To evaluate the histological and ultrastructural alterations in rabbit knee joint cartilage and synovia induced by intraarticular injections of 2 water soluble contrast agents.

**Methods:** The study was conducted at the Department of Orthopedics and Traumatology, Medical Faculty, Osmangazi University, Eskisehir, Turkey in January 2002. To examine the effect of contrast agents on articular cartilage and synovial membrane, rabbit model was used. Specimens from 62 knee joints were examined by light microscopy and transmission electron microscopy one hour, one day, one week and 2 weeks after intraarticular administration of gadolinium-diethylenetriamine pentaacetic acid, iopromide or saline.

**Results:** In the knees injected with saline, light microscopic changes of the synovium consisted of edema only. Edema and hyperemia were seen in contrast agent injected knees. Ultrastructurally, numerous and large pinocytotic vesicles in A cells of the synovial membrane were seen in contrast agent injected groups. In the knees injected with saline the cartilage were ultrastructurally normal but contrast agent injected knees showed increased activation of chondrocytes with increase of dense glycogen accumulation, large lipid vacuoles and matrix material. There were very rare pycnotic cells in these samples. The rating scale has been used and the means of the total scores were determined for the groups.

**Conclusions:** The effects of contrast agents reduced gradually on the cartilage and synovium in general but did not become completely normal in the observation period.

*Saudi Med J 2007; Vol. 28 (5): 713-716*

*From the Department of Orthopedics and Traumatology (Kose, Inan, Omeroglu, Seber), Department of Histology (Baycu), Eskisehir Osmangazi University Faculty of Medicine, Meselik, Eskisehir, and the Department of Orthopedics and Traumatology (Omeroglu), Faculty of Medicine, Ufuk University, Ankara, Turkey.*

*Received 8th October 2006. Accepted 31st December 2006.*

*Address correspondence and reprint request to: Dr. Nusret Kose, Associate Professor of Orthopedics and Traumatology, Department of Orthopedics and Traumatology, Faculty of Medicine, Eskisehir Osmangazi University, Meselik, Eskisehir 26480, Turkey. Tel. +90 (222) 2392979. Fax. +90 (222) 2393774. E-mail: nkose@ogu.edu.tr*

Arthrography continues to be a valuable examination technique in the imaging of joint disorders in spite of the introduction and spread of modern imaging techniques such as ultrasound, computed tomography and magnetic resonance imaging (MRI). It can be used on children and elderly patients without reservation.

Prior to clinical use, a contrast agent has to pass through a group of clinical testing with step-wise advancement for safety reasons. There is universal consensus that the contrast agents, especially new generation of radio-opaque contrast agents, are comfortable and safer for the patient.<sup>1</sup> In the literature, the studies have focused on acute toxicity and adverse reactions of the contrast agents.<sup>2</sup> With regard to local effects, unfortunately more limited data are available. Although previous studies have demonstrated histological changes in some tissues resulting from exposure to contrast material, little attention has been directed to pathological abnormalities of the synovial membrane and cartilage following injection of contrast material into the joint.<sup>3-5</sup>

The purpose of the current study was to evaluate the histological and ultrastructural alterations in rabbit knee joint cartilage and synovia, induced by intraarticular injections of 2 water soluble contrast agents, gadolinium-diethylenetriamine pentaacetic acid (gd-DTPA) and iopromide.

**Methods.** The study was conducted at the Department of Orthopedics and Traumatology, Medical Faculty, Osmangazi University, Eskisehir, Turkey in January 2002. This study has been approved by the institutional ethics committee and principles of laboratory animal care were followed. Sixty two healthy mature

rabbits weighing 2.5-3 kg were used in the study. The study was carried out under general anesthesia, induced with intramuscular ketamine hydrochloride (Ketalar) (50 mg/kg). Animals were randomly divided into 3 groups as dimeglumine, iopromide and control groups. After surgical preparation of a small area over the knee joint, an aseptic puncture was performed using 24-gauge, 19 mm disposable needles. Needle placement in the joint space was verified by aspiration of synovial fluid. In 20 rabbits, the right knees were injected with 1 ml of gd-DTPA (Magnevist®). In another 20 rabbits, the right knees were injected with 1 ml of iopromide (Ultravist®). The remainder 20 knees served as control and injected with 1 ml saline.

Gadopentetate dimeglumine is the N-methylglucamine salt of the gadolinium complex of DTPA, and is an injectable contrast medium for MRI. Iopromide is a nonionic, iodinated, low-osmolar radiological contrast agent recommended especially for intravascular administration.

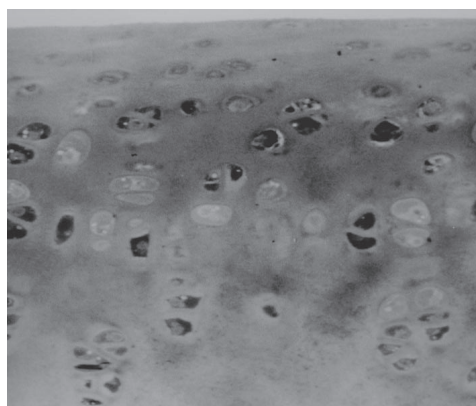
The groups of animals were observed in cages. The animals, 5 in each group, were killed with intraperitoneal high dose sodium thiopental after 1 hour, 1 day, 1 week and 2 weeks. By the same aseptic technique biopsies of the synovial membrane and articular cartilage were obtained for histologic examination via knee arthrotomy. Specimen were placed in 5% glutaraldehyde with phosphate buffer solution and fixed for overnight at +5°C temperature. Tissues were postfixed in 1% osmium tetroxide solution for 1 hour. Tissues were dehydrated using graded alcohol and embedded in Araldite. Semi-thin sections were stained with toluidine blue and examined under light microscopy (Olympus PM10-ADS). Selected areas were routinely prepared for transmission electron microscopy and examined using Jeol 1220 EM with 80 kV. The histologist had no knowledge of the material injected or how long after injection the animal had been killed. In the 2 rabbits, which had not received any intraarticular injections, the cartilage and the synovium of the knees were examined to determine the normal appearance.

Each histological change in tissues was rated semi-quantitatively on a scale of 0 to 3. Zero represented a normal appearance, 1 minimum, 2 moderate and 3 severe changes. Study groups and control group were compared to evaluate the effects of the contrast media on the synovial membrane and joint cartilage. Statistical significance between individual test groups was determined by Mann-Whitney U test, with *p*-value less than 0.05 considered significant.

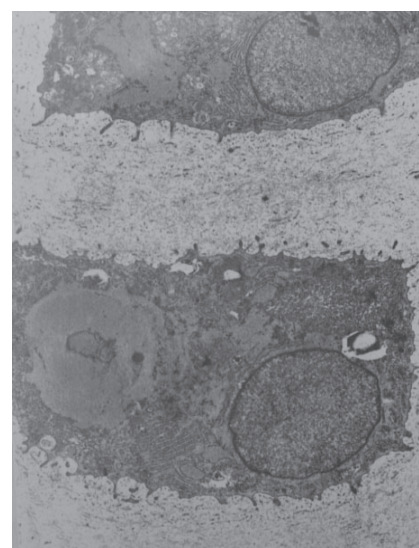
**Results.** All animals survived the entire duration of the study. On clinical observation rabbits appeared

normal. None of the rabbits had infection on their knee joints visually. In the knees injected with saline, or contrast media the cartilage and synovium appeared normal on gross pathological examination.

**Light microscopy.** In the knees injected with saline only minimal hypertrophic chondrocytes were observed in the cartilage tissue in the first week. In the knees injected with iopromide and dimeglumine, many changes were observed in the cartilage tissue such as hypertrophy of chondrocytes, accumulation of dense glycogen, and weak glycosaminoglycan staining of matrix material in the first week (**Figure 1**). Very rare pycnotic chondrocytes were also seen. These findings decreased gradually by the second weeks. No superficial erosion, pannus or grouping of chondrocytes were observed on any samples.



**Figure 1** - Densely stained glycogen in chondrocytes of dimeglumine injected group.



**Figure 2** - Dense glycogen accumulation and darkly stained chondrocyte after 1 week dimeglumine injection.

Light microscopic changes of the synovium consisted of edema and hyperemia in the first hours in iopromide and dimeglumine injected groups. Hyperemia persisted slightly in the first and second weeks. Synovial membrane was histologically intact. In the knees injected with SF light microscopic changes of the synovium consisted of edema only.

**Electron microscopy.** In the knees injected with SF the cartilage were ultrastructurally normal. Whereas in those injected with dimeglumine and iopromide increased activation of chondrocytes with increase of glycogen accumulation, large lipid vacuoles and matrix material were observed (**Figure 2-3**). These observed changes were not severe. Ultrastructurally, numerous and large pinocytotic vesicles in A cells of synovial membrane were seen in contrast agent injected groups (**Figure 4**).

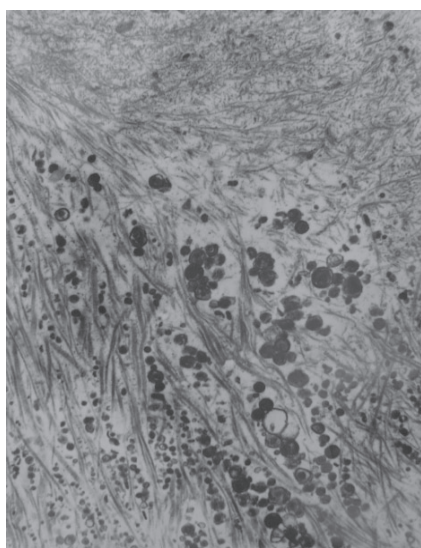
The rating scale for each histological change in tissues on the light microscopic examination has been used and the means of the total scores were determined for the groups. The effects of these contrast agents reduced gradually on the cartilage and synovium in general but did not become normal completely. The mean score of dimeglumine elevated from 0.7-2.7 in 7 days and reduced to 2 in 14 days while the mean score of iopromide reduced from 2.7-1.7 in 14 days on cartilage. The paired comparisons between dimeglumine, iopromide and control revealed no significant difference between groups at 1 hour, 1 day, 1 week and 2 weeks after injection ( $p > 0.05$ ).

**Discussion.** To improve the accuracy of visualization in the diagnosis of joint disorders, intraarticular injection

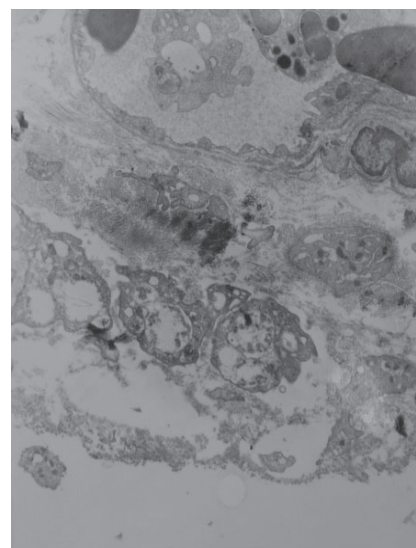
of the contrast agents has been used frequently in clinical practice. The most important physicochemical properties of contrast agents are their solubility, viscosity, osmolality, hydrophilia, and electrical charge.<sup>1</sup> There are 2 components to contrast media toxicity; high osmolality and chemotoxicity.<sup>6</sup> Mild and transient post-procedural pain and swelling are not uncommon following arthrography. These symptoms and signs have been attributed to a possible irritant effect of contrast media on the synovium, a decrease in the pH of the joint fluid, or joint distension provoked by additional influx of fluid into an already distended joint.<sup>1,3</sup>

In the literature the effect of various contrast agents have been studied almost exclusively from a clinical point of view. Direct observations are rare. Although it is considered safe for systemic use of water-soluble contrast media, toxicities in some tissues have been identified. Gabelmann et al<sup>7</sup> reported that ionic contrast agents lead to reversible transient focal endothelial cell injury following intraaortic injection. Despite their widespread use in musculoskeletal diagnosis, contrast agents have received relatively little attention on their effect on cartilage and synovial membrane after intra-articular administration.

In one study to determine whether the contrast medium- after being incorporated into the hyaline articular cartilage- was stored in the chondrocytes, uptake experiments were carried out in vitro on rabbit knee-joint cartilage with radioactive contrast media. One fourth of the original radioactivity of the medium was found in the innermost layer after 48 hours. These experiments showed that gadolinium is taken up completely into the hyaline cartilage, and that this



**Figure 3** - Increased of matrix material in dimeglumine injected group.



**Figure 4** - Numerous and large pinocytotic vesicle in A cells of synovial membrane.

process is time-dependent. The contrast medium is similarly taken up into the cartilage matrix.<sup>8</sup>

Few studies have examined the toxicity of contrast media on articular cartilage and synovium. Rahmouni et al<sup>9</sup> found that cell viability, measured by uptake of neutral red, was decreased by a suprathreshold concentration of a contrast agent. Safety of intraarticular contrast media was examined in another study, where solution of Gd-DTPA were injected into rabbit knees. Gross inspection and light microscopy revealed some focal hyperplasia of the synovium and focal mononuclear infiltrate of the synovium in some knees a few hours after injection with uncertain significance.<sup>4</sup> Greisberg et al<sup>10</sup> have shown that exposure to contrast agents can alter chondrocyte matrix production and cellular proliferation, and can also induce apoptosis of chondrocytes at the concentrations used for arthrography in monolayer cell cultures.

In this study, the observed changes when correlated with those that had been demonstrated by electron microscopy showed that intraarticular injections of contrast media produce histological and ultrastructural alterations in rabbit knee joint cartilage and synovium. The effects of these contrast agents reduced gradually on the cartilage and synovium in general but did not become normal completely. In this study, adverse local effects of contrast agents have been demonstrated by high dose exposure in rabbit joint cartilage. This effect would be of more concern if injection into an immature joint was performed. We are aware of the limitations of our experimental model. In fact, the low number of animals examined in each group restricted the statistical significance of the results. But it is possible that contrast media effects may have been underestimated to some

degree. Further work is needed to determine if these effects are of clinical importance.

## References

1. Stacul F. Current iodinated contrast media. *Eur Radiol* 2001; 11: 690-697.
2. Goldstein HA, Kashanian FK, Blumetti RF, Holyoak WL, Hugo FP, Blumenfeld DM. Safety assessment of gadopentetate dimeglumine in U.S. clinical trials. *Radiology* 1990; 174: 17-23.
3. Pastershank SP, Resnick D, Niwayama G, Danzig L, Haghighi P. The effect of water-soluble contrast media on the synovial membrane. *Radiology* 1982; 143: 331-334.
4. Hajek PC, Sartorius DJ, Gylys-Morin V, Haghighi P, Engel A, Kramer F, et al. The effect of intra-articular gadolinium-DTPA on synovial membrane and cartilage. *Invest Radiol* 1990; 25: 179-183.
5. Corbetti F, Malatesta V, Camposampiero A, Mazzi A, Punzi L, Angelini F, et al. Knee arthrography: effects of various contrast media and epinephrine on synovial fluid. *Radiology* 1986; 161: 195-198.
6. Dawson P. Structure - Toxicity relationships and molecular design. In: Contrast Media in Practice. Dawson P, Clauß W, editors. Berlin: Springer Verlag; 1994. p. 11-12.
7. Gabelmann A, Haberstroh J, Weyrich G. Ionic and non-ionic contrast agent-mediated endothelial injury. Quantitative analysis of cell proliferation during endothelial repair. *Acta Radiol* 2001; 42: 422-425.
8. Engel A. Magnetic resonance knee arthrography. Enhanced contrast by gadolinium complex in the rabbit and in humans. *Acta Orthop Scand* 1990; 240: 1-57.
9. Rahmouni A, Mathieu D, Chambou C, Dao TH, Hernigou P, Vasile N. Intraarticular tolerability and kinetics of gadolinium tetra-azacyclododecane tetraacetic acid. *Acad Radiol* 1995; 2: 413-417.
10. Greisberg JK, Wolf JM, Wyman J, Zou L, Terek RM. Gadolinium inhibits thymidine incorporation and induces apoptosis in chondrocytes. *J Orthop Res* 2001; 19: 797-801.

### Related topics

Al-Shukaili AK, Al-Jabri AA. Rheumatoid arthritis, cytokines and hypoxia. What is the link? *Saudi Med J* 2006; 27: 1642-1649.

Vidyadhara S, Rao SK, Rao S. Discoid medial meniscus. Varied presentation of 3 knees. *Saudi Med J* 2006; 27: 888-891.

Atilla B, Atilla P, Tokgozoglu AM, Cakar AN, Alpaslan AM. Immunohistochemical evaluation of periprosthetic membrane from loose cemented and uncemented total hip arthroplasty. *Saudi Med J* 2005; 26: 429-433.