Clinical Quiz

Mohammed A. Yassin, *MD.*
Specialist, Department of Medicine, Hamad General Hospital, PO Box 3050, Doha, Qatar.
Fax. +974 4392273 E-mail: yassin160@yahoo.co.uk

Notice: Authors are encouraged to submit quizzes for possible publication in the Journal. These may be in any specialty, and should approximately follow the format used here (maximum of 2 figures). Please address any submissions to: Editor, Saudi Medical Journal, Armed Forces Hospital, PO Box 7897, Riyadh 11159, Kingdom of Saudi Arabia. Tel. +966 (1) 4777714 Ext. 6570. Fax. +966 (1) 4761810 or 4777194

Ovarian hyper stimulation syndrome

Clinical Presentation

A 23-year-old Qatari female, pregnant (after induction of ovulation), presented with shortness of breath and increased abdominal girth.

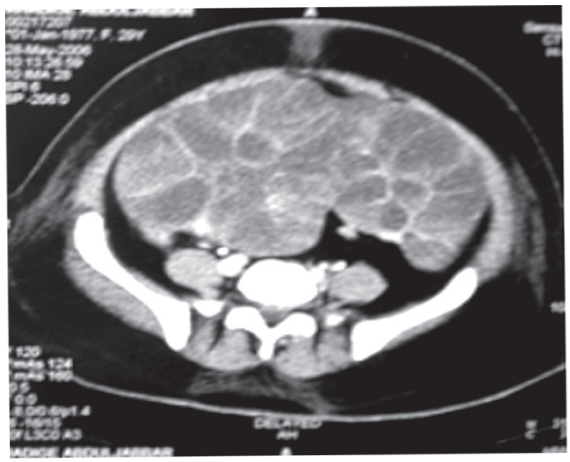

Figure 1-

Questions

1. What organ is involved?
2. What is your diagnosis?

Clinical Quiz

Answers

1. These are hyper stimulated ovaries.
2. Ovarian hyper stimulation syndrome.

Discussion

Most of the problems resulting from gonadotropin therapy for induction of ovulation are related to the development, luteinization, and ovulation of multiple follicles. The 2 most serious complications of excessive ovarian stimulation are high incidence of multiple gestation and ovarian hyperstimulation syndrome (OHSS). Ovarian hyperstimulation syndrome refers to a combination of ovarian enlargement due to multiple ovarian cysts and an acute fluid shift out of the intravascular space. It is a potentially life-threatening complication of ovulation induction. Ovarian hyper stimulation is classified into 3 grades based upon the severity of symptoms, signs, and laboratory findings.[1] The cardinal event in the genesis of OHSS is ovarian enlargement, with ascites and hypovolemia resulting from an acute fluid shift out of the intravascular space. Ovarian hyperstimulation syndrome is a self-limiting disease; thus, treatment should be symptomatic and conservative. Medical therapy suffices for most patients, with laparotomy reserved for catastrophic complications, such as ovarian torsion or rupture and internal hemorrhage. Women with severe symptoms often require intensive medical care. Vaginal intercourse is restricted in all grades of OHSS due to the risk of cyst rupture. Patients should also avoid impact-type activities or strenuous exertion, and if it is a mild treatment, it is supportive, as needed; and if it is moderate, the treatment consist of observation, bed rest, provision of an adequate fluid, and sonographic monitoring of cyst size. Serum electrolytes, hematocrit, and creatinine should also be evaluated. Some physicians have outpatients keep track of their fluid intake and output; intake or output less than 1000 mL/day or a discrepancy in fluid balance greater than 1000 mL/day would be a cause for concern.[2]

Medical treatment of severe hyperstimulation is directed toward maintaining blood volume while correcting the disturbed fluid and electrolyte balance relieving secondary complications of ascites and hydrothorax, preventing thromboembolic phenomena.

References

1. Lunenfeld B, Insler V, Glezerman M. Diagnosis and treatment of functional infertility. 3rd ed. Berlin: Blackwell Wissenschaft; 1993. p. 98.
2. Whelan JG, Vlahos NF. The ovarian hyperstimulation syndrome. *Fertil Steril* 2000 73: 883-896.