

# Imaging of peripheral arteries by 16-slice computed tomography angiography

*A valuable tool?*

Anuj Mishra, MD, FRCR, Ehtuish F. Ehtuish, MSc, PhD.

## ABSTRACT

**Objective:** To evaluate the efficacy of multidetector (16-row) computed tomography (MDCT) in imaging the upper and lower limb arterial tree in trauma and peripheral vascular disease.

**Methods:** Thirty three patients underwent multislice computed tomography angiography (MSCTA) of the upper or the lower limb on multislice (16-slice) CT scanner between November 2004 and July 2005 in the Department of Radiology, National Organ Transplant Center, Tripoli, Libya. The findings were retrospectively compared with the surgical outcome in cases of trauma with suspected arterial injuries; or color Doppler correlation was obtained, for patients of peripheral vascular disease.

**Results:** Multislice computed tomography angiography allows a comprehensive diagnostic work-up in all trauma cases with suspected arterial injuries. In 23 cases of peripheral vascular diseases, MSCTA adequately demonstrated the presence of any stenosis or occlusion, its degree and extent, the presence of collaterals and distal reformation if any; the presence of plaques.

**Conclusion:** Our experience of computed tomography angiography with 16-row MDCT scanner has clearly demonstrated its efficacy as a promising, new, fast, accurate, safe and non-invasive imaging modality of choice in cases of trauma with suspected arterial injuries; and as a useful screening modality in cases of peripheral vascular diseases for diagnosis and for grading.

*Saudi Med J 2007; Vol. 28 (7): 1091-1095*

*From the Department of Radiology (Mishra), and the Department of Surgery (Ehtuish), National Organ Transplant Program, Tripoli, Libyan Arab Jamahiriya, Libya.*

*Address correspondence and reprint request to: Dr. Anuj Mishra, PO Box 7913, Ainzara, Al-Furnaz, Tripoli, Libyan Arab Jamahiriya, Libya. Tel. +218 (21) 3620188. Fax. +218 (21) 3620189. E-mail: dranujmish@yahoo.com*

The availability of the 'state-of-the-art' technology of (16-row) multidetector computed tomography MDCT scanner has revolutionized the evaluation of the peripheral vasculature in our institution, especially in diabetics. As diabetes being so common in our country, this has begun to make a significant impact in the diagnosis and treatment of such cases. It is indeed the beginning of a new and exciting journey and our initial experience of 33 patients in the last 9 months has successfully guided the surgeons' knife with a correlating outcome. Evaluation of peripheral vasculature is an integral part in the management of patients with peripheral vascular disease, polytrauma patients with suspected vascular injury, and in patients with bone and soft tissue tumors. The traditional means of evaluating vascular anatomy with conventional angiography was slowly replaced by digital subtraction angiography (DSA). Although considered as a 'gold standard' in the evaluation of peripheral vessels, especially peripheral vascular disease, the role of DSA has now been challenged by recent advances in technology like color Doppler, multislice computed tomography angiography (MSCTA) and contrast enhanced magnetic resonance angiography (MRA). Though not considered a primary vascular imaging modality till a few years ago, computed tomography angiography (CTA) has experienced a technological quantum leap with the introduction of MDCT and has gained widespread acceptance in the imaging of the aorta, carotid, renal and iliac vessels. The introduction of multiple detectors with isotropic imaging capabilities has enabled MSCTA to surpass even MRA with regard to spatial resolution. We present our analysis regarding the efficacy of 16-row MDCT in the evaluation of peripheral

vasculature. The MDCT 16-slice scanner can obtain 16 slices of data in a single gantry rotation. This allows for a dramatic increase in speed as well as linear coverage, thinner sections of entire anatomic territories; and at the same time eliminates misregistration and respiratory artifacts, thereby achieving volumetric imaging.

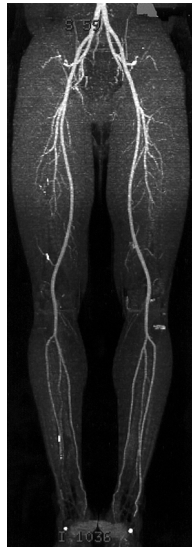**Methods.** From November 2004 to July 2005, 33 patients underwent peripheral MSCTA in the Department of Radiology, Tripoli Central Hospital, Libya, of whom 23 patients had suspected peripheral vascular disease and 10 patients had a history of trauma. Of these 33 patients, 20 were male and 13 were female, in a wide age group ranging from 24 years to 75 years. Twenty eight patients underwent lower limb MSCTA while the remaining 5 patients had upper limb MSCTA. All patients were scanned on the Lightspeed Pro 16-slice CT scanner (General Electric GE, USA), in supine position with head first for upper limb and feet first for lower limb evaluation. The scan direction was cranio-caudal for lower limb CTA, with the scan range from the level of infra-renal aorta to the pedal arch; while for upper limb CTA the scan direction was caudo-cranial from the level of tip of shoulder to the palmar arch. A 150 cc of non-ionic contrast medium (Inj. Iohexol 300) was injected at a rate of 3 cc/second with a dual-head pressure injector (Medrad, USA) followed by a 20 cc bolus of saline chase. The images were acquired with a slice thickness of 3 mm and a collimation of 2.5 mm with a pitch of 1.5-2. The success of any CTA depends on the calculation of an accurate delay to start the acquisition of images after the injection of contrast, to get optimum arterial enhancement, not contaminated by the venous phase. In our study, the optimum delay was calculated by automatic 'smart prep' software (General Electric, USA), wherein the machine automatically starts scanning once the level of peak contrast enhancement in the aorta reaches a preset value of 60-70 Hounsfield units(HU). The images thus, acquired were then processed on a separate 3-dimensional workstation ('Advantage Windows' by GE, USA). The thinner images were reconstructed with 50% overlap. Different advanced 3-dimensional techniques were used like maximum intensity projection, shaded surface display and volume rendering. Due to the size of generated dataset, considerable time was required for image reconstruction, and this remained a major limitation of the current technique.

**Results.** In all of our 33 patients, there has been no technical failure. The procedure was well tolerated by all patients and in no study was there image degradation due to motion artifacts. The images acquired in all the patients were true diagnostic images. The CTA was

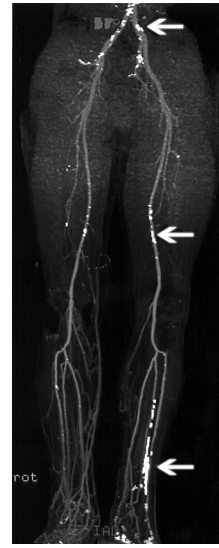normal in 2 patients (6.06%) (Figure 1). An obvious vessel contusion was seen in 3 patients (9.09%) with resultant complete block and failure of opacification of the distal vessels. In 5 patients (15.15%), there was compression of the vessel seen due to fracture segment pressing on the vessel (n=1), due to 'mass effect' from the surrounding soft tissue edema or hematoma (n=2) (Figure 2) and due to vasospasm (n=2). Thirteen patients (39.4%) showed diffuse narrowing of the vessels with calcific plaques (Figure 3) while 10 patients (30.3%) showed hemodynamically significant stenosis or occlusion of the arterial lumen (Figure 4). All patients with normal CTA study or with the diagnosis of vasospasm were managed conservatively.

**Discussion.** Helical CT has improved over the past 8 years with faster gantry rotation, more powerful x-ray tubes, and improved reconstruction algorithms, but the greatest advance has been the introduction of MDCT scanners. Fundamental advantages of MDCT include substantially shorter scan times, high spatial resolution, increased anatomic coverage and improved 3-dimensional rendering.<sup>1</sup> The greatest impact of this has been on CTA.

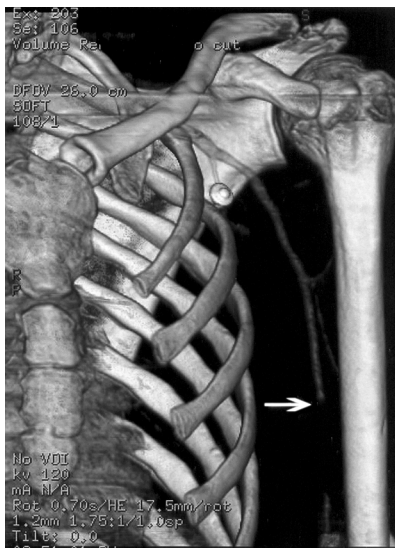
The aim of CTA in peripheral vascular disease patients is to delineate the presence or absence of significant obstruction to blood flow, the site and anatomical extent of obstruction, the status of collateral flow and distal vasculature; for planning treatment as well as to monitor the results of therapy and disease progression. The cause of peripheral vascular disease in all our positive 23 patients was seen to be atherosclerosis. Other rarer causes of peripheral vascular disease like vascular aneurysms, cystic adventitial disease or popliteal entrapment syndrome were not seen in any of the cases, although, submillimeter sections were reconstructed<sup>2</sup> and optimal volume of intravenous contrast was used.<sup>3</sup> Mesurole et al<sup>4</sup> in 2004 compared CTA with catheter angiography and concluded that helical CT was inconclusive in 6.2% of segments, whereas catheter angiography in 5% and the CTA was seen to have 91% sensitivity, 93% specificity. Romano et al<sup>5</sup> in 2004 reported a sensitivity and specificity of 93% and 95% respectively<sup>6</sup> with an overall diagnostic accuracy of 94%. Axial sections yielded the most correct results and should always be reviewed additionally.<sup>7</sup> In all our peripheral vascular disease patients, MSCTA was successful in establishing the exact location and extent of the block as well as the nature of the block. Multislice computed tomography angiography also gave information on the formation of collaterals and distal reformation, as correlated by color Doppler studies. The main advantage of MSCTA over DSA is in the detection and characterization of atherosclerotic plaques and the presence or absence



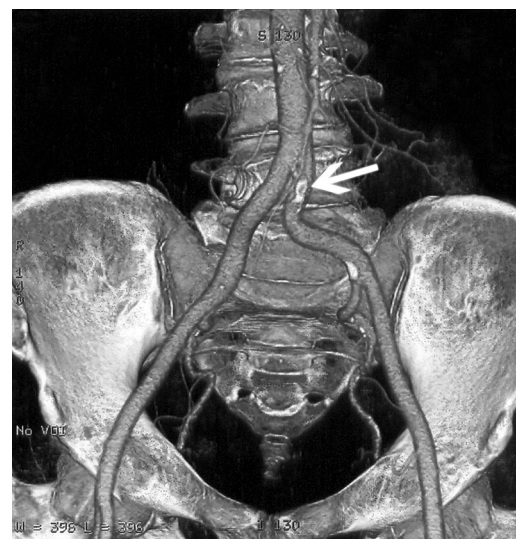**Figure 1** - Maximum intensity projection image showing the normal arterial tree of the lower extremities.



**Figure 3** - Maximum intensity projection image showing multiple calcific plaques (arrows) lining the arterial tree.



**Figure 2** - Volume rendered 3-dimensional image showing short-segment unopacified arterial lumen due to extrinsic compression by hematoma (arrow).



**Figure 4** - Three-dimensional volume rendered image shows calcific plaques in left common iliac artery with focal stenosis (arrow).

of calcification within it.<sup>8</sup> This is significant as heterogeneous plaques are more prone to calcify while the soft plaques are more prone to dislodge and throw an embolus. In addition, by being able to more clearly define a plaque and its morphology, the effect of various therapies on progression or regression of the plaques can be monitored. However, the presence of very heavy calcification is a disadvantage for CTA,<sup>9</sup> as the vessels are then not adequately evaluated due to blooming artifacts, especially in smaller caliber vessels, beyond the level of the knee.<sup>10</sup> However, with the development of newer software algorithms, this drawback would be overcome very soon. The additional benefit of cross-

sectional CT in simultaneously depicting extraluminal structures causing arterial obstruction, as in popliteal artery entrapment or cystic adventitial disease cannot be overemphasized. The major disadvantage of CTA, however, is the radiation dose and the absence of any hemodynamic assessment, which is obtained by color Doppler and MRA. In spite of these limitations, CTA is being increasingly used as a screening modality for initial assessment of the presence of vascular disease, its extent and severity, thereby allowing interventional radiologists and vascular surgeons to plan the most appropriate therapeutic method, reducing unnecessary intervention or possible intra-operative difficulty.

Multislice computed tomography angiography helped in comprehensive diagnostic work-up of trauma patients within a critically short time. Moreover, associated bone fractures, soft tissue injury and injury of other visceral organs were demonstrated in the same sitting. Thus, it is easy to see why MSCTA has such tremendous growth prospects as a distinct diagnostic imaging modality in recent years. Apart from the fact that the radiation dose is 4 times less in MSCTA as compared to DSA,<sup>11,12</sup> the former is faster, non-invasive and combines luminal information provided by conventional angiography with the advantages of cross-sectional imaging.<sup>13</sup> The use of non-invasive multi-detector row CTA instead of DSA as the initial diagnostic imaging test for peripheral arterial disease provides sufficient information for therapeutic decision making and reduces imaging costs.<sup>14</sup> Non-invasive screening of lower limb arterial disease has long been performed using color Doppler ultrasonography<sup>15</sup> and is the initial imaging modality of choice in suspected peripheral vascular disease, but it has few drawbacks. It is operator dependent, and fails to demonstrate direct evidence of cystic adventitial or popliteal entrapment syndrome. In contrast, CTA is less operator dependent and is clearly of advantage in patients with trauma that are often immobilized and in intense pain. Surgeons prefer CT images to Doppler images as they are presented in a format similar to conventional angiograms with which they are more familiar and comfortable. The main competitor to MSCTA is contrast-enhanced dynamic MRA.<sup>16</sup> Both modalities have similar z-axis resolution, however, MRA has an advantage by the fact that it is unaffected by the presence of vascular calcification. In addition, MRA is a good imaging modality for evaluation of the distal anterior tibial, peroneal and dorsalis pedis arteries. However, CTA scores over MRA by being much faster, less expensive, more widely available, with better patient compliance and with the absence of retrograde flow artifacts. It is also a modality of choice in patients with MR incompatible hardware, indwelling stents and in severely claustrophobic patients. The major drawback of CTA is the large amount of intravenous contrast and the ionizing radiation involved.<sup>17</sup> Also, no information is obtained regarding the flow direction and velocity. In addition, CTA may fail to demonstrate short segment stenosis, apart from the fact that horizontally oriented branches are poorly visualized. Despite these limitations, the vast majority of examinations we performed were considered sufficiently diagnostic to avoid more invasive imaging. Multidetector row CTA appears consistent and accurate in the assessment of patients with peripheral arterial occlusive disease.<sup>18</sup>

Our initial experience of CTA with 16-slice MDCT has shown that it is a promising, new, fast, accurate and non-invasive imaging modality that can be utilized

effectively in the evaluation of peripheral vasculature. It has given nearly 100% intra-operative correlation in patients of trauma and correlating confirmatory Doppler findings in patients of peripheral vascular diseases. The contrast and the radiation dose was well tolerated by all the patients and the image quality obtained was comparable to intra-arterial DSA. Some of the inherent limitations of the technique and the time consumed in post-processing can be overcome with faster workstation and technology advances. Thus, it would be most appropriate to conclude that 16-row MSCTA is clearly emerging as a screening tool in patients of peripheral vascular disease, while in trauma patients with suspected vascular injury, this is the imaging modality of choice. The high spatial resolution and relatively non-invasive nature make MSCTA a strong and serious competitor to established vascular imaging techniques.

**Acknowledgment.** We wish to express our sincere thanks to Dr. Jahnvi N. Bhaktarahalli, MD, for lending invaluable aid in the manuscript preparation and data analysis.

## References

1. Hiatt MD, Fleischmann D, Hellinger JC, Rubin GD. Angiographic imaging of the lower extremities with multidetector CT. *Radiol Clin North Am* 2005; 43: 1119–1127.
2. Schertler T, Wildermuth S, Alkadhi H, Kruppa M, Marincek B, Boehm T. Sixteen-detector row CT angiography for lower-leg arterial occlusive disease: analysis of section width. *Radiology* 2005; 237: 649–656.
3. Meyer BC, Ribbe C, Kruschewski M, Wolf KJ, Albrecht T. 16-row multidetector CT angiography of the aortoiliac system and lower extremity arteries: contrast enhancement and image quality using a standardized examination protocol. *Rofa* 2005; 177: 1562–1570.
4. Mesurolle B, Qanadli SD, El Hajjam M, Goeau-Brissonniere OA, Mignon F, Lacombe P. Occlusive arterial disease of abdominal aorta and lower extremities: comparison of helical CT angiography with transcatheter angiography. *Clin Imaging* 2004; 28: 252–260.
5. Romano M, Mainenti PP, Imbriaco M, Amato B, Markabaoui K, Tamburrini O, et al. Multidetector row CT angiography of the abdominal aorta and lower extremities in patients with peripheral arterial occlusive disease: diagnostic accuracy and interobserver agreement. *Eur J Radiol* 2004; 50: 303–308.
6. Romano M, Amato B, Markabaoui K, Tamburrini O, Salvatore M. Multidetector row computed tomographic angiography of the abdominal aorta and lower limbs arteries. A new diagnostic tool in patients with peripheral arterial occlusive disease. *Minerva Cardioangiol* 2004; 52: 9–17.
7. Portugaller HR, Schoellnast H, Hausegger KA, Tiesenhausen K, Amann W, Berghold A. Multislice spiral CT angiography in peripheral arterial occlusive disease: a valuable tool in detecting significant arterial lumen narrowing? *Eur Radiol* 2004; 14: 1681–1687.
8. Duddalwar VA. Multislice CT angiography: a practical guide to CT angiography in vascular imaging and intervention. *Br J Radiol* 2004; 77: S27–S38.

9. Heuschmid M, Krieger A, Beierlein W, Luz O, Kuettner A, Kopp AF, et al. Assessment of peripheral arterial occlusive disease: comparison of multislice-CT angiography (MS-CTA) and intraarterial digital subtraction angiography (IA-DSA). *Eur J Med Res* 2003; 8: 389–396.
10. Lawler LP, Fishman EK. Multidetector row computed tomography of the aorta and peripheral arteries. *Cardiol Clin* 2003; 21: 607–629.
11. Edwards AJ, Wells IP, Roobottom CA. Multidetector row CT angiography of the lower limb arteries: a prospective comparison of volume-rendered techniques and intra-arterial digital subtraction angiography. *Clin Radiol* 2005; 60: 85–95.
12. Adriaensen ME, Kock MC, Stijnen T, van Sambeek MR, van Urk H, Pattynama PM, et al. Peripheral arterial disease: therapeutic confidence of CT versus digital subtraction angiography and effects on additional imaging recommendations. *Radiology* 2004; 233: 385–391.
13. Willmann JK, Baumert B, Schertler T, Wildermuth S, Pfammatter T, Verdun FR, et al. Aortoiliac and lower extremity arteries assessed with 16-detector row CT angiography: prospective comparison with digital subtraction angiography. *Radiology* 2005; 236: 1083–1093.
14. Koch MC, Adriaensen ME, Pattynama PM, van Sambeek MR, van Urk H, Stijnen T, et al. DSA versus multi-detector row CT angiography in peripheral arterial disease: randomized controlled trial. *Radiology* 2005; 237: 727–737.
15. Laissy JP, Pernes JM. Imaging of the lower limb arteries : when, how and why ? *J Radiol* 2004; 85: 845–850.
16. Ouwendijk R, de Vries M, Pattynama PM, van Sambeek MR, de Haan MW, Stijnen T, et al. Imaging peripheral arterial disease: a randomized controlled trial comparing contrast-enhanced MR angiography and multi-detector row CT angiography. *Radiology* 2005; 236: 1094–1103.
17. Jakobs TF, Wintersperger BJ, Becker CR. MDCT-imaging of peripheral arterial disease. *Semin Ultrasound CT MR* 2004; 25: 145–155.
18. Catalano C, Fraioli F, Laghi A, Napoli A, Bezzi M, Pediconi F, et al. Infrarenal aortic and lower-extremity arterial disease: diagnostic performance of multi-detector row CT angiography. *Radiology* 2004; 231: 555–563.

### *Illustrations, Figures, Photographs*

Four copies of all figures or photographs should be included with the submitted manuscript. Figures submitted electronically should be in JPEG or TIFF format with a 300 dpi minimum resolution and in grayscale or CMYK (not RGB). Printed submissions should be on high-contrast glossy paper, and must be unmounted and untrimmed, with a preferred size between 4 x 5 inches and 5 x 7 inches (10 x 13 cm and 13 x 18 cm). The figure number, name of first author and an arrow indicating “top” should be typed on a gummed label and affixed to the back of each illustration. If arrows are used these should appear in a different color to the background color. Titles and detailed explanations belong in the legends, which should be submitted on a separate sheet, and not on the illustrations themselves. Written informed consent for publication must accompany any photograph in which the subject can be identified. Written copyright permission, from the publishers, must accompany any illustration that has been previously published. Photographs will be accepted at the discretion of the Editorial Board.