

Surgical management of hepatocellular carcinoma

Liver resection and liver transplantation

Kiyoshi Hasegawa, MD, PhD, Norihiro Kokudo, MD, PhD, Masatoshi Makuuchi, MD, PhD.

ABSTRACT

Although remarkable progress has been made in the treatment of hepatocellular carcinoma (HCC), local control is still the most important consideration. Liver resection is and will continue to be the first-line therapeutic modality for local control of a primary HCC, including cases with intrahepatic metastases. For a large HCC, or multiple HCCs with vascular invasion, aggressive liver resection must be pursued. In cases with poor liver functional reserve, liver transplantation would be a good therapeutic option, after considering age, and tumor-related factors. To prevent deterioration of the liver function should be the second priority in the treatment of HCC. As for liver resection, extensive removal of the non-cancerous parenchyma, such as lobectomy and hemihepatectomy, should be avoided as much as possible. Anatomic resection, which involves systematic elimination of the main tumor with its minute metastases and preserves liver function, is strongly recommended. The treatment algorithm, which is based on evidence picked up from published papers, is now available and useful to determine the therapeutic choice depending on the tumor- and liver function-related conditions.

Saudi Med J 2007; Vol. 28 (8): 1171-1179

From the Department of Surgery, Hepato-Biliary-Pancreatic Surgery Division, Graduate School of Medicine, University of Tokyo, Tokyo, Japan.

Address correspondence and reprint request to: Dr. Masatoshi Makuuchi, Department of Surgery, Hepato-Biliary-Pancreatic Surgery Division, Graduate School of Medicine, University of Tokyo, 7-3-1, Hongo, Bunkyo-ku, Tokyo 113-8655, Japan. Tel. +81 (3) 5800-8654. Fax. +81 (3) 5684-3989. E-mail: makuuchi-ky@umin.ac.jp

Liver resection, liver transplantation, percutaneous ablation, and transcatheter arterial chemoembolization (TACE) are now established as effective treatment modalities for hepatocellular carcinoma (HCC). The nationwide survey conducted by the Liver Cancer Study Group of Japan indicated

that liver resection would be superior to percutaneous ablation and TACE.^{1,2} Although its superiority is not confirmed by a randomized controlled trial, liver resection should be initially considered as a treatment of HCC, if the liver function is well-preserved. Candidates with liver function not adequate for liver resection and not-so advanced cancer (namely, in accordance with the Milan criteria)³ may be good candidates for liver transplantation, except for patients more than 60 years of age. Percutaneous ablation (ethanol injection, microwave coagulation, and radiofrequency ablation) may be considered in patients who are suitable for neither resection nor transplantation. Although TACE is inferior to resection and ablation for the local control of HCC, it has a great advantage in that it can be performed in cases of poor liver function or multiple tumors in the bilateral liver lobes. In this article, we summarize the recent findings and results regarding the surgical management strategies (liver resection and transplantation) for HCC.

Liver resection. Liver resection, which is the most effective approach for the local control of HCC, is the first treatment modality of choice, if liver function is well preserved.

Indication. The indications and procedure of liver resection are determined primarily by the liver function, and the tumor location, and number. The treatment algorithm (**Figure 1**),^{4,5} recommends that if the degree of liver damage is grade A or B, liver resection is the first-line indication for HCC with 3 or less nodules, regardless of tumor size. It is of utmost importance to accurately evaluate the liver functions preoperatively. The Child-Pugh classification, which is a rough method of such evaluation, is popular in the West. In the East, the indocyanine green retention at 15 minutes (ICG-R15) value is regarded as important, and allows more accurate evaluation.^{6,7} Especially in Japan, the criteria consisting of the ICG-R15 value, ascites and jaundice are widely accepted (**Figure 2**).⁸ Based on these criteria, the maximum permissible volume of the liver that can

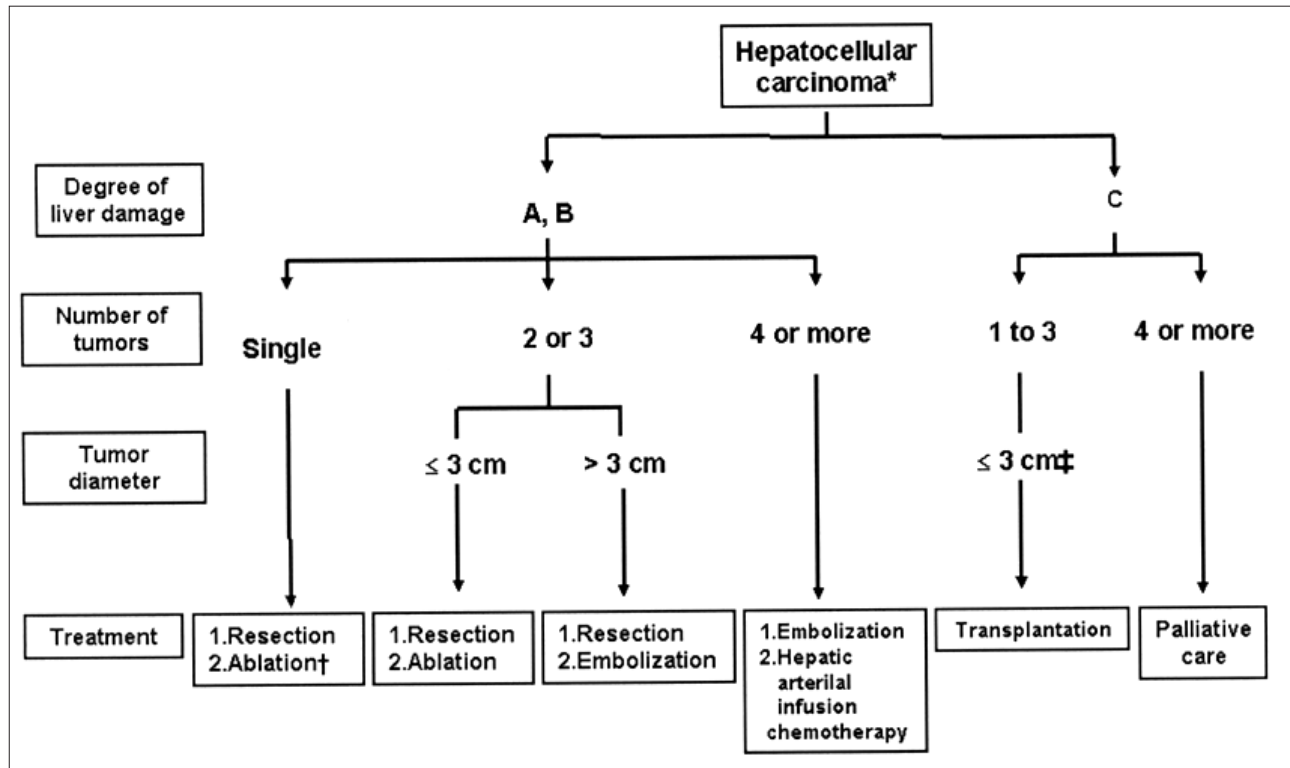


Figure 1 - Treatment algorithm for hepatocellular carcinoma (reproduced from reference 4, with permission). *Presence of vascular invasion or extrahepatic metastasis to be indicated separately. †Selected when the severity of liver damage is class B and tumor diameter is ≤ 2 cm. ‡Tumor diameter ≤ 5 cm when there is only one tumor.

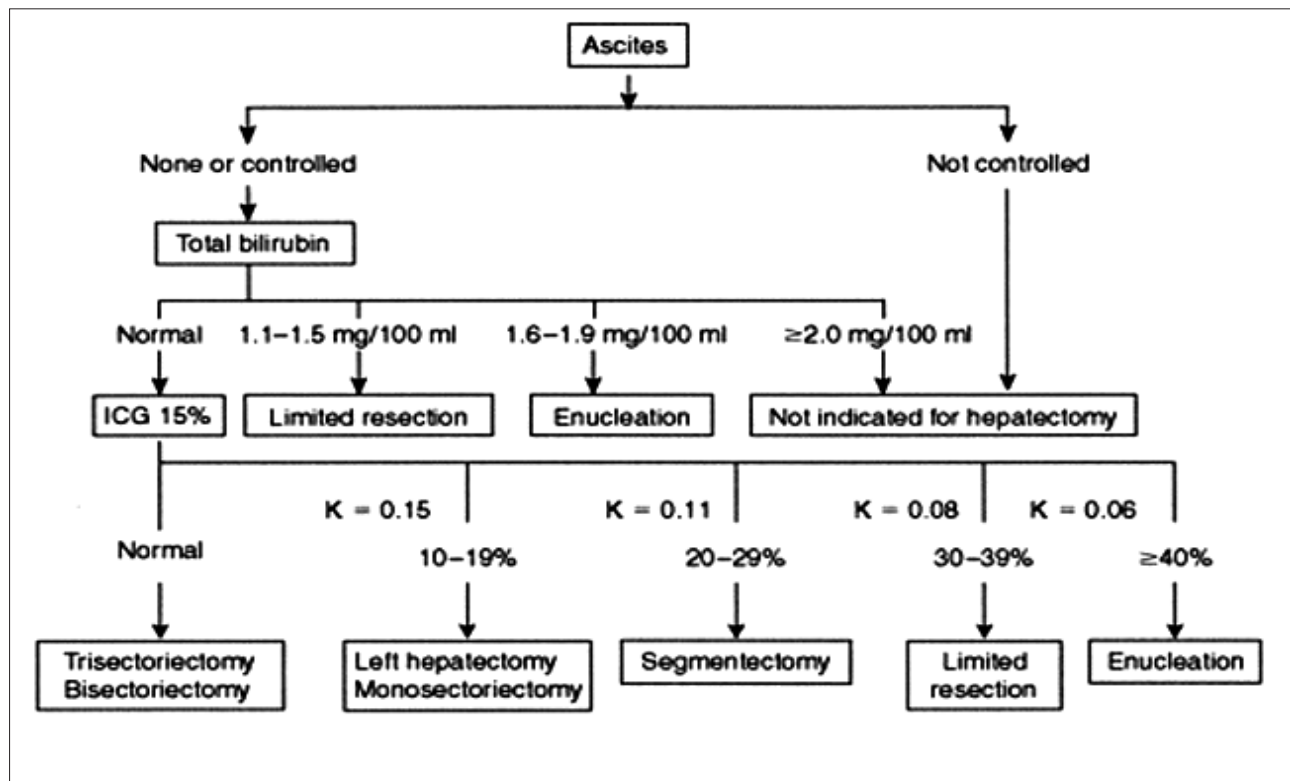


Figure 2 - A decision tree for selection of operative procedures in patients with hepatocellular carcinoma (reproduced from reference 8, with permission).

be resected is estimated and based, in turn, on this estimation, an operative procedure is determined.

Short-term outcomes. The safety of liver resection is now established. According to the 16th report of the Liver Cancer Study Group of Japan in 2000-2001, the mortality in patients undergoing liver resection for HCC was 1.6%.¹ Some high-volume centers from the East have reported zero mortality.^{9,10} Accurate preoperative evaluation of liver function, appropriate selection of the appropriate operative procedure, and advances in perioperative management have all contributed to the excellent short-term outcomes.

Long-term outcomes. The overall 3-, 5-, and 10-year survival rates after liver resection for HCC have been reported as 70.5%, 54.6%, and 28.9%.¹ The high incidence of recurrence is a serious problem in the treatment of HCC. Even after curative resection, the incidence of recurrence at 3 and 5 years postoperatively has been shown to be approximately 50-60% and 70-100%,¹¹⁻¹⁶ and in 80% of these cases, the recurrence occurs in the liver. Thus, the means to cope with intrahepatic recurrences constitutes an important consideration in the treatment of HCC. The therapeutic

choices for recurrence are the same as those for primary HCC, namely, liver resection, transplantation, ablation, and TACE. As the 3-year survival rate has been shown to be acceptable (approximately 80%) after repeated resection, liver resection still remains the first-line choice.^{15,16} The indication for repeated liver resection and the operative procedure are determined based on the same criteria as those for the first surgery, estimation of the liver function and tumor-related factors.

Variations of liver resection. When the liver volume resected exceeds the estimated permissible amount, the risk of postoperative liver failure is increased, which is critical. However, complete and systematic removal of a segment entirely containing the tumor-bearing portal branches would be desirable to prevent recurrence due to dissemination of the cancerous cells through the portal venous system (**Figure 3a**).¹⁷ Anatomic liver resection satisfies both of the above conflicting propositions (**Figure 3b**).¹⁷ Recent retrospective studies have shown that anatomic resection is superior to non-anatomic resection for a single HCC (**Figure 4**).^{18,19} As long as the liver function is adequate, anatomic resection should be selected as the surgical procedure for HCC. Vascular invasion, including portal vein tumor thrombus (PVTT) and intrahepatic metastasis, is the strongest prognostic factor in patients treated for HCC. Neither liver transplantation nor percutaneous ablation is contraindicated in cases of advanced HCC with PVTT. However, if liver functions are well preserved (ICG-R15 <20%), the combination of TACE and subsequent liver resection can yield a 5-year survival rate of 42%.²⁰ In the absence of vascular invasion, 3- and 5-year survival rates after liver resection for giant HCCs larger than 10cm in diameter have been reported to be 51.1% and 38.2%.²¹ Liver resection should be aggressively pursued in cases of advanced HCC. Portal vein embolization has been applied in cases of HCC as a preparative procedure before extensive resection of the liver parenchyma.^{22,23} This might contribute to the expansion of the indications of liver resection for HCC.

Liver transplantation. Liver transplantation is theoretically reasonable, because it can eliminate not only the existing HCC, but also involves removal of the pre-cancerous damaged liver itself. Candidates with liver function not adequate for liver resection and not-so advanced cancer may be good candidates for liver transplantation, except for patients older than 65 years.

Limits of liver transplantation. The most crucial problem associated with liver transplantation for HCC is recurrence. The incidence of post-transplantation recurrence is not rare, and the prognosis in such cases of recurrence is rather poor, perhaps attributable to immunosuppression. Thus, the indications for liver transplantation in cases of HCC should be limited by

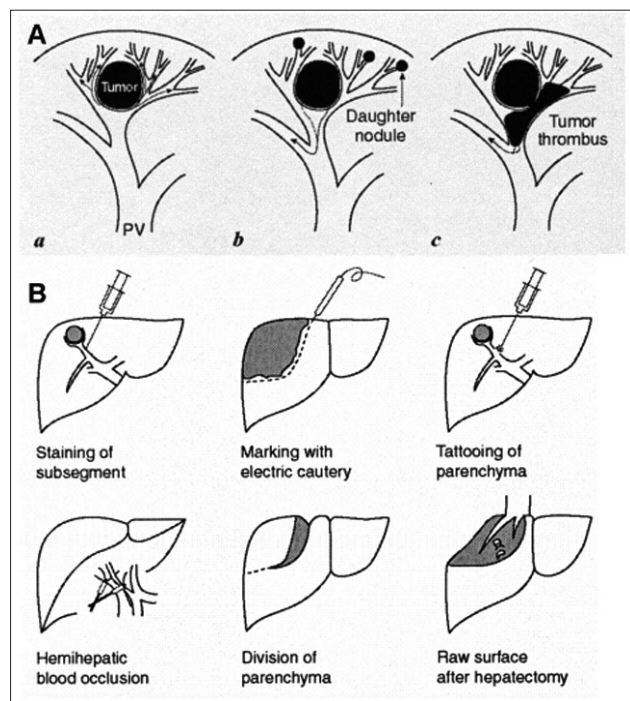
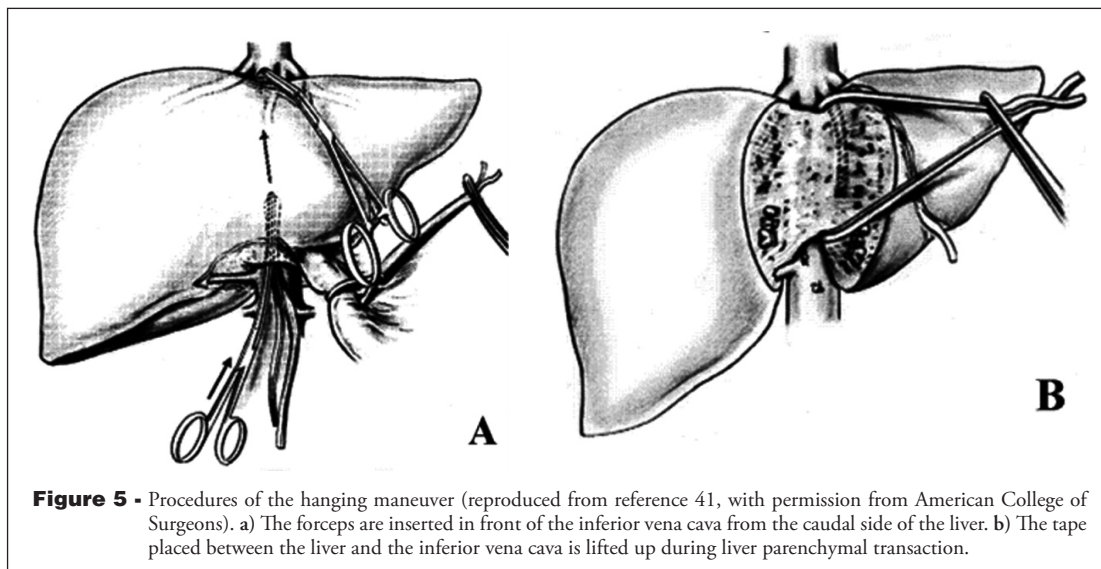
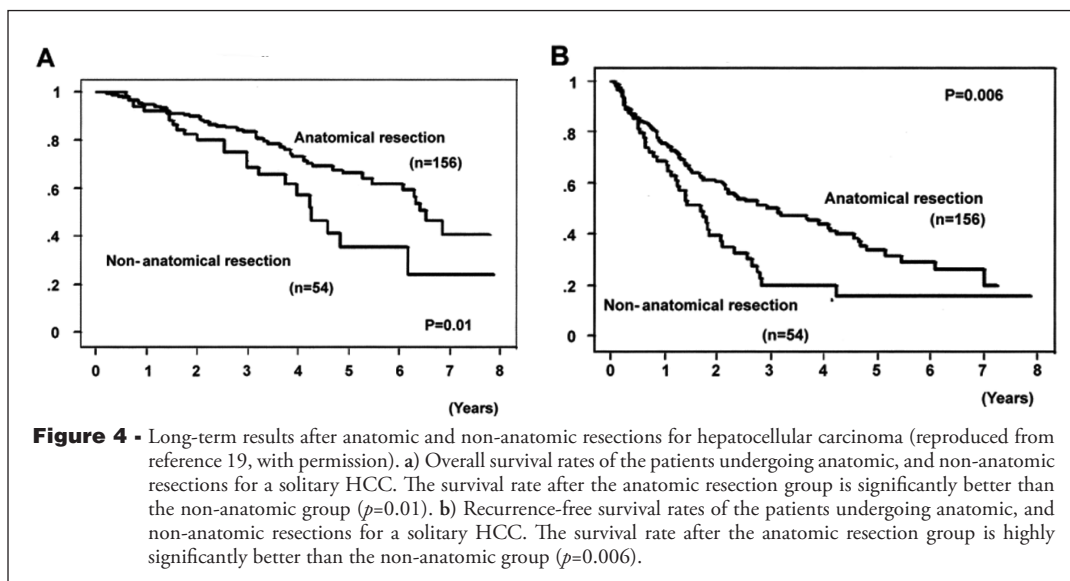


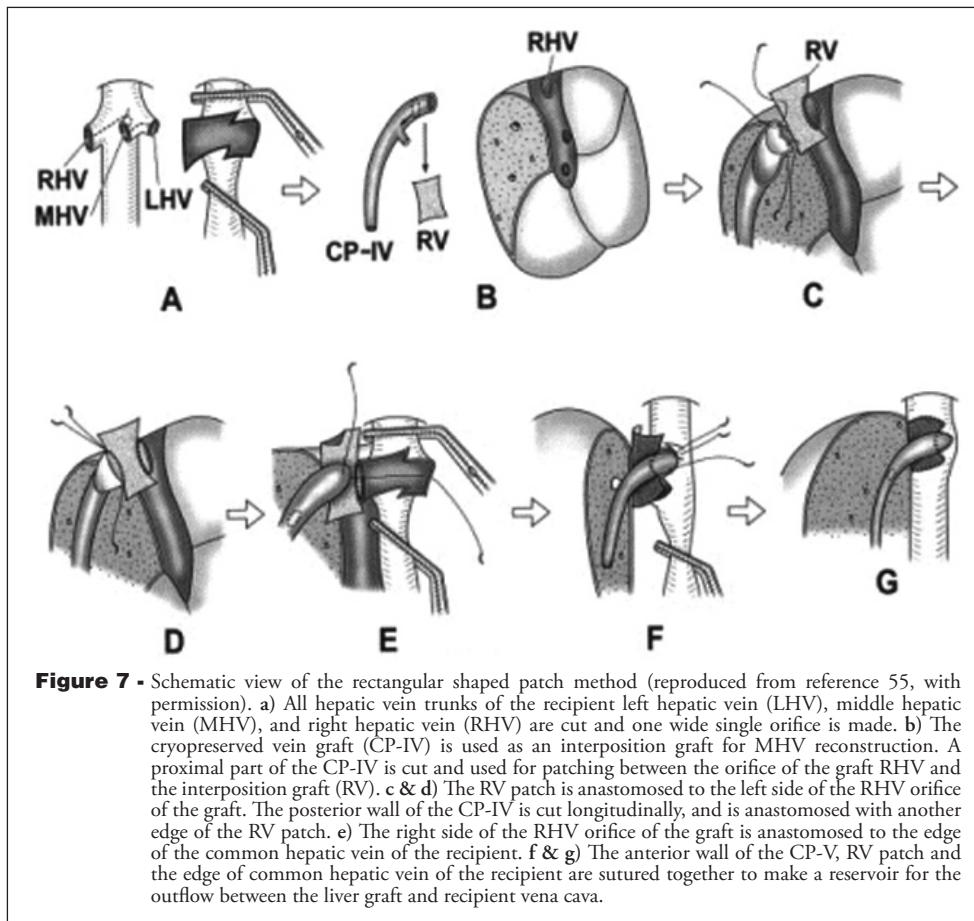
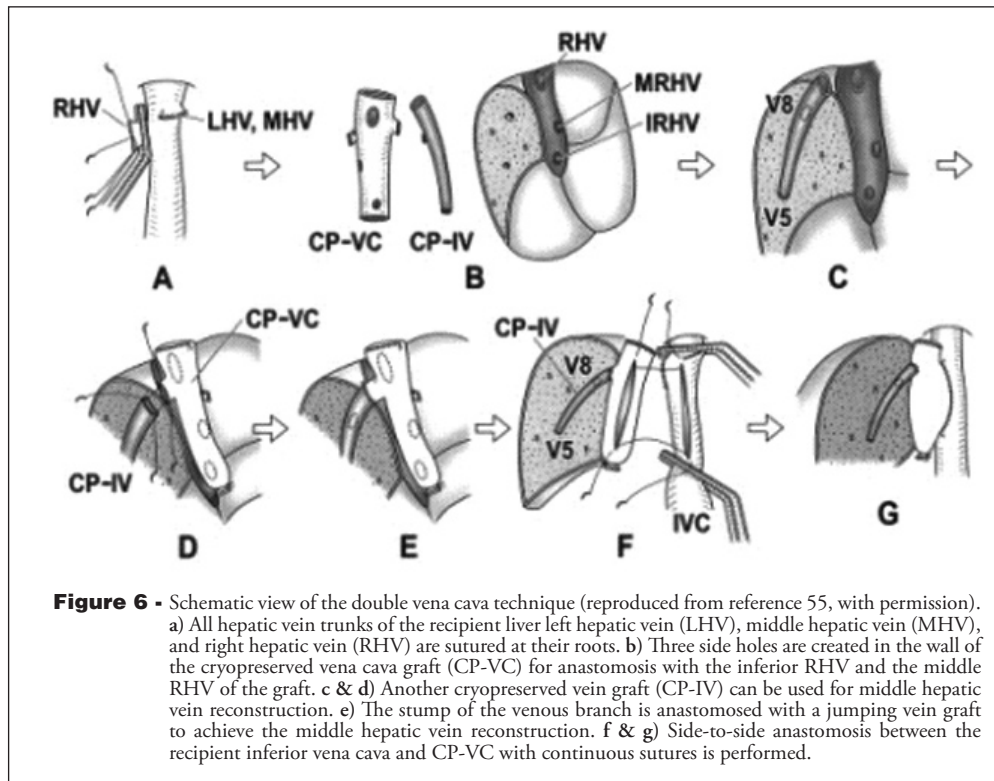
Figure 3 - Anatomic resection for hepatocellular carcinoma (HCC) (reproduced from reference 17, with permission). A) Schema of intrahepatic spread of HCC. (a) An HCC has invaded the nearby portal vein branches, and tumor cells are delivered to the periphery. (b) Tumor cells form microscopic tumor thrombi then metastasize intrahepatically. (c) Tumor thrombi become a source of wider disease dissemination. PV, portal vein. B) Procedures of anatomic resection for HCC.

the tumor-related factors. The Milan criteria (a single tumor less than 5cm in diameter or no more than 3 tumors less than 3cm in diameter each),³ are regarded as the gold standard to determine the indication of transplantation for HCC. When tumor-related factors are within these criteria, the overall survival rate at 4 years was good (85%). The list of indications for transplantation in cases of HCC is, however, likely to expand.²⁴ Further studies are needed to determine suitable criteria for transplantation in cases of HCC. Recurrence of viral hepatitis is another critical problem in liver transplantation, because in most cases HCC develops in a liver with hepatitis virus B- or C-mediated injury. To prevent the recurrence of hepatitis B,

preoperative elimination of the virus with lamivudine and postoperative maintenance of high titer HBsAb with γ -globulin are useful. As for hepatitis C, no effective therapy has yet been established to eliminate the virus before transplantation. Actually, once steatohepatitis has occurred, the prognosis of the recipient is dismal. Preemptive therapy with ribavirin and interferon alpha is now being tried,²⁵ and the preliminary results showed that 30% of the sustained viral response was obtained, even in patients with genotype 1b. However, a larger number of cases and longer follow-up period are needed to evaluate the significance of this strategy.

Deceased liver transplantation. Cadaveric liver transplantation plays a major role in the treatment of





HCC, where cadaveric liver grafting is popularly available. According to the criteria of the Barcelona group,²⁶ the indication for liver resection is limited to a single HCC with normal serum bilirubin level, and portal pressure. For HCC within the Milan criteria,³ the 5-year overall survival rates were reported to be 62-70%,²⁷⁻²⁹ which is satisfactory. However, the high dropout rate from the waiting list remains the critical problem, because of the severe graft shortage.³⁰ The old graft allocation policy in the United States of America (USA), based on the Child Turcotte Pugh score, tended to underestimate the priority of HCC carrying patients, because this score is calculated only by the liver function-related factors, not by the tumor-related ones.³¹ Thus, re-evaluation of the allocation policy was needed. From February 2002, the United Network of Organ Sharing applied the new allocation policy based on the model for end-stage liver disease score. In this new policy, candidates with stage T1 (one lesion <2cm) or stage T2 (one lesion \geq 2cm but <5cm, or as many as 3 lesions less than 3cm each) HCC are given priority beyond the degree of their hepatic decompensation itself.³¹ After applying the new policy, the 5-month dropout rate was reduced from 16.5% to 8.5%.³² The long-term results of liver transplantation for HCC are expected to improve. The strategy of salvage transplantation has been advocated; a respectable HCC is primarily removed by liver resection in patients with good liver function, and after that

secondary liver transplantation is considered if HCC recurs or liver function deteriorates.³³ This strategy seems to be reasonable, in view of the effective usage of the limited graft resources. However, some investigators insist that the morbidity after salvage transplantation is worse than that after primary transplantation.³⁴ However, there is another opinion that the morbidities are similar after salvage and primary transplantation.³⁵ The clinical significance of salvage transplantation remains controversial. The indication of cadaveric liver transplantation and the priority of the waiting list are affected not only by tumor-related factors, but also by social conditions, such as the graft availability.

Living donor liver transplantation (LDLT). Although adult-to-adult LDLT was first performed in 1993,³⁶ its role remained minor in the liver transplantation field in the 1990's. However, the indication of adult-to-adult LDLT has been gradually expanded to include hepatitis C-related cirrhosis with or without HCC,³⁷ because of severe graft shortage and establishment of the right hemiliver graft techniques. The follow-up period is therefore insufficient to evaluate the clinical significance of LDLT for HCC based on long-term results. The median follow-up period in large studies from Japan and the USA was only 16 months in Japan and 450 days in the USA.^{38,39} The 3-year survival rate in the Japanese series was 69%.³⁸ Especially in patients fulfilling Milan criteria,³ the 3-year recurrence rate was very low (only 1.6%). Although further investigation with larger numbers of patients and longer follow-up periods is needed, the present available data suggest that LDLT can provide comparable long-term results with those of cadaveric liver transplantation for HCC, given appropriate candidate selection. As for donor safety, the feasibility of LDLT seems to be acceptable in the present situation. A survey of 1,508 living donors in the 5 Asian high-volume centers showed that the overall complication rate in donors was 15.8%, and the mortality was zero.³⁷ A report from Japan also revealed no mortality and low morbidity (12%).⁴⁰ However, a donor with non-alcoholic steatohepatitis, from whom a right hemiliver graft was harvested in Japan, died of liver failure in 2003. Further follow-up of long-term outcomes of living donors is needed to evaluate the feasibility and maintain donor safety.

New techniques in liver surgery. In the last decade, the mortality after liver resection was remarkably reduced to approximately 1%,¹ which is almost equal to those after other abdominal operations. To further improve the safety of liver resection, various new surgical techniques have been designed.

Hanging maneuver. In this maneuver proposed by Belghiti,⁴¹ a surgical tape is first inserted between the liver and the anterior surface of the inferior vena cava (**Figure**

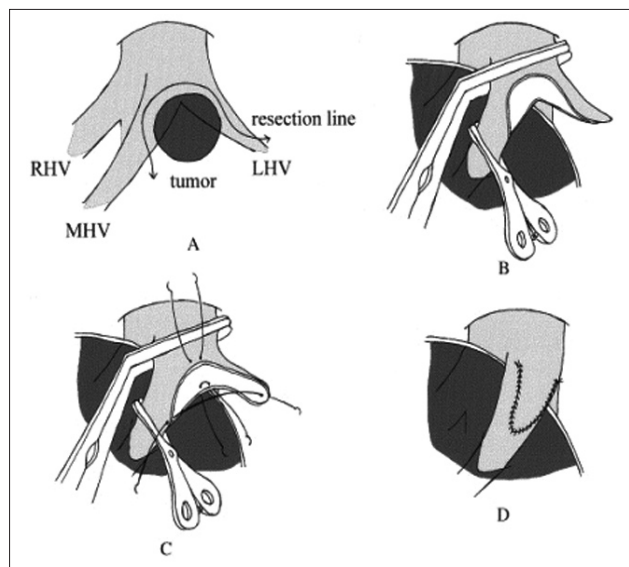


Figure 8 - Rotating left hepatic vein flap technique (reproduced from reference 57, with permission from American College of Surgeons). a) The tumor has invaded the middle and left hepatic veins. The resection line of the hepatic veins is determined after transection of the liver parenchyma and exposure of the venous wall. b) En bloc resection of the tumor and the hepatic venous wall is accomplished. c & d) The venous wall is closed using a continuous suture.

5a). Second, by lifting up the tape, hanging the liver is performed during division of the liver parenchyma (Figure 5b). This maneuver can reduce blood loss through compression effects by the tape, and make it easy to determine the proper direction during the liver division. In right hepatectomy, especially for a huge liver tumor, this maneuver can also avoid mobilization of the right liver. In spite of the possible risk that the short hepatic veins may be injured, this maneuver is useful, and has been applied to liver transection for graft harvesting in LDLT.⁴²

Laparoscopic liver resection. Laparoscopy currently plays a major role in the abdominal surgery fields to achieve minimal invasiveness. Laparoscopic liver resection has been challengingly performed,⁴³⁻⁴⁵ however, its safety is not established. The indication of the laparoscopic approach is limited to a small tumor (<3cm in diameter) located in the peripheral site of the liver,^{43,45} such as the left and right lateral sectors.

New surgical devices. To reduce intraoperative blood loss in liver resection, various surgical devices for liver parenchymal transection have been developed, for example, the ultrasonic dissector, water jet, and dissecting sealer. Fan⁴⁶ reported in a historical control study that introduction of the ultrasonic dissector remarkably reduced blood loss, whereas Takayama⁴⁷ showed in a randomized trial that the quality of the operation using the clamp crushing method was superior to that performed with the ultrasonic dissector, in spite of a similar blood loss volume.⁴⁷ As for the dissecting sealer, both positive and negative opinions have advanced.^{48,49}

Inflow occlusion. Inflow occlusion techniques, such as Pringle's maneuver, hemi-hepatic vascular occlusion, and total vascular exclusion, are indispensable in liver resection to minimize intraoperative blood loss. However, those techniques have disadvantages associated with ischemia-reperfusion injury to the liver. Clavian⁵⁰ reported that 10 minutes of ischemic preconditioning by inflow occlusion could significantly improve the postoperative liver function. Imamura⁵¹ showed that the serum transaminase levels were lowered by the combination of the preconditioning and intermittent inflow occlusion in LDLT. The superiority of the intermittent inflow occlusion over continuous or total occlusion is widely accepted.

Hepatic venous reconstruction. Recently, the clinical significance of the area of congestion has been assiduously investigated, especially in LDLT.⁵² The criteria to judge the presence or absence of congestion have also been established.⁵³ Because the congestion area will atrophy and become non-functioning at some stage following its formation,⁵² adequate reconstruction of the hepatic vein should be performed to guarantee the maximum functional liver volume in LDLT. Various techniques

of reconstruction using vein auto- and allografts have been proposed (Figures 6 & 7).^{54,55} In liver resection for a malignant tumor, hepatic venous reconstruction is also recommended if the functional volume of the residual liver is not enough. In most cases with HCC, which is likely to demonstrate expansive growth, it is easy to detach the HCC from the hepatic vein, even if they are closely attached to each other. However, if the HCC is the mixed or sclerosed type, detachment may be difficult due to tumor invasion. In such cases, reconstruction techniques using an autologous vein graft obtained from the resected liver specimen are useful, as reported for metastatic liver tumors (Figure 8).^{56,57}

In conclusion, in the treatment of HCC, surgical management strategies, including liver resection and transplantation, will play a central role. Surgeons will constantly endeavor to achieve further improvement in the short- and long- term outcomes after surgery for HCC in the future.

References

1. The Liver Cancer Study Group of Japan. The 16th report of primary liver cancer in Japan. Tokyo (JP): The Liver Cancer Study Group of Japan; 2005.
2. Arii S, Yamaoka Y, Futagawa S, Inoue K, Kobayashi K, Kojiro M, et al. Results of surgical and nonsurgical treatment for small-sized hepatocellular carcinomas: a retrospective and nationwide survey in Japan. *Hepatology* 2000; 32: 1224-1229.
3. Mazzaferro V, Regalia E, Doci R, Andreola S, Pulvirenti A, Bozzetti F, et al. Liver transplantation for the treatment of small hepatocellular carcinomas in patients with cirrhosis. *N Engl J Med* 1996; 334: 693-699.
4. Group formed to establish "Guidelines for evidence-based clinical practice for the treatment of liver cancer". Clinical practice guidelines for hepatocellular carcinoma. Tokyo (JP): Kanehara & Co. Ltd.; 2005.
5. Makuuchi M, Kokudo N. Clinical practice guidelines for hepatocellular carcinoma: the first evidence based guidelines from Japan. *World J Gastroenterol* 2006; 12: 828-829.
6. Lam CM, Fan ST, Lo CM, Wong J. Major hepatectomy for hepatocellular carcinoma in patients with an unsatisfactory indocyanine green clearance test. *Br J Surg* 1999; 86: 1012-1017.
7. Wu CC, Cheng SB, Ho WM, Chen JT, Liu TJ, Feng FK. Liver resection for hepatocellular carcinoma in patients with cirrhosis. *Br J Surg* 2005; 92: 348-355.
8. Makuuchi M, Kosuge T, Takayama T, Yamazaki S, Kakazu T, Miyagawa S, et al. Surgery for small liver cancers. *Semin Surg Oncol* 1993; 9: 298-304.
9. Fan ST, Lo CM, Liu CL, Lam CM, Yuen WK, Yeung C. Hepatectomy for hepatocellular carcinoma: toward zero hospital deaths. *Ann Surg* 1999; 229: 322-330.
10. Torzilli G, Makuuchi M, Inoue K, Takayama T, Sakamoto Y, Sugawara Y, et al. No-mortality liver resection for hepatocellular carcinoma in cirrhotic and noncirrhotic patients. Is that a way? A prospective analysis of our approach. *Arch Surg* 1999; 134: 984-992.
11. Imamura H, Matsuyama Y, Miyagawa Y, Ishida K, Shimada R, Miyagawa S, et al. Prognostic significance of anatomical resection and des-gamma-carboxy prothrombin in patients with hepatocellular carcinoma. *Br J Surg* 1999; 86: 1032-1038.

12. Grazi GL, Ercolani G, Pierangeli F, Del Gaudio M, Cescon M, Cavallari A, et al. Improved results of liver resection for hepatocellular carcinoma on cirrhosis give the procedure added value. *Ann Surg* 2001; 234: 71-78.
13. Poon RT, Fan ST, Lo CM, Liu CL, Wong J. Long-term survival and pattern of recurrence after resection of small hepatocellular carcinoma in patients with preserved liver function: implications for a strategy of salvage transplantation. *Ann Surg* 2002; 235: 373-382.
14. Belghiti J, Panis Y, Farges O, Benhamou JP, Fakete F. Intrahepatic recurrence after resection of hepatocellular carcinoma complicating cirrhosis. *Ann Surg* 1991; 214: 114-117.
15. Kakazu T, Makuuchi M, Kawasaki S, Miyagawa S, Hashikura Y, Kosuge T, et al. Repeat hepatic resection for recurrent hepatocellular carcinoma. *Hepato-gastroenterology* 1993; 40: 337-341.
16. Nakajima Y, Ko S, Kanamura T, Nagao M, Kanehiro H, Hisanaga M, et al. Repeat liver resection for hepatocellular carcinoma. *J Am Coll Surg* 2001; 192: 339-344.
17. Makuuchi M, Hasegawa H, Yamazaki S. Ultrasonically guided subsegmentectomy. *Surg Gynecol Obstet* 1986; 161: 346-350.
18. Regimbeau JM, Kianmanesh R, Farges O, Dondero F, Sauvanet A, Belgiti J. Extent of liver resection influences the outcome in patients with cirrhosis and small hepatocellular carcinoma. *Surgery* 2002; 131: 311-317.
19. Hasegawa K, Kokudo N, Imamura H, Matsuyama Y, Aoki T, Minagawa M, et al. Prognostic impact of anatomic resection for hepatocellular carcinoma. *Ann Surg* 2005; 242: 252-259.
20. Minagawa M, Makuuchi M, Takayama T, Ohtomo K. Selection criteria for hepatectomy in patients with hepatocellular carcinoma and portal vein tumor thrombus. *Ann Surg* 2001; 233: 379-384.
21. Poon RTP, Fan ST, Wong J. Selection criteria for hepatic resection in patients with large hepatocellular carcinoma larger than 10cm in diameter. *J Am Coll Surg* 2002; 194: 592-602.
22. Azoulay D, Castaing D, Krissat J, Smail A, Hargreaves GM, Lemoine A, et al. Percutaneous portal vein embolization increases the feasibility and safety of major liver resection for hepatocellular carcinoma in injured liver. *Ann Surg* 2000; 232: 665-672.
23. Aoki T, Imamura H, Hasegawa K, Matsukura A, Sano K, Sugawara Y, et al. Sequential preoperative arterial and portal venous embolizations in patients with hepatocellular carcinoma. *Arch Surg* 2004; 139: 766-774.
24. Yao FY, Ferrell L, Bass NM, Watson JJ, Bacchetti P, Venook A, et al. Liver transplantation for hepatocellular carcinoma: expansion of the tumor size limits does not adversely impact survival. *Hepatology* 2001 33: 1394-1403.
25. Sugawara Y, Makuuchi M, Matsui Y, Kishi Y, Akamatsu N, Kaneko J, et al. Preemptive therapy for hepatitis C virus after living-donor liver transplantation. *Transplantation* 2004; 78: 1308-1311.
26. Llovet JM, Brú C, Bruix J. Prognosis of hepatocellular carcinoma: the BCLC staging classification. *Semin Liver Dis* 1999; 19: 329-338.
27. Santoyo J, Suarez MA, Fernandez-Aguilar JL, Jimenez M, Daga JAP, Sanchez-Perez B, et al. Liver transplant results for hepatocellular carcinoma applying strict preoperative selection criteria. *Transplant Proc* 2005; 37: 1488-1490.
28. Benckert C, Jonas S, Thelen A, Spinelli A, Schumacher G, Heise M, et al. Liver transplantation for hepatocellular carcinoma in cirrhosis: prognostic parameters. *Transplant Proc* 2005; 37: 1693-1694.
29. Lohse F, Angele MK, Gerbes AL, Lohrs U, Jauch KW, Schauer RJ. Tumour size is an important predictor for the outcome after liver transplantation for hepatocellular carcinoma. *Eur J Surg Oncol* 2005; 31: 994-999.
30. Yao FY, Bass NM, Nikolai B, Merriman R, Davern TJ, Kerlan R, et al. A follow-up analysis of the pattern and predictors of dropout from the waiting list for liver transplantation in patients with hepatocellular carcinoma: implication for the current organ allocation policy. *Liver Transpl* 2003; 9: 684-692.
31. Freeman RB Jr, Wiesner RH, Harper A, McDiarmid SV, Lake J, Edwards E, et al. The new liver allocation system: Moving toward evidence-based transplantation policy. *Liver Transpl* 2002; 8: 851-858.
32. Sharma P, Balan V, Hernandez JL, Harper AM, Edwards EB, Rodriguez-Luna H, et al. Liver transplantation for hepatocellular carcinoma: the MELD impact. *Liver Transpl* 2004; 10: 36-41.
33. Manjo PE, Sarasin FP, Mentha G, Hadengue A. Primary liver resection and salvage transplantation or primary liver transplantation in patients with single, small hepatocellular carcinoma and preserved liver function: an outcome-oriented decision analysis. *Hepatology* 2000; 31: 899-906.
34. Adam R, Azoulay D, Castaing D, Eshkenazy R, Pascal G, Hashizume K, et al. Liver resection as a bridge to transplantation for hepatocellular carcinoma on cirrhosis: a reasonable strategy? *Ann Surg* 2003; 238: 508-518.
35. Belghiti J, Cortes A, Abdalla EK, Regimbeau JM, Prakash K, Durand F, et al. Resection prior to liver transplantation for hepatocellular carcinoma. *Ann Surg* 2003; 238: 885-892.
36. Hashikura Y, Makuuchi M, Kawasaki S, Matsunami H, Ikegami T, Nakazawa Y, et al. Successful living-related partial liver transplantation to an adult patient. *Lancet* 1994; 343: 1233-1234.
37. Lo CM. Complications and long-term outcome of living liver donors: a survey of 1,508 cases in five Asian centers. *Transplantation* 2003; 75: S12-S15.
38. Todo S, Furukawa H. Living donor liver transplantation for adult patients with hepatocellular carcinoma: experience in Japan. *Ann Surg* 2004; 240: 451-461.
39. Gondolesi GE, Roayaie S, Muñoz L, Kim-Schluger L, Schiano T, Fishbein TM, et al. Adult living donor liver transplantation for patients with hepatocellular carcinoma: extending UNOS priority criteria. *Ann Surg* 2004; 239: 142-149.
40. Umeshita K, Fujiwara K, Kiyosawa K, Makuuchi M, Satomi S, Sugimachi K, et al. Operative morbidity of living donors in Japan. *Lancet* 2003; 362: 687-690.
41. Belghiti J, Guevara OA, Noun R, Saldinger PF, Kianmanesh R. Liver hanging maneuver: a safe approach to right hepatectomy without liver mobilization. *J Am Coll Surg* 2001; 193: 109-111.
42. Kokudo N, Imamura H, Sano K, Zhang K, Hasegawa K, Sugawara Y, et al. Ultrasonically assisted retrohepatic dissection for a liver hanging maneuver. *Ann Surg* 2005; 242: 651-654.
43. Gigot JF, Glineur D, Azagra JS, Goergen M, Ceuterick M, Morino M, et al. Laparoscopic liver resection for malignant liver tumors: preliminary results of a multicenter European study. *Ann Surg* 2002; 236: 90-97.
44. Morino M, Morra I, Rosso E, Miglietta C, Garrone C. Laparoscopic vs open hepatic resection. *Surg Endosc* 2003; 17: 1914-1918.
45. Teramoto K, Kawamura T, Takamatsu S, Noguchi N, Nakamura N, Arii S. Laparoscopic and thoracoscopic partial hepatectomy for hepatocellular carcinoma. *World J Surg* 2003; 27: 1131-1136.
46. Fan ST, Lai ECS, Lo CM, Chu KM, Liu CL, Wong J. Hepatectomy with an ultrasonic dissector for hepatocellular carcinoma. *Br J Surg* 1996; 83: 117-120.
47. Takayama T, Makuuchi M, Kubota K, Harihara Y, Hui AM, Sano K, et al. Randomized comparison of ultrasonic vs clamp transaction of the liver. *Arch Surg* 2001; 136: 922-928.

48. Sakamoto Y, Yamamoto J, Kokudo N, Seki M, Kosuge T, Yamaguchi T, et al. Bloodless liver resection using the monopolar Floating Ball plus LigaSure diathermy: preliminary results of 16 liver resections. *World J Surg* 2005; 28: 166-172.
49. Arita J, Hasegawa K, Kokudo N, Sano K, Sugawara Y, Makuuchi M. Randomized clinical trial assessing effect of saline-linked radiofrequency coagulator on blood loss during hepatic resection. *Br J Surg* 2005; 92: 954-959.
50. Clavian PA, Yadav S, Sindram D, Bentley RC. Protective effects of ischemic preconditioning for liver resection performed under inflow occlusion in humans. *Ann Surg* 2000; 232: 155-162.
51. Imamura H, Takayama T, Sugawara Y, Kokudo N, Aoki T, Kaneko J, et al. Pringle's manoeuvre in living donors. *Lancet* 2002; 360: 2049-2050.
52. Maema A, Imamura H, Takayama T, Sano K, Hui AM, Sugawara Y, et al. Impaired volume regeneration of split livers with partial venous disruption: A latent problem in partial liver transplantation. *Transplantation* 2002; 73: 765-769.
53. Sano K, Makuuchi M, Miki K, Maema A, Sugawara Y, Imamura H, et al. Evaluation of hepatic venous congestion: Proposed indication criteria for hepatic vein reconstruction. *Ann Surg* 2002; 236: 241-247.
54. Sugawara Y, Makuuchi M, Sano K, Imamura H, Kaneko J, Ohkubo T, et al. Vein reconstruction in modified right liver graft for living donor liver transplantation. *Ann Surg* 2003; 237: 180-185.
55. Sugawara Y, Makuuchi M, Akamatsu N, Kishi Y, Niiya T, Kaneko J, et al. Refinement of venous reconstruction using cryopreserved veins in right liver grafts. *Liver Transpl* 2004; 10: 541-547.
56. Aoki T, Sugawara Y, Imamura H, Seyama Y, Minagawa M, Hasegawa K, et al. Hepatic resection with reconstruction of the inferior vena cava or hepatic venous confluence for metastatic liver tumor from colorectal cancer. *J Am Coll Surg* 2004; 198: 366-372.
57. Hashimoto T, Kokudo N, Aoki T, Natori T, Arita J, Sano K, et al. Reconstruction of middle hepatic vein using a rotating left hepatic vein flap. *J Am Coll Surg* 2004; 199: 656-660.

Supplements

- * Supplements will be considered for work including proceedings of conferences or subject matter covering an important topic
- * Material can be in the form of original work or abstracts.
- * Material in supplements will be for the purpose of teaching rather than research.
- * The Guest Editor will ensure that the financial cost of production of the supplement is covered.
- * Supplements will be distributed with the regular issue of the journal but further copies can be ordered upon request.
- * Material will be made available on Saudi Medical Journal website