

Pleuropulmonary blastoma

A rare childhood malignancy

Yasser M. Aljehani, MD, Ayman M. Elbaz, MSc, Khaled M. Moghazy, MD, Amer A. Alardi, MD, Adel A. Montaser, MD, Yasser F. El-Ghoneimy, MD.

ABSTRACT

Pleuropulmonary blastoma (PPB) is an extremely rare, intrathoracic neoplasm of early childhood with unfavorable outcome. We present a case of a 4-year-old boy with progressive dyspnea due to tension pneumothorax. After chest tube insertion, the CT scan showed large multilocular cystic lesions containing air and solid areas involving the right lower lobe, and its related pleura. Thoracotomy was carried out, and the cyst was removed with the pleural solid areas. Histopathological examination confirmed the diagnosis of PPB type II. Postoperatively, the patient was scheduled to start chemotherapy in a specialized pediatric oncology center to complete the treatment.

Saudi Med J 2007; Vol. 28 (9): 1443-1445

From the Departments of Surgery, Thoracic Unit (Aljehani, Elbaz, El-Ghoneimy), Radiology (Moghazy), Pediatrics (Alardi), and Pathology (Montaser,) King Faisal University, Al-Khobar, Kingdom of Saudi Arabia.

Received 30th April 2006. Accepted 20th December 2006.

Address correspondence and reprint request to: Dr. Yasser El-Ghoneimy, King Faisal University, King Fahad Hospital of the University, PO Box 40087, Al-Khobar 31952, Kingdom of Saudi Arabia. Tel. +966 (3) 8966745. Fax. +966 (3) 8966728. E-mail: yasser_farag@hotmail.com

Pleuropulmonary blastoma (PPB) is a rare, and aggressive primary malignant tumor of the lung. It is represented by an epithelial component consisting of tubular or gland-like elements, and a mesenchymal embryonic component resembling the fetal lung at the 12th gestational age.¹⁻² This tumor is the pulmonary equivalent to other pediatric tumors such as Wilm's tumor, neuroblastoma, hepatoblastoma, and retinoblastoma.³ Based on a previous report, the term blastoma was proposed due to its resemblance to Wilm's tumor, and the first case in the literature was reported by

Barrett and Barnard⁴ in 1945. In 1988, Manivel et al⁵ described PPB in children as an entity that was distinct from the biphasic epithelial-stromal morphology of the classic adult type. The tumor is usually located in the lung periphery, but it may be extra pulmonary with involvement of the mediastinum, diaphragm, or pleura, or both.⁶ In light of the preceding information, which reflects the rarity of this malignant entity, we report this case with the objective of adding to the limited existing literature. A better understanding of the natural history, and effective management is gained by the increased reporting of such entity.

Case Report. A 4-year old boy presented to us with respiratory distress, and low-grade fever of 3 days duration. Plain chest x-ray showed a picture of tension pneumothorax on the right side, with an air-fluid level. A chest tube was inserted to relieve the dyspnea and to achieve full lung expansion (**Figure 1**). After tube insertion, the lung was partially inflated with persistence of the cystic areas involving the middle and lower pulmonary zones. A CT scan of the chest showed a large cystic lesion involving both middle and lower zones with multiple solid areas (**Figure 2**). Right thoracotomy was carried out in the 5th intercostal space. There was a large cystic lesion measuring 15 x 10 x 5 cm, arising from the right upper lobe, with no evidence of solid areas arising from the lung. The solid part of the lesion was mainly pleural. There was no hilar, or mediastinal lymph node enlargement. The cystic part was completely excised to free the 3 lobes, with wedge resection from the upper lobe. The solid part was completely removed from the chest wall by extrapleural dissection. The resected tumor was cystic, with associated solid parts of fleshy, gray white masses. Histologically, the solid portion consisted of nests of primitive round to oval blastomatous cells, separated by delicate fibrous tissue septa with areas of rhabdomyosarcomatous differentiation. Multiple cystic spaces were seen. The resection margins were free. These

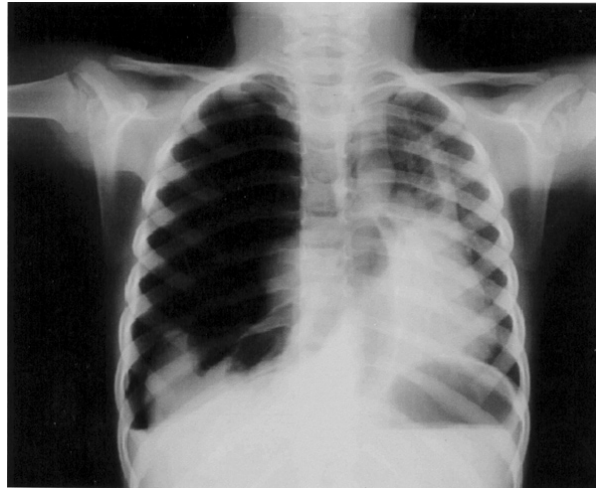


Figure 1 - Plain chest X-ray showing right side tension pneumothorax, with shift of the mediastinum to the left side. Small right side plural effusion is noted.

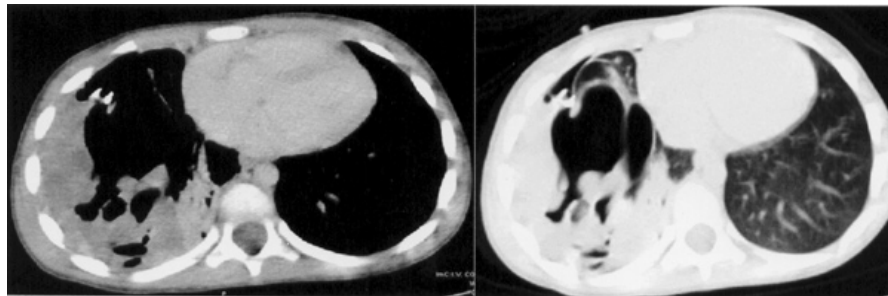


Figure 2 - Enhanced CT scan of the chest, mediastinal, and corresponding lung window. A large multilocular cystic lesions containing air and solid areas involving the right lower lobe, and its related pleura. Pleural effusion and chest tube are seen.

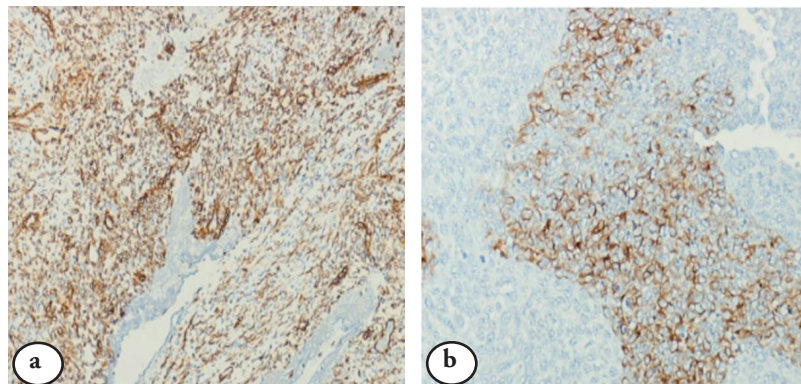


Figure 3 - Histopathological results showing a) sheets of small blastemal malignant cells with hypocellular areas of elongated mesenchymal cells strongly positive for vimentin staining, and b) cystic spaces lined by respiratory epithelium are also seen as foci positive for desmin staining indicating rhabdomyosarcomas origin.

findings correspond to PPB-type II (Figures 3a & 3b). Postoperative course was smooth with no complications, and he is doing well after 3 months, and is now undergoing chemotherapy.

Discussion. The PPB is a rare, intrathoracic tumor of childhood. It accounts for 0.5% of all primary malignant lung neoplasms.⁷ There are 100 cases recorded by the PPB registry, and occurs in children up to 12 years of age, usually by the age of 4 years, with a median age of 2 years.^{6,7} There is no specific clinical feature. The child, like most reported cases, presented with a pulmonary infection and respiratory difficulty. The most common presenting symptoms are cough, dyspnea or respiratory distress, fatigue and fever, and rarely pneumothorax. In our case, the child presented with a tension pneumothorax, which is an unusual presentation. Radiologically, the tumor has no characteristic findings on imaging studies, but should be considered in the differential diagnosis of other benign cystic lung lesions.⁸ The PPB is considered a dysontogenetic tumor, analogous to Wilm's tumor in the kidney, neuroblastoma in the adrenal gland, and hepatoblastoma in the liver. Pathologically, Denher et al⁹ classified PPB into 3 subtypes: (I) purely cystic, the multilocular cysts have thin walls; (II) cystic and solid; and (III) purely solid, the solid areas are gelatinous and white, and sometimes hemorrhagic. They may be massive, occupying an entire lobe or lung. There is an increased tendency for malignant transformation from type I to type III.⁹ Histologically, it is characterized by a primitive, mixed blastomatous, and sarcomatous appearance. There are several reports of gains in chromosome 8, specifically within the mesenchymal elements, and P53 mutations are common.¹⁰ The vimentin stain is positive in mesenchymal component, and desmin stain in rhabdomyosarcomatous component, less often in the small cell cambium layer.¹⁰ The right hemithorax is involved in 80% of the reported cases,^{3,4,6,7,8} although bilateral forms have been recently described.¹¹ As complete tumor ablation is essential to prevent local recurrence and allow any chance of survival, the main goal of therapy should be radical surgery, followed by chemotherapy.¹² Because the response to chemotherapy is poor, some suggest that chemotherapy should be given with local radiotherapy in the majority of patients.^{6,12,13} **Prognosis.** The prognosis for these patients is grave, for type I: 80-90%, 5 year disease-free survival,¹⁴ types II and III: less than 50%, 5 year survival.^{4,11} Types II and III PPBs are clearly aggressive malignancies with projected overall survival of 62% at 2 years, and 42% at 5 years, even after multimodality therapy. Pleural and

mediastinal involvement are associated with a worse prognosis.¹⁴ The tumor recurs locally,⁴ and metastasizes to the central nervous system,¹⁴ and bone, pancreatic, and ocular⁴ metastases occur. Patients with extrapulmonary involvement at the time of diagnosis have worse prognosis than those without such involvement.^{6,9} Children may develop a second pleuropulmonary blastoma.⁶

In conclusion, pulmonary blastoma is rare. Because of the rarity, limited information on the clinical features, the natural course, and the treatment efficacy of these neoplasms are available. However, multimodality therapy including complete surgical removal of the tumor is considered the treatment of choice. Chemotherapy has been used as an adjuvant therapy,^{12,13} and the role of radiotherapy is still unclear.^{13,14}

References

1. Fung CH, Lo JW, Yonan TN. Pulmonary blastoma. An ultra structural study with a brief review of literature and discussion of pathogenesis. *Cancer* 1977; 39: 153-163.
2. Senac MO, Wood BP, Isaacs H, Weller M. Pulmonary blastoma: a rare childhood malignancy. *Radiology* 1991; 179: 743-746.
3. Romeo C, Impellizzeri P, Grosso M, Vitarelli E, Gentile C. Pleuropulmonary blastoma: long-term survival and literature review. *Med Pediatr Oncol* 1999; 33: 372-376.
4. Barnard WG. Embryoma of lung. *Thorax* 1952; 7: 299-301.
5. Manivel JC, Priest JR, Watterson J, Steiner M, Woods WG, Wick MR. Pleuropulmonary blastoma: to so called pulmonary blastoma of childhood. *Cancer* 1988; 62: 1516-1526.
6. Indolfi P, Casale F, Carli M, Bisogno G, Ninfo V, Cecchetto G, et al. Pleuropulmonary blastoma: management and prognosis of 11 cases. *Cancer* 2000; 89: 1396-1401.
7. Calabria R, Srikanth MS, Chamberlin K, Bloch J, Atkinson JB. Management of pulmonary blastoma in children. *Am Surg* 1993; 59: 192-196.
8. Priest JR, McDermott MB, Bhatia S, Watterson J, Manivel JC, Dehner LP. Pleuropulmonary blastoma. A clinicopathological study of 50 cases. *Cancer* 1997; 80: 147-161.
9. Dehner LP, Watterson J, Priest J. Pleuropulmonary blastoma. A unique intrathoracic pulmonary neoplasm of childhood. *Perspect Pediatr Pathol* 1995; 18: 214-226.
10. Perdikogianni C, Stiakaki E, Danilaitou V. Pleuropulmonary blastoma: an aggressive intrathoracic neoplasm of childhood. *Pediatr Hematol Oncol* 2001; 18: 259-266.
11. Sebire NJ, Rampling D, Malone M, Ramsay A, Sheppard M. Gains of chromosome 8 in pleuropulmonary blastomas of childhood. *Pediatr Dev Pathol* 2002; 5: 221-222.
12. Lallier M, Boutchard S, Di Lorenzo M. Pleuropulmonary blastoma: a rare pathology with an even rarer presentation. *J Pediatr Surg* 1999; 34: 1057-1059.
13. Dosios T, Stinios P, Nicolaidis AS, Spyarakos E, Androulakakis E, Constantopoulos A. Pleuropulmonary blastoma in childhood. A malignant degeneration of pulmonary cysts. *Pediatr Surg Int* 2004; 20: 863-865.
14. Piastra M, Ruggiero A, Caresta E, Granone P, Chiaretti A, Polidori G, et al. Critical presentation of pleuropulmonary blastoma. *Pediatr Surg Int* 2005; 21: 223-226.