

Mucinous cystadenoma of the ovary in a 12-year-old girl

Abdulaziz S. Alobaid, FRCS(C).

ABSTRACT

الأورام الميوسينية الحميدة هي أورام نادرة لدى الأطفال . حسب علمنا تم وصف ١٩ حالة فقط في النشرات الطبية من قبل . عادة تتبين الحالة بوجود ورم في البطن، نقدم حالة فتاة عمرها ١٢ سنة كان لديها ورم ضخم في المبيض الأيسر مسبباً تضخم في الكلى مع قصور في وظائف الكلى . تقرير الباثولوجي النهائي أكد وجود ورم ميوسيني حميد ، المرضى المصابين بالأورام الميوسينية، تظهر لديهم الأعراض متأخرة ، وقد يؤدي هذا إلى قصور في وظائف الكلى بسبب انسداد مخرج البول. إزالة المبيض مع الأنبوب عادة ما يكون علاج كافي لهذه الحالات. تشخيص ورم ميوسيني حميد يجب أن يؤخذ في الاعتبار لدى الأطفال الذين يشتكون من أورام ضخمة في البطن التشخيص والتدخل العلاجي المبكر ضروري في هذه الحالات لتجنب حدوث المضاعفات .

Benign mucinous cystadenomas (MCA) are rare benign neoplasms in the pediatric age group. Only 19 cases have been described before, and they often present as large abdominal masses. We present a 12-year-old patient that had a huge mass arising from the left ovary causing bilateral hydronephrosis and renal insufficiency. The final pathology revealed a benign MCA. Patients with mucinous tumors usually present late, this may lead to renal insufficiency secondary to urinary outflow obstruction. Unilateral salpingo-oophorectomy is usually sufficient treatment for these cases. The diagnosis of MCA should be considered in children who present with huge pelvi-abdominal masses. Early recognition and intervention are necessary to avoid potential complications.

Saudi Med J 2008; Vol. 29 (1): 126-128

From the Department of Obstetrics and Gynecology, College of Medicine, King Saud University, Riyadh, Kingdom of Saudi Arabia.

Received 29th April 2007. Accepted 23rd June 2007.

Address correspondence and reprint request to: Dr. Abdulaziz S. Alobaid, Department of Obstetrics and Gynecology, College of Medicine, King Saud University, PO Box 7805, Riyadh 11472, Kingdom of Saudi Arabia. Tel. +966 (1) 4670818. Fax. +966 (1) 4679557. E-mail: draalobaid@hotmail.com

Benign and malignant ovarian tumors are rare in children younger than 15 years of age, the incidence has been estimated to be 2.6 cases in 100,000 girls.¹ Of all childhood malignancies, ovarian tumors account for only 1-1.5%,^{2,3} only 10-17% of these are epithelial tumors. Mucinous cystadenomas (MCA) are benign ovarian epithelial neoplasms that occur most often in the third to sixth decade of life.² Patients with these tumors do not have specific symptoms. This may lead to late presentation. Since these tumors are rare in the second decade of life, their diagnosis can be missed. The tumors can become very large, which may lead to ureteric compression and secondary renal insufficiency. Unilateral salpingo-oophorectomy is usually sufficient treatment for these cases. On literature review, we found only 19 cases described with MCA in the pediatric age group.⁴⁻⁸ We present a 12-year-old girl with a large ovarian cystadenoma and renal insufficiency. Her kidney function returned to normal after the surgery.

Case Report. A 12-year-old girl presented to the emergency room with a few months history of abdominal distention and discomfort. The symptoms gradually worsened with time, and on hospital admission she had severe discomfort and weakness. On physical examination a giant mass was palpated filling the abdominal cavity from the xiphoid process to the pubic bone. Abdominal ultrasonography (**Figure 1**) revealed a mixed cystic and solid mass that was 30 cm in greatest diameter, with bilateral hydronephrosis and hydroureter. A CT scan revealed similar findings. Tumor markers were all normal, Calcium 125 = 25 IU/L (normal 0-35 IU/L), human chorio-gonadotrophin <0.1 IU/L (normal <5 IU/L), alpha fetoprotein = 1.87 KIU/L (normal <5.8 KIU/L), carcinoembryonic antigen = 0.34 ug/L (normal 0-2.5 ug/L) and Lactate dehydrogenase = 172 IU/L (normal 115-225 IU/L), however, the creatinine was elevated at 125 umol/L (normal 44-97 umol/L). The surgery was performed through a midline incision, exploration of the upper abdomen was normal, pelvic exploration revealed a normal right ovary and uterus, the left ovary, however, was totally replaced by a giant mass that was filling the entire pelvic and abdominal

cavity (**Figure 2**), the mass was cystic with a smooth irregular surface, a left salpingo-oophorectomy was performed as the left fallopian tube could not be saved. At frozen section, the mass was diagnosed to be a benign MCA. The weight of the mass was approximately 8 kg, and the final pathology confirmed the diagnosis of a benign MCA (**Figure 3**). The postoperative recovery was uneventful, and the patient was discharged home on the 6th post-operative day with normal creatinine (60 $\mu\text{mol/L}$). Nine months after the surgery the patient is still doing very well with normal menses and kidney function. A follow-up ultrasound was also normal.

Discussion. Differential diagnosis of ovarian masses in adolescents includes functional cysts, benign or malignant ovarian neoplasm, torsion with consecutive edema, and involvement of the ovary in lymphoma, leukemia, or metastatic disease.^{2,5} Benign MCA are rare neoplasms in the pediatric age group with only 19 cases reported in the literature.⁸ The diagnosis can be delayed because of the slow growth of these tumors, non-specific symptoms, and rarity of these tumors leading to delayed treatment.³ Our patient had non-specific symptoms for a few months before her presentation. This led to late presentation where the mass was filling the whole pelvi-abdominal cavity. This is compatible with previous reports.⁸ The tumor arose from the left ovary, which is in concordance with previous reports that describe a predilection of these tumors to the left ovary.⁸ The most common symptom is increased abdominal distention and discomfort, as it was in our case. Unilateral hydronephrosis has also been described previously.⁸ Our patient had renal insufficiency with a high creatinine level. This was never described in previous reports. The ultrasound scan described bilateral hydronephrosis and bilateral hydroureter. We believe that this patient had renal insufficiency because of the urinary outflow obstruction, as her mass was huge and compressed both ureters. Once the obstruction was relieved with the surgical removal of the mass, her kidney function returned to normal. The treatment of these patients is surgical. Unilateral salpingo-oophorectomy is usually sufficient treatment.^{5,8} If the contralateral ovary looks normal at exploration, biopsy is not necessary as it may lead to adhesion formation and may jeopardize future fertility.⁹ No cases of tumor recurrence in the contralateral ovary have been described. Our patient had a unilateral salpingo-oophorectomy, the contralateral ovary was inspected to be normal, and therefore, biopsy was not felt to be necessary. She is still doing very well during her follow-up. Her kidney function is normal. Follow-up of these patients is clinical, and by serial ultrasound examination. Our patient was followed up every 4 months with ultrasounds, as suggested in previous reports.⁸ Because of the rarity of these tumors,

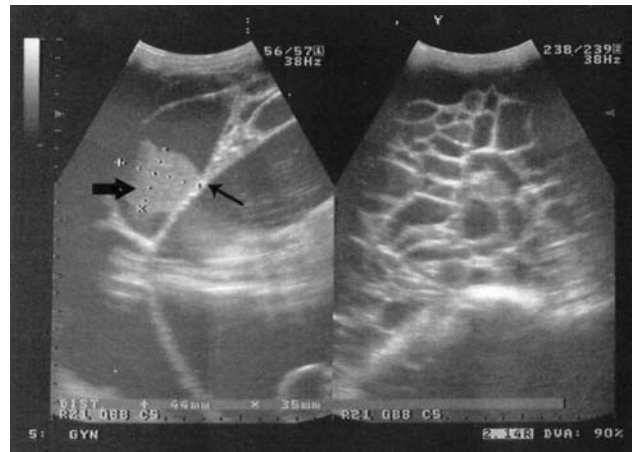


Figure 1 -Ultrasounds scan showing a large cystic multilocular mass containing multiple thick septations (small arrow) and a solid component (big arrow).

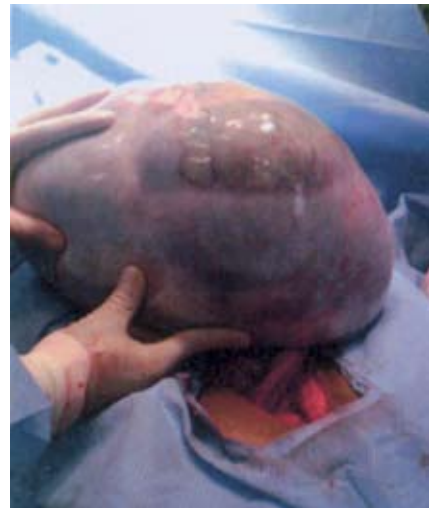

Figure 2 - The mass taken out from the abdomino-pelvic cavity.

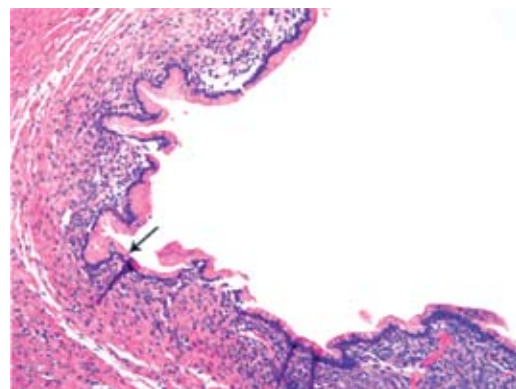


Figure 3 -Ovarian mucinous cystadenoma. The epithelium contains prominent vacuoles containing mucin (arrow) (haematoxylin and eosin, original magnification x 200).

strict guidelines about the frequency of ultrasound examination cannot be recommended based on this or previous case reports.

In summary, our patient had a similar presentation to patients described in previous reports. However, her late presentation lead to renal insufficiency. In conclusion, MCA are rare tumors in children, they often present as large pelvic-abdominal masses with non-specific symptoms. Large tumors may lead to impaired kidney function. Conservative surgery (unilateral ovarian cystectomy or salpingo-oophorectomy) is adequate for these benign ovarian neoplasms, with a resumption of normal kidney function. Physicians should consider the diagnosis of MCA if a young patient presents with a pelvi-abdominal mass. Early recognition and intervention is necessary to avoid potential complications.

References

1. Lindfors O. Primary ovarian neoplasms in infants and children: a study of 81 cases diagnosed in Finland and Sweden. *Ann Chir Gynaecol Fenn Suppl* 1971; 177: 1-66.
2. Brown MF, Hebra A, McGeehin K, Ross AJ 3rd. Ovarian masses in children: a review of 91 cases of malignant and benign masses. *J Pediatr Surg* 1993; 28: 930-933.
3. Freud E, Golinsky D, Steinberg RM, Blumenfeld A, Yaniv I, Zer M. Ovarian masses in children. *Clin Pediatr (Phila)* 1999; 38: 573-577.
4. Lefebvre B, Philippart P, Brandelet B, Mendes da Costa P. Giant cystadenoma of the ovary in an adolescent: clinical case and review of the literature. *Rev Med Brux* 2000; 21: 157-159.
5. Flotho C, Rückauer K, Duffner U, Bergstätter E, Böhm N, Niemeier CM. Mucinous cystadenoma of the ovary in a 15-year-old girl. *J Pediatr Surg* 2001; 36: 1-3.
6. Yazici M, Etensel B, Gursoy H, Erkus M. Mucinous cystadenoma: a rare abdominal mass in childhood. *Eur J Pediatr Surg* 2002; 12: 330-332.
7. Connolly G, Walsh M, McKenna P, Devaney D. Massive ovarian cystadenoma in a 14-year-old girl. *J Obstet Gynaecol* 2004; 24: 93-94.
8. Sri Paran T, Mortell A, Devaney D, Pinter A, Puri P. Mucinous cystadenoma of the ovary in perimenarchal girls. *Pediatr Surg Int* 2006; 22: 224-227.
9. Lazar EL. Evaluation and management of pediatric solid ovarian tumors. *Semin Pediatr Surg* 1998; 7: 29-34.

Related topics

Zangana AM. Twisted mixed germ cell tumor of the ovary in a child. *Saudi Med J* 2006; 27: 1240-1243.

Khan FY. Unusual cause of dysphagia. *Saudi Med J* 2005; 26: 1303-1304.

Al-Ghamdi FA, Al-Khattabi MA. Ovarian mucinous cystadenocarcinoma of low malignant potential associated with a mature cystic teratoma. *Saudi Med J* 2006; 27: 1412-1414.

Sait KH, Alkhattabi MA, Alkushi AO, Alqahtani MH. Ovarian mucinous cystadenoma in a female with Turner syndrome. *Saudi Med J* 2004; 25: 1270-1273.