

Hemoptysis

A rare presentation of a vallecular cyst

Saad A. Alsaleh, MBBS, Ahmed Y. Al-Ammar, MD, FKSU.

ABSTRACT

يعتبر بصق الدم تجربة مخيفة لكل من المريض والطبيب وتتطلب المباشرة في تقييم وتشخيص الحالة بدون أي تأخير. نستعرض في هذا التقرير حالة كيس في لسان المزمارية لرجل يبلغ من العمر ثلاثون عاماً، ظهر ببصق دم، وهي الحالة الثانية فقط في الأدبيات الطبية من هذا النوع. تم استئصال الكيس بواسطة ليزر أوكسجين، بعد إزالة الضغط عن الكيس بإبرة. لم يكن هناك أي مضاعفات أو انتكاسات للحالة بعد شهرين من المتابعة. في مثل هذا الحالات النادرة، ما يحصل دائماً هو تباين في آراء الكتاب، من حيث تصنيف وتقييم الحالة، ناهيك عن عدم الاتفاق في التوصل إلى السبيل الأمثل لعلاجها. وعليه، فقد حاولنا في هذا التقرير بأن نقوم باستعراض مثل هذه الآراء ومناقشتها.

Hemoptysis is a frightening experience for both patient and clinician and warrants prompt evaluation and diagnosis. We report a case of a vallecular cyst (VC) in a 30-year-old gentleman presenting with hemoptysis. Carbon dioxide laser dissection of the VC after needle decompression was carried out with no complications or recurrence in a 2 months follow-up. In such rare lesions, the authors tend to have conflicting opinions in their classification, evaluation, and management. In this report, these opinions are reviewed and discussed.

Saudi Med J 2008; Vol. 29 (10): 1497-1500

From the Department of Otolaryngology, King Abdulaziz University Hospital, King Saud University, Riyadh, Kingdom of Saudi Arabia.

Received 22nd February 2008. Accepted 10th August 2008.

Address correspondence and reprint request to: Dr. Saad A. Alsaleh, Department of Otolaryngology, King Abdulaziz University Hospital, PO Box 245, Riyadh 11411, Kingdom of Saudi Arabia. Tel. +966 504443759. Fax. +966 (1) 4775748. E-mail: dr.saad.alsaleh@gmail.com

Laryngeal cysts are rare lesions, representing approximately 5% of all benign laryngeal lesions.¹ It is estimated that 10.5% of laryngeal cysts occur in the vallecular space.² Vallecular cysts (VC) have been reported in the literature under other names, such as mucus retention cyst, pre-epiglottic cyst, epiglottic cyst, base-of-the-tongue cyst, and ductal cyst.^{3,4} This is probably due to the confusion surrounding the pathogenesis and etiology of such lesions. Adult patients with a VC generally have a benign course and commonly present with symptoms of hoarseness, foreign body sensation and dysphagia.^{2,5} Cold excision technique or repeated aspiration of the VC are the conventional modes of treatment.^{2,4} However, these are associated with high rates of recurrence. Newer methods, such as CO₂ laser excision and laser marsupialization were suggested.^{6,7} However, data is scarce to justify the safety and efficacy of the latter methods. We report our successful experience in CO₂ laser excision of a VC in a patient who had an atypical presentation hemoptysis.

Case Report. A 30-year-old gentleman presented to our service with a 10-day history of hemoptysis. It was described as streaks of blood on a background of whitish mucous. It stopped spontaneously in 4 days with no history of dyspnea, fever, night sweats or weight loss. He also reported that he had hoarseness, foreign body sensation in the throat and difficulty breathing when sleeping in the supine position for 2 years. There was history of voice abuse as a school teacher and 15 pack-year smoking history was also reported. He denied having dysphagia, heartburn or choking. His past medical and surgical history were irrelevant except for bronchial asthma which was controlled by salbutamol inhalers. Seventy degree rigid endoscopic examination revealed a vallecular mass measuring 2x2 cm and a small nodular mass at the junction of the anterior third and posterior two thirds of the right vocal fold. There was no evidence of other swellings or lymphadenopathy in the head and neck. Vital signs and systemic examination were normal.

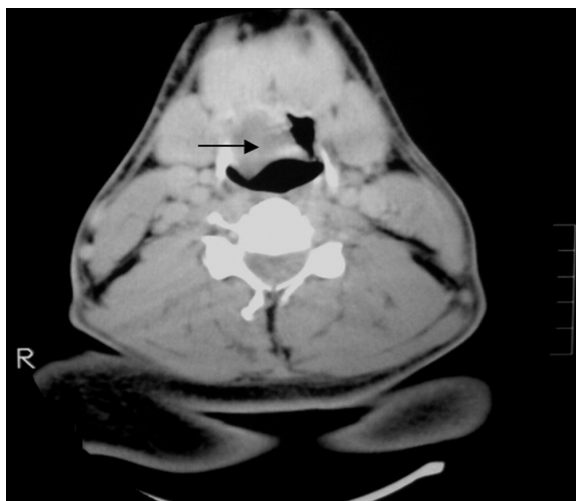


Figure 1 - Computerized tomography scan of the neck demonstrating a vallecular homogenous cystic mass narrowing the airway.

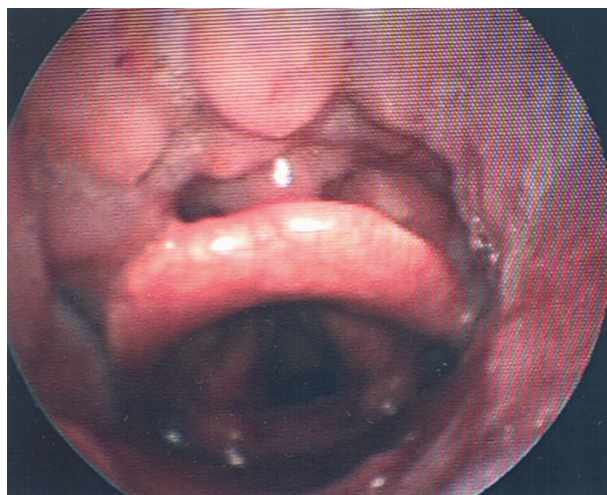


Figure 3 - Picture taken during follow-up demonstrating no recurrence and complete healing.

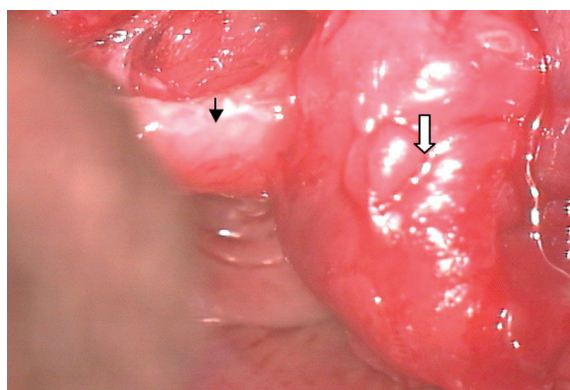


Figure 2 - A picture taken during micro-laryngoscopy representing laser dissection of the vallecular cysts (white arrow) and the epiglottis (black arrow).

Computerized tomography scan and ultrasound of the neck demonstrated a 1.7 x 2 cm cystic mass at the right vallecular space crossing the midline with insignificant cervical lymphadenopathy and a normal thyroid gland (**Figure 1**). Under general anesthesia, laryngoscopy confirmed the findings mentioned above and it also showed that the cyst was attached firmly to base of the tongue and lingual surface of the epiglottis with no evident bleeding site. Using a large gauge needle aspiration of thick yellowish fluid and decompression of the cyst was preformed to facilitate excision. After that, CO₂ laser was set at a power of 6 watts, acublade, a repeated pulse of 0.1 second, and a depth of 1 mm to completely dissect the VC with its intact mucosal lining (**Figure 2**). Next, the right vocal fold nodular mass was removed using the cold excision technique. Histopathology analysis showed that the vallecular lesion had benign squamous epithelium outlining,

cyst like invaginations and no atypical changes noted. Whereas the vocal fold lesion findings were consistent with a benign fibrous nodule. Also, fluid cytology from the VC did not show the presence of atypical cells. Tissue culture of the VC showed growth of *Escherichia coli*, which was sensitive to most antibiotics and no fungal growth. The patient was discharged the next day with no complications on Cefuroxime 500 mg twice daily for one week. In a follow up 2 months post surgery, his symptoms were relieved and endoscopic examination showed no recurrence (**Figure 3**).

Discussion. Laryngeal cysts are considered rare lesions. In a 10-year review at the Mayo Clinic, DeSanto et al,⁵ reported 238 cases of laryngeal cysts and found that 52% originated from the epiglottis, with most coming from the lingual surface. However, Arens et al,² in another retrospective review of 416 cases of laryngeal cysts reported that 10.5% originated from the vallecula and the majority originated from the vocal folds. Vallecular cysts were found to be more common in adults, in the fifth and sixth decades of life.⁵ Several classification systems and theories concerning the etiology of laryngeal cysts were suggested. The first classification was by Myerson⁸ who separated laryngeal cysts into 4 types: retention, congenital, traumatic, and lymph or blood cysts. However, the most popular classification was by DeSanto et al⁵ as he classified laryngeal cysts into either ductal cysts, which account for 75% of all laryngeal cysts or saccular cysts which account for 25%. Ductal cysts as he explained were the result of submucous gland obstruction and subsequent fluid retention and were mostly found at the vallecula. On the other hand, Saccular cysts were due to obstruction of the saccular orifice in the laryngeal

ventricle.⁵ Newman et al,¹ used histological diagnosis to divide laryngeal cysts into epithelial cysts (subgroups being saccular and ductal), tonsillar cysts (has abundant follicular lymphoid tissue with squamous-lined crypt-like structures) and oncocyctic cysts (lined by epithelium which had undergone oncocyctic metaplasia). In the present case, the VC was lined by squamous epithelium, but there was no lymphoid element or oncocyctic changes noted. On the other hand, Arens et al,² used histomorphology and location to classify laryngeal cysts into congenital, retention and inclusion cysts. He classified congenital cysts as a separate entity as controversy surrounded its origin and a recent classification system was introduced to classify congenital laryngeal cysts to clear that confusion.⁹ Presenting symptoms of a VC varies depending on its size, amount of airway obstruction, as well as age of the patient. In infants, inspiratory stridor and dyspnea are frequently noted, whereas in older children feeding difficulties and failure to thrive are the most common symptoms.^{3,10} In adults, they tend to be asymptomatic,⁵ discovered incidentally during an otolaryngologist examination or by an anesthetist upon induction of general anaesthesia leading to a difficult intubation.¹¹ Symptomatic adults usually present with hoarseness, throat pain, foreign body sensation, and dysphagia.^{1,2} Rarely, a laryngeal cyst can present as sudden death in an adult.¹² Other than the case presented, the presentation of hemoptysis in a case with a laryngeal cyst has only been reported once in literature.¹³ Secondary infection of a VC could lead to such a presentation and may possibly progress to epiglottitis or an epiglottic abscess. *Streptococcus pneumoniae*, *Beta-hemolytic streptococci*, and *Staphylococci* were the most prevalent in these cases.^{7,14} With the significant smoking history demonstrated in this case, laryngeal malignancies also should be excluded as they can masquerade as a laryngeal cyst.¹⁵ Evaluation of a suspected case of VC should start with rigid or flexible endoscopic examination of the pharynx and larynx, in which visualization of the airway down to the vocal folds is easily carried out and an obstructing lesion could be easily seen. There is dispute among authors as what to do next in terms of imaging. Some suggest a lateral neck x-ray which in infants can be difficult to interpret and could also mimic acute epiglottitis with the thumb sign.^{3,7} Others suggest a CT scan or an MRI of the airway which localizes the lesion, shows its extent, and can differentiate fluid-filled cysts from air-filled laryngoceles. A thyroid scan is also advisable to exclude the possibility of an ectopic thyroid.^{3,9,16} Definitive diagnosis involves direct visualization of the lesion under general anesthesia via laryngoscopy. The standard options of treatment include endoscopic excision,

marsupialization, and deroofting with or without a CO₂ laser.^{2,7,16} Also, removal of the cyst using an eve's tonsillar snare was described.¹⁷ In a recent prospective clinical series by Su et al,⁶ the safety and effectiveness of laser marsupialization of epiglottic cysts via a transoral route was evaluated in 28 patients. All of the patients enrolled did not have perioperative complications or recurrences in a mean follow-up period of 16 months. Furthermore, the authors explained how this procedure is superior to the classical cold techniques, which were time consuming, resulted in intra-operative bleeding, possible cyst rupture and high recurrence rates. Other authors⁷ advocated complete excision of the VC by CO₂ laser after decompression by aspiration. This technique was used in the presented case and proved to be effective, free of complications and with no recurrence after 2 months.

In conclusion, although laryngeal cysts are rare lesions they should be thought of as a cause in any patient presenting with airway complaints or voice changes. Hemoptysis seen in this case is a very rare presentation of a laryngeal cyst, reported only once in literature, but may indicate cyst infection or a malignancy which should be excluded and dealt with promptly.

References

1. Newman BH, Taxy JB, Laker HI. Laryngeal cysts in adults: a clinicopathologic study of 20 cases. *Am J Clin Pathol* 1984; 81: 715-720.
2. Arens C, Glanz H, Kleinsasser O. Clinical and morphological aspects of laryngeal cysts. *Eur Arch Otorhinolaryngol* 1997; 254: 430-436.
3. Gutierrez JP, Berkowitz RG, Robertson CF. Vallecular cysts in newborns and young infants. *Pediatr Pulmonol* 1999; 27: 282-285.
4. Keenleyside HB, Greenway RE. Management of pre-epiglottic cysts: a report of nine cases. *CMAJ* 1968; 99: 645-649.
5. DeSanto LW, Devine KD, Weiland LH. Cyst of the larynx: classification. *Laryngoscope* 1970; 80:145-176.
6. Su CY, Hsu JL. Transoral Laser Marsupialization of Epiglottic Cysts. *Laryngoscope* 2007; 117: 1153-1154.
7. Fang TJ, Cheng KS, Li HY. A huge epiglottic cyst causing airway obstruction in an adult. *Chan Gung Med J* 2002; 25: 275-278.
8. Myerson MC. Cysts of the larynx. *Arch Otolaryngol* 1933; 18: 281-290.
9. Forte V, Fuoco G, James A. A New Classification System for Congenital Laryngeal Cysts. *Laryngoscope* 2004; 114: 1123-1127.
10. Tuncer U, Aydogan LB, Soylu L. Vallecular cyst: a cause of failure to thrive in an infant. *Int J Pediatr Otorhinolaryngol* 2002; 65: 133-135.
11. Rivo J, Matot I. Asymptomatic vallecular cyst: airway management considerations. *J Clin Anesth* 2001; 13: 383-386.

12. Kastowsky T, Stevenson M, Dufflou J. Sudden Death from Saccular Laryngeal Cyst. *J Forensic Sci* 2006; 51: 1144-1146.
13. Yadav SP, Sahni JK, Raj B, Chawla RK, Yadav J, Singh B. Laryngeal cyst-causing haemoptysis. An unusual presentation. *Indian J Chest Dis Allied Sci* 1986; 28: 50-51.
14. Heeneman H, Ward KM. Epiglottic abscess: its occurrence and management. *J Otolaryngol* 1977; 6: 31-36.
15. Chang KP, Lee LY, Yeh AR, Dai TS, Hao SP. Endoscopic CO₂ laser surgery for an atypical carcinoid tumor of the epiglottis masquerading as a supraglottic cyst. *Head Neck* 2005; 27: 1004-1007.
16. Hsieh WS, Yang PH, Wong KS, Li HY, Wang ER, Yeh TF. Vallecular cyst: an uncommon cause of stridor in newborn infants. *Eur J Pediatr* 2000; 159: 79-81.
17. Bhandary S. Innovative Surgical Technique in the Management of Vallecular Cyst. *Online J Health Allied Scs* 2003; 3: 2.

Case Reports

Case reports will only be considered for unusual topics that add something new to the literature. All Case Reports should include at least one figure. Written informed consent for publication must accompany any photograph in which the subject can be identified. Figures should be submitted with a 300 dpi resolution when submitting electronically or printed on high-contrast glossy paper when submitting print copies. The abstract should be unstructured, and the introductory section should always include the objective and reason why the author is presenting this particular case. References should be up to date, preferably not exceeding 15.