Anatomy of the azygos vein examined by computerized tomography imaging

Ilkan Tatar, MD, Cemil C. Denk, MD, PhD, Hamdi H. Celik, MD, PhD, Aytekin Oto, MD, Devrim A. Karaosmanoglu, MD, Bulent M. Ozdemir, MD, PhD, Selcuk H. Surucu, MD, PhD.

ABSTRACT

الأهداف: فحص تشريح الوريد المفرد (AV) باستعمال مختلف المقاييس. لذلك فقد تم استعمال الأشعة المقطعية (CT) في قياس مقياس الوريد المفرد (AV) عند فتحه إلى الوريد الأجوف العلوي ومستوى فتح الأوردة المفردة (AV) إلى الوريد الأجوف العلوي وموضع الأوردة المفردة (AV) مع اعتبار العمود الفقري والأرينة.

الطريقة: تم تقييم الأشعة المقطعية (CT) للصدر لعدد 103 حالة منهم 42 (40.8%) أنثى، و61 (59.2%) ذكر، في جامعة هيسيتيب بكلية الطب – قسم الأشعة – أنقرة – تركيا، خلال الفترة ما بين يوليو 2004م وحتى فبراير 2005م. أجريت الفحوصات الإشعاعية (CT) باستخدام جهاز فيليبس (AU E1 الحلزوني CT)، بالقياسات التالية: 200 mAs، 120 Hv، السماكة: 7mm، النبرة:1، مدخل إعادة البناء:7mm. تم تحليل النتائج إحصائيا.

النتائج: تراوح قياس الوريد المفرد (AV) عند الفتح إلى الوريد الأجوف العلوي بين 4.3mm و 16mm. كانت الأوردة المفردة (AV) في الخط الوسطي لدى 41 حالة. كان القوس ومستوى الفتح لدى الأوردة المفردة (AV) عند مستوى الفقرة الصدرية الخامسة لدى معظم الحالات. كان مستوى الفتح في الغالب عند نفس المستوي للقحف. تم اكتشاف الأوردة الوريدية المنصفة لدى 90 مريض.

خاتمة: قد تكون هذه القياسات التي استخدمت في هذه الدراسة مفيدة في العمليات الجراحية لمنتصف الحيزوم وخلال توضيحات صور إشاعة الصدر.

Objective: To examine the anatomy of the azygos vein (AV) using different parameters. Therefore, the diameter of the AV at its opening into the superior vena cava, the opening level of the AV into the superior vena cava, and the position of the AV, with respect to the vertebral column and carina, were examined by CT.

Methods: Chest CTs of 103 cases (42 female and 61 male) were reviewed at the Department of Radiology, Faculty of Medicine, Hacettepe University, Ankara, Turkey between July 2004 and February 2005. The CT examinations were performed with a Philips AU E1 spiral CT (Rotterdam, Netherlands) with the following parameters: 120 Hv; 200 mAs; slice thickness: 7 mm; pitch: 1; reconstruction index: 7 mm. The results were statistically analyzed.

Results: The diameter of the AV at the opening into the superior vena cava ranged between 4.3 mm and 16 mm. The AV was in the midline in 41 cases. The arching and opening level of the AV was at the fifth thoracic vertebra in most cases. The opening level was most often at the same level as the carina. Hemiazygos veins were detected in 90 patients.

Conclusion: The parameters measured in this study may be useful in surgical procedures of the mediastinum and during the interpretation of chest radiographs.

Saudi Med J 2008; Vol. 29 (11): 1585-1588

From the Departments of Anatomy (Tatar, Denk, Celik, Ozdemir, Surucu), and Radiology (Oto, Karaosmanoglu), Faculty of Medicine, Hacettepe University, Ankara, Turkey.

Received 13th July 2008. Accepted 13th October 2008.

Address correspondence and reprint request to: Dr. Ilkan Tatar, Department of Anatomy, Medical School, Hacettepe University, Sihhye, Ankara 06100, Turkey. Tel. +90 (312) 3052101. Fax. +90 (312) 3107169. E-mail: ilkan@hacettepe.edu.tr

The azygos vein (AV) arises in the abdomen and passes into the thorax with the hemiazygos and serves as the primary venous drainage pathway for the thoracic wall and the contents of the posterior mediastinum. In the thoracic cavity the AV courses upwards on the right side of the anterior surface of the vertebral column. It is situated on the right side of the thoracic duct, posterior to the esophagus, and just in front of the right posterior intercostal arteries. At its cranial end it arches forward and medially, just above the right main bronchus, to join the superior vena cava.[1,2] The course of the AV varies widely.[2-7] In a study comprising 200 subjects the

frequency of deviation from the normal pattern was observed in 26% of the subjects,[8] and these variations are said to occur during embryological development.[9] Determining the normal diameter of the AV might prove to be important, considering the various clinical conditions affecting it, for example aneurysms and indentations due to malignant processes.[10,11] In the present study we aimed to outline the anatomical variations of the AV, the diameter, and the level of its terminus of AV and its course with respect to thoracic structures.

Methods. Chest CTs of 103 cases were reviewed at the Department of Radiology, Faculty of Medicine, Hacettepe University, Ankara, Turkey between July 2004 and February 2005. Among the 103 cases, 42 were female and 61 were male (**Table 1**). The patients selected from the database of normal CT scans, which contained no known chest pathology and ranged in age from 18-83 years (median: 47 years) (**Table 2**). All patients signed informed approval form before the CT scans. The CT examinations were performed with a Philips AU E1 spiral CT (Rotterdam, Netherlands) with the following parameters: 120 Hv; 200 mAs; slice thickness: 7 mm; pitch: 1; reconstruction index: 7 mm. In total, 150 ml of intravenous contrast material was administered at a rate of 3-4 ml/sec. The study group consisted of patients that underwent chest CT examination due to several reasons, the most common being to stage extra-thoracic malignancies. The patients with intrathoracic malignancies and a history of thoracic surgery were excluded from the study. All of the participants were free from any thoracic disorders. The parameters we evaluated were the presence of a hemiazygos vein (HAV) and an accessory HAV, the position of the AV with respect to the adjacent vertebrae, vertebral column, and carina, and the diameter of the AV at the level of its opening to the superior vena cava (**Figures 1-3**). Variations in the anatomy of the azygos system were evaluated as well.

The collected data were evaluated using the independent samples t-test and the Mann-Whitney U test. We also calculated Spearman's correlation coefficients. Data were analyzed using Statistical Package for the Social Science (SPSS version 10.0) for windows.

Results. Hemiazygos veins were detected in 90 patients (87.4%); 50 (55.5%) of the hemiazygos veins were detected in males versus 40 (44.5%) in females. The mean age of the cases was 47.08 years. Azygos vein diameter just at the opening into the superior vena cava ranged between 4.3 mm and 16 mm. The overall mean diameter was 8.1 mm: 8.2 mm in males and 7.8 mm in females (**Table 2**). The azygos vein was on the right side of the body in 39 (37.9%) cases and the mean distance

Table 1 - Gender distribution of the subjects.

Characteristic	Frequency	(%)	Valid (%)	Cumulative (%)
Male	61	(59.2)	(59.2)	(59.2)
Female	42	(40.8)	(40.8)	(100)
Total	**103**	**(100)**	**(100)**	

Table 2 - Statistical analysis of subject's ages and diameter of the azygos vein (mm).

Characteristic	n	Minimum	Maximum	Mean	Standard deviation
Age	103	18.00	81.00	47.0818	22.06
Diameter	103	4.30	16.00	8.1126	2.02
Male	61	4.70	16.00	8.2	2.55
Female	42	4.30	15.55	7.8	2.35

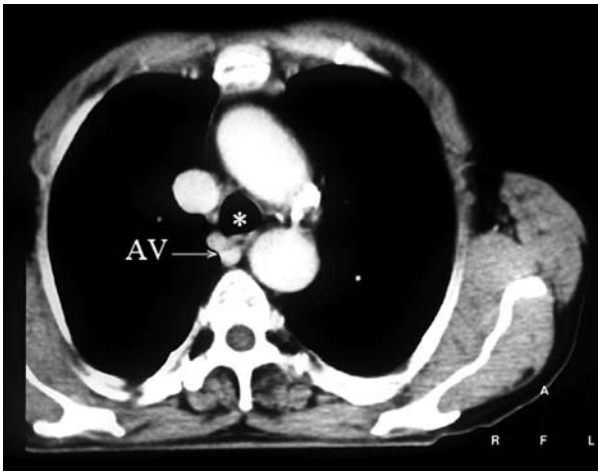

Figure 1 - The azygos vein (AV) is shown at upper thoracic region. *Trachea

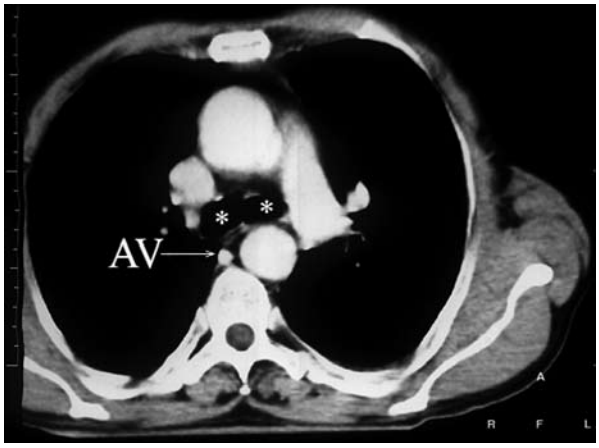

Figure 2 - The azygos vein (AV) is shown at tracheal bifurcation. *Right and left main bronchus

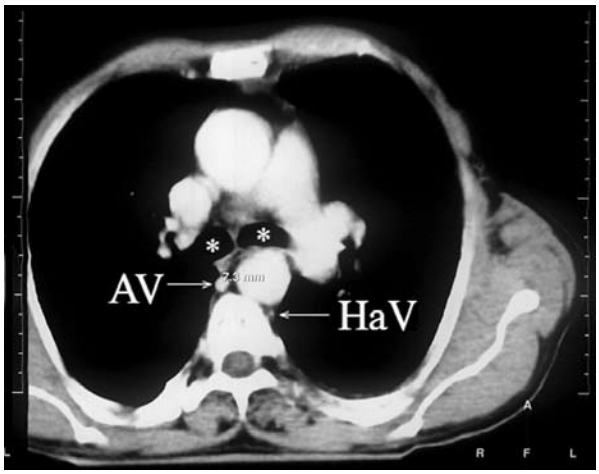

Figure 3 - The diameter measurement of the azygos vein (AV) is shown at the level of left and right main bronchus. *Right and left main bronchus, HAV - hemiazygos vein

to the midline was 6.4 mm. In 23 (22.3%) cases the azygos vein was on the left side and the mean distance to the midline was 7.5 mm. In the remaining 41 (39.8%) subjects it were located at the midline and in front of the vertebral column. The opening level of the azygos vein into the superior vena cava was between the 4th and 6th thoracic vertebrae. The arching it made before draining into the superior vena cava was at the T4 level in 40% of the cases, at T5 in 55%, and at T6 in 5% of the subjects. The azygos vein crossed the vertebrae to join the superior vena cava at the superior part of the body of the vertebra in 42 (40.8 %), at midlevel in 23 (22.3%), and at the inferior part of the body in 38 (36.9%) of the subjects. In 20 (19.4%) subjects the azygos vein was superior to the carina, in 2 (1.9%) it was at the same level as the carina, and in 81 (78.6%) it was inferior to the carina. The distance to the carina ranged from 0 mm to 15 mm, while the mean distance was 1.6 mm. Mean diameter of the azygos vein was 8.1 mm, and the difference between the genders was not statistically significant. A statistically significant difference was not also observed in the distance of the azygos vein to the midline between males and females. There was no correlation among the age, diameter, and distance to midline.

Discussion. The normal anatomy and anatomical variations of the azygos venous system were previously studied.[1,4,12-17] These studies utilized CT, magnetic resonance imaging, and 3-diamension reconstructions after the injection of gelatin-gadolinium-minimum and altufix-minimum mixtures. Based on these studies numerous variations in the origin of the azygos system were successfully outlined. The development of multi-detector CT and the application of highly sophisticated reconstruction software were groundbreaking and had tremendous impact on the non-invasive imaging of vascular anatomy, including the azygos system. With this new technology came the ability to identify the anatomy of smaller veins, and the creation of nearly isotropic multiplanar reconstructions was made possible with the use of thinner slices (even sub-millimetric) and fast scanning. Hollinshead[1] stated that the AV normally ascends on the right side of the vertebral column, arching anteriorly and medially before it drains into the superior vena cava. Bergman et al[8] studied the origin and course of the AV system as well, and reported that in cases of incomplete hemiazygos and accessory HAVs, the AV receives the left posterior intercostal veins independently, and is situated at the midline. In our study based on CT, we observed several variations of the AV. However, we should keep on mind that this study is an only definitive and retrospective radio-anatomical research.

In the present study, the AV was at the midline in 39.8% of the subjects, on the right side of the vertebral column in 37.9%, and on the left side of the vertebral column in 22.3%. Mean distance of the AV to the midline was also examined in this study when it did not ascend at the midline and was found to be 4.2 mm. In the present study, the HAV was observed to have greater anatomical variation in its origin than the AV. Interestingly, the HAV was absent in 12.6% of the cases. In a previous study the hemiazygos and accessory HAVs were incompletely formed in 15% of individuals,[8] close to our percentage. When this occurs, the posterior intercostal veins on the left side of the thorax may drain into the AV independently. If the AV is incompletely formed, then its usual tributaries directly join the AV.[8] We also examined the effect of developmental agenesis of the HAV, regarding whether or not it contributes to the overall diameter of the AV, and did not observe a significant effect.

Our study group included both male and female subjects of varying age, allowing us to examine the differences between the genders. Ultimately, we did not find any statistically significant differences in the parameters related to the AV system based on gender. In addition, a statistically significant difference was not observed between the different age groups when identical parameters were compared. In this study the location of the final arching of the AV before joining the superior vena cava was observed at the T4 level in 40% of the subjects, at T5 in 55%, and at T6 in 5%. In the literature the reference point related to arching of the AV is reported to be over the right main bronchus.[1] The vertebrae that we outlined in the present study may prove to be useful anatomical landmarks that

could serve as reference points for clinical and research purposes. Differences in AV diameter between subjects may be important, depending on particular clinical circumstances. Trigaux et al[18] measured the diameter of the AV in 3 different groups: normal subjects, subjects with lung opacity, and subjects with lung sequestration. The level of the measurement was the midpoint between the upper pole of the kidney and the inferior pulmonary vein. The diameter of the AV was 10.4 ± 5 mm in the normal group, while the diameter was larger in cases with posterobasal opacity.

In our study the mean diameter of the AV measured at the point it joins the superior vena cava was 8.1 mm; the difference between the genders was not statistically significant. The location of the AV at the point it drains into the superior vena cava, with respect to the body of the vertebra and the carina, was also observed in the present study to determine the exact position of the vein. It was at the superior part of the body of the vertebra in 40.8% of the subjects, at midlevel in 22.3%, and at the inferior part in 36.9%. In 20 of the 103 cases it was located superior to the carina, in 81 it was inferior, and in 2 it was at the same level as the carina. Mean distance to the carina was 1.6 mm. The results of this study demonstrate that the position of the AV at the point it drains into the superior vena cava is between vertebrae T4 and T6, just inferior to the carina.

The results of the present study can be used in the evaluation of chest CTs in order to prevent over diagnosis, which is a result of the wide latitude of AV variation. These measurement data might be beneficial for pre-operative arrangement of the AV pathologies, discussed by many authors, such as AV diverticulum,[19] penetrating trauma of the azygos system,[20] giant AV varix,[21] and idiopathic saccular AV aneurysm.[22] This may also be extremely useful during these invasive mediastinal procedures, which are performed with ever increasing frequency with minimally invasive surgical techniques that do not provide surgeons with a wide enough view. In the future, comparative CT and MRI studies of the azygos vein and surgical cadaveric models of the clinical conditions mentioned above might be collaborative with recent studies.

References

1. Hollinshead WH, editor. Anatomy for surgeons. 2nd ed. New York: Harper & Row; 1971. p. 579-580.
2. Williams PL, Bannister LH, Berry MM, Collins P. Veins of the thorax. Gray's Anatomy, 38th ed. New York (NY): Churchill-Livingstone; 1995. p. 1593-1594.
3. Anson BJ, editor. Morris' Human Anatomy. 12th ed. New York (NY): McGraw-Hill Book Company, The Blakiston Division; 1966. p. 420-496.
4. Bergman RA, Thompson SA, Afifi AK, Saadeh FA, editors. Compendium of Human Anatomic Variation: Catalog, Atlas and world Literature. Baltimore and Munich: Urban & Schwarzenberg; 1988. 30-81.
5. Çelik HH, Sargon MF, Aldur MM, Cumhur M. An anomalous course of the interazygos vein. ***Surg Radiol Anat*** 1996; 18: 61-62.
6. Ozbek A, Dalcik C, Colak T, Dalcik H. Multiple variations of the azygos venous system. ***Surg Radiol Anat*** 1999; 21: 83-85.
7. Özdemir B, Aldur MM, Çelik HH. Multiple variations in the azygos venous system: a preaortic interazygos vein and the absence of hemiazygos vein. ***Surg Radiol Anat*** 2002; 24: 68-70.
8. Bergman RA, Afifi AK, Miyauchi RB. Virtual Hospital: Illustrated Encyclopedia of Human Anatomic Variation. c1995 [2008; Cited October 6th, 2008]. Available from: URL http://www.anatomyatlases.org/AnatomicVariants/Cardiovascular/Text/Veins/Azygos.shtml.
9. Moore KL, Persaud TVN, editors. The cardiovascular system. The Developing Human-Clinically Oriented Embryology. 5th ed. Philadelphia (PA): WB Saunders; 1993. p. 305-308.
10. Westra D, Verbeeten B Jr. Some anatomical variants and pitfalls in computed tomography of the trachea and mainstem bronchi. II. Compression of anatomical variants? ***Diagn Imaging Clin Med*** 1985; 54: 285-297.
11. Barraine R, Gasquet C, Tournoux B, Bordage JP, Bonneau A. Aneurysm of the azygos vein. ***Arch Mal Coeur Vaiss*** 1981; 74: 755-759.
12. Nathan H. Anatomical observation on the course of the azygos vein. ***Thorax*** 1960; 15: 229-232.
13. Laterjet A. Testut's Traite d'Anatomie Humaine. 9th ed. Paris: G. Doin & Cie; 1948. 205-396.
14. Heller A. Anomalies of Azygos vein. ***German Pathology Association's Reports*** 1900; 12: 248. (German)
15. Morison BG. The arrangement of the azygos and superior intercostal veins in thorax. ***J Anat Physiol*** 1879; 13: 346-349.
16. Poytner CWM. Congenital anomalies of the arteries and veins of the human body with bibliography. ***Studies of the University of Nebraska*** 1922; 22: 1-106.
17. Sieb GA. The Azygos system of veins in American White and American Negroes, including observations on the inferior caval venous system. ***Am J Phys Anthropol*** 1934; 19: 39-163.
18. Trigaux JP, Jamart J, Van Beers B, Goncette L, Pringot J. Pulmonary sequestration. Visualization of an enlarged azygos system by CT. ***Acta Radiol*** 1995; 36: 265-269.
19. Caramutti VM, Zaidman JC, Abud JA, Gabe ED. Azygos vein diverticulum. ***Ann Thorac Surg*** 2000; 70: 665-666.
20. Wall MJ Jr, Mattox KL, DeBakey ME. Injuries to the azygos venous system. ***J Trauma*** 2006; 60: 357-362.
21. Podbielski FJ, Sam AD II, Halldorsson AO, Iasha-Sznajder J, Vigneswaran WT. Giant Azygos Vein Varix. ***Ann Thorac Surg*** 1997; 63: 1167-1169.
22. Watanabe A, Kusajima K, Aisaka N, Sugawara H, Tsunematsu K. Idiopathic Saccular Azygos Vein Aneurysm. ***Ann Thorac Surg*** 1998; 65: 1459-1461.