

Role of tissue harmonic imaging in characterization of cystic renal lesions

Asmi Mohammed MD, Manavjit S. Sandhu, MD, Anupam Lal, MD, Kushaljit S. Sodhi, MD, Kamal Sud, MD, DM, Harbir S. Kohli, MD, DM.

ABSTRACT

الأهداف: تحديد الفائدة من التصوير الهرموني النسيجي في تقييم الآفات الكيسية الكلوية، ومقارنة هذه النتائج مع التصوير بالموجات فوق الصوتية التقليدية (USG) والتصوير المقطعي الطبقي (CT).

الطريقة: شملت هذه الدراسة 30 مريضاً أكتشف إصابتهم بآفات كيسية كلوية عن طريق الموجات فوق الصوتية التقليدية (GSI)، على مدى 18 شهراً، خلال الفترة مابين يوليو 2004م وحتى ديسمبر 2005م، في مؤسسة الدراسات العليا للتعليم الطبي والأبحاث – شانديغار – الهند. خضع جميع المرضى لأشعة الموجات فوق الصوتية التقليدية (GSI) عقبها التصوير الهرموني النسيجي (THI) على نفس الآلة. اجري لهم التصوير المقطعي للبطن بعد أسبوع واحد من إجراء الفحص بالموجات فوق الصوتية. تم تقييم جميع الصور من حيث الحجم، العدد، وموقع الآفات. تم تسجيل نتائج الفحص بالتصوير الهرموني النسيجي (THI)، الفحص بالموجات فوق الصوتية للبطن (USG)، والفحص بالأشعة المقطعية للبطن (CT) في الأشكال المستقبلية. كما تم تقييم الصور التي تم الحصول عليها بواسطة التصوير بالموجات فوق الصوتية (GSI)، والتصوير الهرموني النسيجي (THI)، والتصوير المقطعي (CECT) من أجل جودة نوعية الصور، درجة الوضوح، وتمييز السائل والصلب.

النتائج: أظهر التصوير الهرموني النسيجي جودة نوعية في الصور أفضل في 27 آفة من 34 آفة. تبين وجود أهمية الوضوح للآفة في 27 آفة كيسية من 34 آفة، وتمييز السائل والصلب المطور في 30 آفة من 34 آفة عند المقارنة مع التصوير بالموجات فوق الصوتية (GSI). زود التصوير الهرموني النسيجي (THI) معلومات إضافية مقارنة مع التصوير بالموجات فوق الصوتية (GSI) في 8 مرضى. كانت درجة التصوير بالأشعة المقطعية (CT) أعلى بشكل ملحوظ من حيث جودة ونوعية الصور بشكل عام ($p=0.007$) ووضوح الآفات ($p=0.004$)، ولكنها لم تكن ملحوظة من حيث التمييز بين السائل والصلب ($p=0.23$).

خاتمة: يوفر التصوير الهرموني النسيجي (THI) جودة ونوعية أعلى للصور، تخطيط الآفة، والصفات العلوية بشكل أفضل من التصوير بأشعة الموجات فوق الصوتية التقليدية (GSI).

Objectives: To determine the utility of tissue harmonic imaging in evaluating cystic renal lesions and to compare these findings with conventional ultrasound guidance (USG) and CT.

Methods: Thirty patients, detected with cystic renal lesions on routine USG (over a period of 18 months from July 2004 to December 2005 at the Postgraduate Institute of Medical Education and Research Chandigarh, Chandigarh, India) were included in this study. All patients underwent a conventional gray scale ultrasound study (GSI), followed by tissue harmonic imaging (THI) sonography on the same machine (advance technology limited high definition imaging 5000). Computed tomography of abdomen was carried out within one week of the ultrasound examinations. All images were evaluated for size, number, and location of lesions. The findings of THI sonography, conventional USG and CT of abdomen were recorded in their respective proformas. The images obtained by GSI, THI, and contrast enhanced CT were also evaluated for image quality, lesion conspicuity, and fluid-solid differentiation.

Results: Tissue harmonic imaging showed better image quality in 27 of 34 lesions, improvement in lesion conspicuity was found in 27 of 34 cystic lesions, and an improved solid-fluid differentiation in 30 of 34 lesions when compared to GSI. The THI provided additional information as compared to GSI in 8 patients. The grading of CT scan was significantly higher in overall image quality ($p=0.007$) and lesion conspicuity ($p=0.004$), but was non-significant for fluid-solid differentiation ($p=0.23$).

Conclusion: Tissue harmonic imaging provides better image quality, lesion delineation, and superior characterization than conventional gray scale sonography.

Saudi Med J 2008; Vol. 29 (12): 1769-1774

From the Departments of Radiodiagnosis (Mohammed, Sandhu, Lal, Sodhi,) and Nephrology (Sud, Kohli), Postgraduate Institute of Medical Education and Research Chandigarh, Chandigarh, India.

Received 3rd August 2008. Accepted 8th November 2008.

Address correspondence and reprint request to: Professor Manavjit S. Sandhu, Department of Radiodiagnosis, Postgraduate Institute of Medical Education and Research Chandigarh, H.No. 220, Sector 9-C, Chandigarh 160009, India. Tel. +91 (172) 2742136/2741311. Fax. +91 (172) 2745768. E-mail: manavjitsandhu@yahoo.com

Tissue harmonic imaging (THI) is a recent sonographic technique that has opened up new prospects for gray scale ultrasound imaging (GSI). Tissue harmonic imaging is based on the phenomenon of nonlinear distortion of an acoustic signal as it travels through the body.¹ Harmonic waves are generated within the tissue and built up with depth to a point of maximal intensity before they decrease because of attenuation.¹ In comparison, conventional ultrasound guidance (USG) waves are generated at the surface of a transducer and progressively decrease as they traverse the body. Harmonic wave frequencies are higher integral multiples of transmitted frequency. Conventional sonography uses the same frequency bandwidth for both the transmitted and the received signals.

Currently the second harmonic frequency is used for THI in conventional ultrasound machines. The harmonic band is generated by the tissue itself with the distorted and scattered energy much weaker than the transmitted energy generating much weaker harmonics. Therefore, THI contains minimal noise and side lobe artifacts and reverberations and the resultant images are clearer and relatively free from artifacts when compared with the fundamental image.¹ Tissue harmonic imaging is superior to other sonographic modes for overall image quality, lesion conspicuity, and elimination of unwanted artifacts. Tissue harmonic imaging is also cheaper, simple, non-invasive, and non-ionizing compared to contrast enhanced computed tomography (CECT). The elimination of artifacts and pronounced posterior wall acoustic enhancement helps to distinguish solid from cystic components. Also, borders and internal components (septations and debris) are better depicted.²

Cysts of kidney are the most common lesions of kidneys. While simple uncomplicated cysts are easy to diagnose, complicated cystic lesions can create considerable difficulty in diagnosis and can lead to a difference in opinion concerning the proper diagnostic and therapeutic approach. The proper and accurate classifications of renal cysts based on radiological findings help in handling the commonly encountered lesions in the most economical and least invasive manner. Conventionally, USG and CECT have been used to diagnose and characterize renal cysts. With the availability of THI, the diagnostic accuracy of USG is likely to improve and possibly replace CECT, which is expensive, causes radiation, and requires contrast administration as well. As there was little dedicated work published on this particular subject, in this targeted prospective study, the usefulness of THI in evaluating cystic renal lesions was evaluated and these findings were compared with conventional USG and CECT.

Methods. This prospective study was conducted over a period of 18 months from July 2004 to December 2005, at the Postgraduate Institute of Medical Education and Research Chandigarh, Chandigarh, India. The study was approved by the Postgraduate Institute of Medical Education and Research Chandigarh ethics committee. Informed patient consent was taken before start of enrollment of patients in the study group. They were informed on methodology to be used and utility of CT examination after ultrasound study. Thirty asymptomatic and symptomatic patients who were detected to have cystic lesions in the kidney of size >1cm on routine USG were included in this study. All patients underwent a conventional ultrasound on an advance technology limited-high definition imaging 5000 (Philips ultrasound Bothell, WA, USA) machine using a 3.5MHz sector transducer. This was followed by tissue harmonic sonography on the same machine. The imaging parameters were identical for each patient with the exception of image gain, which was optimized for each image. Contrast enhanced CT of abdomen was carried out, within one week of the ultrasound examinations, on a 16 slice multidetector CT scanner (Somatom 16 sensation, Siemens, Germany) by first taking 10/10 mm helical plain sections in the region of kidneys. Contrast enhanced CT sections were acquired from the domes of diaphragm to the pelvis after injecting 100 ml of iohexol intravenously at the rate of 2.8 ml/sec. This was followed by 5/5 mm helical sections in the region of kidneys and 3/3 mm reconstruction in the region of kidney whenever required. Exclusion criteria included patients with smaller renal lesions, <1 cm, and those patients in whom CT scan was performed later than one week.

All images were evaluated for size, number, and location of lesions. The cyst wall was evaluated with respect to its thickness, smoothness, or irregularity. The internal morphological characters of cysts including septations, internal echoes, fluid levels, and so forth were studied and lesions were characterized as per the Bosniak classification. Bosniak MA3 classified cystic lesions of kidney into 4 categories, based on USG and CECT criteria. Category I lesions are simple benign cysts showing homogeneity, water content, and a sharp interface with adjacent renal parenchyma, with no wall thickening, calcification or enhancement. Category II consists of cystic lesions with one or 2 thin (<1mm thickness) septations or thin fine calcification in their walls or septa and hyperdense benign cysts with all features of category I cysts except for homogeneously high attenuation. Category II-F consists of minimally complicated cysts that need follow up. These lesions have some suspicious features (such as wall thickening

more than 1 mm or calcification) that deserve follow up to detect any change in character. Category III consists of true indeterminate cystic masses that need surgical evaluation, although many may prove benign. They may show uniform wall thickening, nodularity, thick or irregular peripheral calcification, or a multilocular nature with multiple enhancing septa. Hyperdense lesions that do not fulfill category II criteria are included in this group. Category IV lesions have a non uniform or enhancing thick wall, enhancing or large nodules in the wall or clearly solid components in the cystic lesion. Enhancement is considered to be present when lesion components increased by at least 10 HU. The findings of THI sonography, GSI, and CECT of abdomen were recorded in their respective proformas. Each set of images was evaluated with a 3 point grading system, with a grade of 3 indicating an excellent image, a grade of 2 for a good image, and a grade of one for an unsatisfactory image. The images obtained by GSI, THI, and CECT were also evaluated for image quality, lesion conspicuity, and fluid-solid differentiation. Image quality was defined as the evaluation of spatial resolution or details of the kidneys with differentiation of the cortex and medulla, lesion conspicuity was defined as the delineation of the lesion within the kidney, and fluid-solid differentiation was defined as the definition of the lesion character. The CECT findings were taken as the gold standard. Whenever a cyst aspirate was available or surgery was carried out, the imaging findings were correlated with the cytological or histopathological findings.

The Wilcoxon sign rank test was used for comparing data obtained from GSI, THI, and CECT. The data was analyzed by Statistical Package for Social Science (SPSS, version 10) software. The p value of <0.05 was considered significant.

Results. Thirty patients (18 males, 12 females) aged 32-85 years (mean 54.3 years) were included in this study. Most patients (22) were asymptomatic, while 8 presented with pain abdomen and 2 also had fever and one had hematuria. Thirty-four cystic lesions were detected in the 30 patients included in this study. Twenty lesions were in the left kidney, while 14 were in the right kidney. Of the total 34 lesions, 7 were in the upper pole, 21 in the interpolar region and 6 in the lower pole. There were 5 lesions with a size between 10-20 mm, 12 lesions between 20-30 mm, 5 lesions between 30-40 mm, and 12 lesions which were more than 40 mm in size. There were 17 Bosniak category I cysts in this study. Twenty lesions fulfilled all the sonographic criteria for simple cysts on GSI. Three lesions which were classified as Bosniak category I on GSI but were upgraded to category II on THI due to the presence of thin septa inside them

(which were missed on GSI). The CECT in 2 of these cases also failed to show the septa. All category I cysts detected on THI fulfilled the criteria for simple cysts on CECT. There were 10 Bosniak category II cysts in this study. Nine of these lesions showed the presence of one or 2 thin septa or thin peripheral calcification on THI. One patient had a thick walled cystic lesion without any septation and underwent surgery and was proven to have a cystic lesion with no evidence of malignancy on histopathology. Five patients had Bosniak category III cysts (Figure 1). They showed presence of multiple septa, and thick or irregular peripheral calcification on GSI and THI. The CECT of these patients also showed the presence of multiple enhancing septa and/or nodular calcification. Two of these patients had presented with fever and abdominal pain and on USG guided aspiration, were found to have abscesses. One patient had USG guided fine-needle aspiration cytology, and the smear was suspicious of malignancy, however, the patient refused surgery. Two patients underwent surgery without FNAC and both had benign cystic lesions on histopathology. There were 2 Bosniak category IV cysts in this study. Gray scale ultrasound imaging showed non uniform wall thickening with solid components in these 2 cystic lesions. The THI in these patients better delineated the solid component. The CECT showed irregular enhancing wall and an enhancing solid component. Both these patients underwent surgery and were found to have renal cell carcinoma on histopathology.

Table 1 shows the result of conventional gray scale imaging, THI, and CT on a 3 point grading system for overall image quality, lesion conspicuity, and fluid-solid differentiation. The THI showed better image quality in 27 of 34 lesions, improvement in lesion conspicuity was found in 27 of 34 cystic lesions, and an improved solid-fluid differentiation in 30 of 34 lesions when compared to GSI. The THI was the better modality for overall image quality ($p=0.001$), lesion conspicuity ($p=0.001$), and fluid-solid differentiation ($p=0.001$) as compared to GSI. The THI provided additional information as compared to GSI in 8 patients (Table 2). The CECT was the best technique in all 30 patients for both overall image quality and lesion conspicuity, however for fluid solid differentiation, it was the best technique in only 32 out of total 34 patients. The grading of CECT scan was significantly higher in overall image quality ($p=0.007$) and lesion conspicuity ($p=0.004$) but was non-significant for fluid-solid differentiation ($p=0.23$).

Discussion. Ultrasonography is currently used as the first imaging modality for evaluating the kidneys and renal cysts are the most common renal lesions

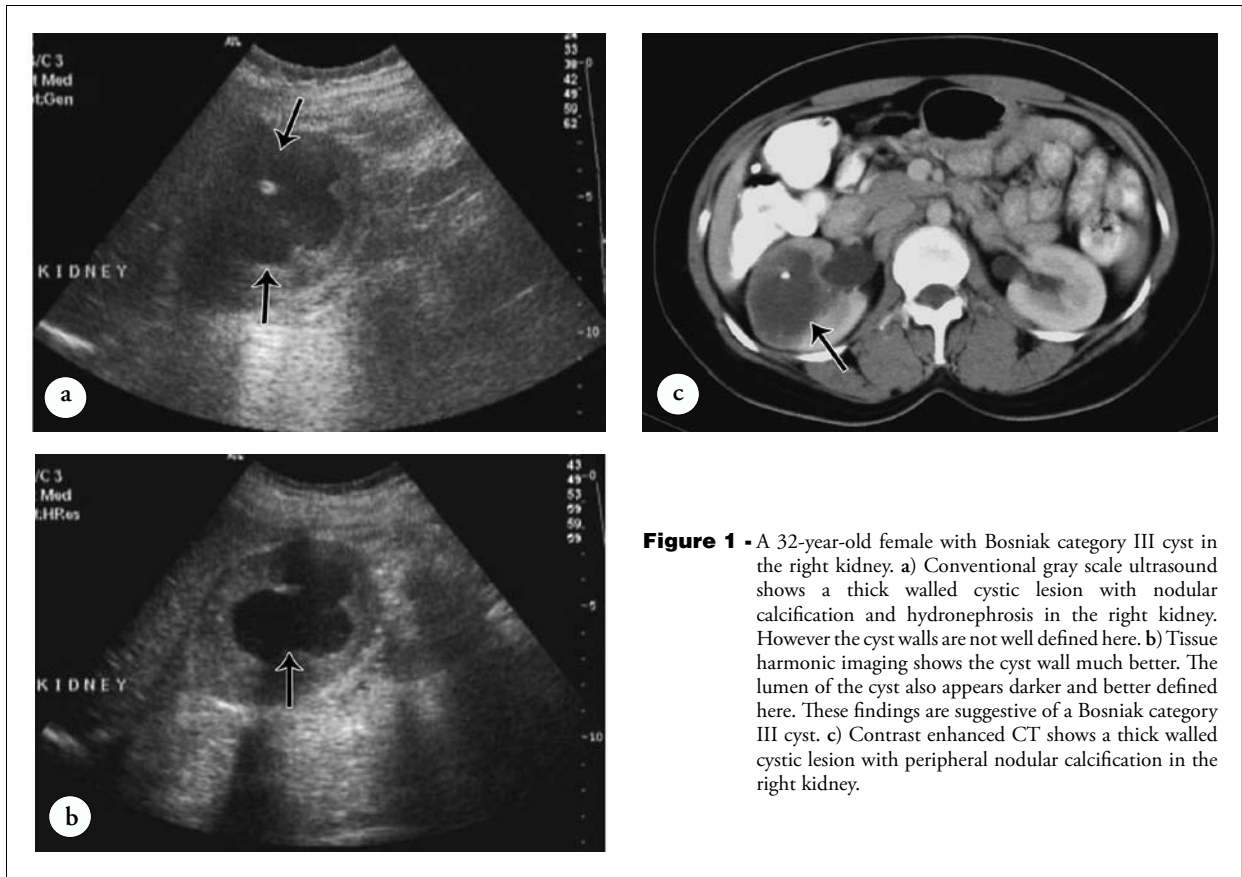


Figure 1 - A 32-year-old female with Bosniak category III cyst in the right kidney. a) Conventional gray scale ultrasound shows a thick walled cystic lesion with nodular calcification and hydronephrosis in the right kidney. However the cyst walls are not well defined here. b) Tissue harmonic imaging shows the cyst wall much better. The lumen of the cyst also appears darker and better defined here. These findings are suggestive of a Bosniak category III cyst. c) Contrast enhanced CT shows a thick walled cystic lesion with peripheral nodular calcification in the right kidney.

Table 1 - Result of THI sonography and GSI sonography versus CECT scan.

Grade	Overall image quality			Lesion conspicuity			Fluid-solid differentiation		
	GSI	THI	CECT	GSI	THI	CECT	GSI	THI	CECT
1	11	0	0	11	0	0	12	0	0
2	21	7	0	21	8	0	20	5	2
3	2	27	34	2	26	34	2	29	32

1 = unsatisfactory, 2 = good, 3 = excellent. GSI - gray scale ultrasound imaging, THI - tissue harmonic imaging, CECT - contrast enhanced computed tomography

Table 2 - Lesions in which THI provided additional information.

Serial number	Findings on GSI	Additional information on THI
1	Suspicion of debris in the lumen	No debris
2	Thick walled cyst with nodular calcification	Mural nodule
3	Thin walled cyst with internal echoes	Thick walled cyst
4	Suspicion of internal debris	No debris
5	Simple cyst	Presence of septa
6	Suspicion of internal debris	No debris
7	Simple cyst	Presence of septa
8	Simple cyst	Presence of septa
9	Suspicion of internal septa	Simple cyst

GSI - gray scale ultrasound imaging, THI - tissue harmonic imaging

detected on ultrasound, with the frequency of simple cysts increasing with advancing age.³ However, the sonographic accuracy is highly operator dependent and therefore CECT is considered the gold standard for the characterization of renal cysts.⁴ Based on radiological findings, Bosniak proposed a classification for cystic renal lesions to assist in the diagnosis and management of complex cystic lesions. In general, the proportion of patients with renal cell carcinoma increases with increasing category grade.³ Tissue harmonic imaging is a novel gray scale imaging technique in which reverberation and side lobe artifacts, which commonly degrade the assessment of fluid containing lesions, particularly in obese patients are substantially reduced, and posterior acoustic enhancement is more easily demonstrated allowing accurate characterization.⁵⁻⁹ Choudhry et al¹⁰ compared THI with conventional USG in abdominal diseases. In 100 patients studied, 202 abdominal lesions were evaluated. Of these 76 (38%) were in the liver, 67 (33%) in the kidney's, 30 (15%) in the biliary tract including gall bladder, 12 (6%) in blood vessels, and 17 (8%) in other abdominal organs including pancreas and spleen. Results showed superiority of THI over conventional USG for lesion visibility with THI being preferred over conventional USG for 62% of lesions.

The purpose of the present dedicated study was targeted to determine the role of THI in evaluating cystic lesions of kidney and to compare this with GSI, taking CECT as the gold standard. In our study, THI and CECT classification were similar in 32 of the lesions, while there was a difference in 2 lesions. In these 2 cases, THI showed the presence of septa leading to an upgrading of Bosniak classification. These results are in accordance with the results of previous studies conducted by various authors for evaluating the clinical usefulness of Bosniak classification.⁴ Importantly, in no patient was there any loss of information from THI compared with the conventional GSI. These results are also in accordance with findings of Sodhi et al⁷ and Garg et al¹¹ who evaluated THI in focal hepatic lesions and acute pancreatitis and found no case in which THI provided less information than GSI. In our study, images obtained from GSI and THI were evaluated for overall image quality and found improvement in 27 of 34 lesions with THI. In 5 cases, both THI and GSI were found to have similar image quality. In 27 lesions, THI was graded as excellent and in 7 lesions as good. Compared to this, GSI was graded excellent in 2 lesions and good in 21 lesions. There was no case in which THI was graded unsatisfactory, whereas GSI was found to be unsatisfactory in 11 lesions. Our results are in accordance with Shapiro et al¹² who reported better image quality in 50 of 60 pancreatic examination and 58 of 68 for other

anatomic areas. The THI improves lesion conspicuity because it has high contrast and spatial resolution. In this study it was found that THI was better in 27 of 34 cystic lesions. The THI therefore, provided better lesion differentiation as compared to the GSI as the cystic lesions appeared more anechoic because of the reduced reverberation artifacts. The internal solid components and septa were also diagnosed with more confidence as they were not confused so easily with reverberation artifacts in cystic lesions.

One possible limitation of our study could be the small number of patients in our study group. Larger prospective studies are suggested for further evaluating the role of THI. The THI is the better technique for the evaluation of cystic lesions in kidneys. However, CECT has better spatial resolution and has higher grades for image quality and lesion conspicuity in all the cases, hence, CECT is the best technique for evaluating renal cystic lesions and is also less operator dependent. The THI sonography produced images of much higher quality than GSI and was therefore, more diagnostic. This improvement in image quality agreed with the underlying principle of harmonic images. Tissue harmonic imaging provides better image quality, helping in much better lesion delineation and superior characterization than conventional gray scale sonography and also increases the confidence level.^{13,14} There were no patients in whom THI provided less information than gray scale imaging. The CECT was better for the evaluation of calcification in cystic lesions however, THI was better for the detection of septa and this resulted in the upgrading of Bosniak classification in 2 patients.

References

1. Oktar SO, Yucel C, Ozdemir H, Ulutürk A, Isik S. Comparison of conventional sonography, real time compound sonography, tissue harmonic sonography and tissue harmonic compound sonography of abdominal and pelvic lesions. *AJR Am J Roentgenol* 2003; 181: 1341-1347.
2. Yucel C, Ozdemir H, Asik E, Oner Y, Isik S. Benefits of tissue harmonic imaging in the evaluation of abdominal and pelvic lesions. *Abdom Imaging* 2003; 28: 103-109.
3. Bosniak MA. The current radiological approach to renal cysts. *Radiology* 1986; 158: 1-10.
4. Siegel CL, McFarland EG, Brink JA, Fisher AJ, Humphrey P, Heiken JP. CT of cystic renal masses: analysis of diagnostic performance and inter observer variation. *AJR Am J Roentgenol* 1997; 169: 819-821.
5. Lencioni R, Cioni D, Bartolozzi C. Tissue harmonic and contrast-specific imaging: back to gray scale in ultrasound. *Eur Radiol* 2002; 12: 151-165.
6. Yen CL, Jeng CM, Yang SS. The benefits of comparing conventional sonography, real-time spatial compound sonography, tissue harmonic sonography, and tissue harmonic compound sonography of hepatic lesions. *Clin Imaging* 2008; 32: 11-15.

7. Sodhi KS, Sidhu R, Gulati M, Saxena A, Suri S, Chawla Y. Role of tissue harmonic imaging in focal hepatic lesions: comparison with conventional sonography. *J Gastroenterol Hepatol* 2005; 20: 1488-1493.
8. Desser TS, Jeffrey RB Jr, Lane MJ, Ralls PW. Tissue harmonic imaging: utility in abdominal and pelvic sonography. *J Clin Ultrasound* 1999; 27: 135-142.
9. Ward B, Baker AC, Humphrey VF. Non linear propagation applied to the improvement of resolution in diagnostic medical ultrasound. *J Acoust Soc Am* 1997; 101: 143-154.
10. Choudhry S, Gorman B, Charboneau JW, Tradup DJ, Beck RJ, Kofler JM, et al. Comparison of tissue harmonic imaging with conventional US in abdominal disease. *Radiographics* 2000; 20: 1127-1135.
11. Garg M, Sandhu M, Sood B, Lal A. Tissue harmonic imaging in the evaluation of acute pancreatitis. *Australian Radiol* 2004; 48: 117-122.
12. Shapiro RS, Wagreich J, Parsons RB, Stancato-Pasik A, Yeh HC, Lao R. Tissue harmonic sonography: evaluation of image compared with conventional sonography. *AJR Am J Roentgenol* 1998; 171: 1203-1206.
13. Chiou SY, Forsberg F, Fox TB, Needleman L. Comparing differential tissue harmonic imaging with tissue harmonic and fundamental gray scale imaging of the liver. *J Ultrasound Med* 2007; 26: 1557-1563.
14. Mitterberger M, Pinggera GM, Pallwein L, Gradl J, Feuchtnr G, Plattner R, et al. Plain abdominal radiography with transabdominal native tissue harmonic imaging ultrasonography vs unenhanced computed tomography in renal colic. *BJU Int* 2007; 100: 887-890.

Authorship Entitlement

Excerpts from the Uniform Requirements for Manuscripts Submitted to Biomedical Journals updated November 2003.
Available from www.icmje.org

The international Committee of Medical Journal Editors has recommended the following criteria for authorship; these criteria are still appropriate for those journals that distinguish authors from other contributors.

Authorship credit should be based on 1) substantial contributions to conception and design, or acquisition of data, or analysis and interpretation of data; 2) intellectual content; and 3) final approval of the version to be published. Authors should meet conditions 1, 2, and 3.

Acquisition of funding, collection of data, or general supervision of the research group, alone, does not justify authorship.

Author should be prepared to explain the order in which authors are listed.