P53 expression in synchronous colorectal cancer

Ulviye Yalcinkaya, MD, Ersin Ozturk, MD, Tumay Ozgur, MD, Omer Yerci, MD, Tuncay Yilmazlar, MD.

ABSTRACT

الأهداف: تم مراجعة حالات من الورم الغدي السرطاني لمعرفة وتحديد الورم الغدي السرطاني المتزامن في القولون والمستقيم (SCRC).

الطريقة: في دراسة وصفية تمت مراجعة 764 حالة خضعت لعملية استئصال جراحي للورم الغدي السرطاني الأولي للقولون والمستقيم. وتم تحويلهم لكلية الطب بجامعة اولوداق إلى قسم الأمراض الجراحية للتشخيص في الفترة ما بين عام 1997م وحتى 2006م بتركيا. تمت ملاحظة موضع الورم، وعمق الإصابة، وظهور الورم الغدي، والمسافة بين هذه الأورام المتعددة الأولية، ودرجة ونمط ظهور عنصر p53 المشير إلى المنشأ المتعدد أو وحيد النسيلة، وذلك من أجل إنشاء التأثير المحتمل على التنبؤ بالعلاج.

النتائج: كان هنالك 28 حالة مصابة بالورم الغدي السرطاني المتزامن في القولون والمستقيم (SCRC). تسعة حالات إناث و تسعة عشر حالة ذكور (الإناث: الذكور=1:2). كانت معظم الحالات في العقد الخامس والسادس من العمر. كان هنالك علاقة إحصائية ملحوظة بين ظهور عنصر p53 والحالة المختلفة (p=0.001)، وعمق الإصابة (p=0.03). أظهرت أربعين حالة من بين 62 حالة وجود سرطان غدي في القولون والمستقيم بشكل إيجابي كيميائي نسيجي مناعي لعنصر p53. أظهرت بعض الحالات نموذج تنافر لتحول عنصر p53 بين الآفات الفردية مما يشير إلى المنشأ المتعدد.

خاتمة: لا يعتبر الورم الغدي السرطاني المتزامن في القولون والمستقيم (SCRC) من الأورام النادرة، ويحدث في سلسلتنا بنسبة 3.6%. نحن نعتقد أن هنالك حاجة لإجراء المزيد من الدراسات مع سلاسل أكبر لعنصر p53 لإثبات المفيد في التنبؤ بعلاج الورم الغدي السرطاني المتزامن في القولون والمستقيم (SCRC).

Objective: We reviewed cases of primary colorectal adenocarcinoma to document synchronous colon and rectum adenocarcinoma (SCRC).

Methods: In a retrospective setting, 764 cases underwent surgical resection for primary colorectal adenocarcinoma and referred to the Department of Surgical Pathology, Uludag University, Medical Faculty for diagnoses between 1997 and 2006, were reviewed. Tumor site, depth of invasion, coexistence of adenoma, distance between these multiple primary tumors, degree of p53 expression, and p53 expression pattern indicating polyclonal or monoclonal origins were noted in order to establish a possible effect on prognosis.

Results: There were 28 cases with SCRC of colon and rectum. Nine cases were female, 19 cases were male (female to male ratio was 1:2). Most of the cases were within the 5th and the 6th decades. There were statistically significant relationships between p53 expression and differentiation status (p=0.001), and invasion depth (p=0.03). Forty of 62 colorectal carcinomas showed immunohistochemical positivity for p53. Six cases showed a discordant pattern of p53 mutation among individual lesions indicating polyclonal origin.

Conclusion: Synchronous colon and rectum adenocarcinoma is not rare. The incidence is 3.6% in our series. We believe that further studies with larger series are needed for p53 to prove useful in predicting prognosis of SCRCs and assessing the polyclonal origin of SCRC at a genetic level.

Saudi Med J 2008; Vol. 29 (6): 826-831

From the Department of Surgical Pathology (Yalcinkaya, Ozgur, Yerci), and the Department of General Surgery (Ozturk, Yilmazlar), Faculty of Medicine, Uludag University Bursa, Bursa, Turkey.

Received 5th January 2008. Accepted 19th April 2008.

Address correspondence and reprint request to: Dr. Ulviye Yalcinkaya, Department of Surgical Pathology, Faculty of Medicine, Uludag University, 16059 Bursa, Turkey. Tel. +90 (224) 2953687. Fax. +90 (224) 2950099. E-mail: drulviye@uludag.edu.tr

Synchronous colon and rectum adenocarcinoma (SCRC) is not rare.[1-3] The reported incidence differs from 1.5-7.5% in various series.[1-4] This frequency increases from 10-20% in patients with familial adenomatous polyposis, hereditary non-polyposis colorectal cancer, and ulcerative colitis.[4,5] Synchronous colon and rectum adenocarcinoma is characterized by 2 or more tumors obtained simultaneously during

examination or in the surgical specimen.[1] Each tumor has a specified malignant appearance, is histopathologically different from the other, and is not metastasis.[2,6] All such tumors typically invade the muscularis mucosa.[6] In up to 75% there are associated benign neoplasms.[2,7,8] It is unclear whether synchronous multiple tumors arise from polyclonal or monoclonal origins. Based on the molecular genetics, colorectal neoplasms are strongly associated with p53 gene mutations.[9,10] In order to verify the polyclonal origin of SCRC at a genetic level, immunohistochemical and molecular techniques may be used to determine the p53 alterations in individual lesions of SCRC.[11,12] In this study, 764 cases of primary colorectal adenocarcinoma were reviewed to document SCRC. Tumor site, depth of invasion, coexistence of adenoma, distance between these multiple primary tumors, degree of p53 expression, and p53 expression pattern indicating polyclonal or monoclonal origins were noted in order to establish a possible effect on prognosis.

Methods. Of the cases underwent surgical resection for primary colorectal adenocarcinoma and referred to the Department of Surgical Pathology, Medical Faculty Uludag University for diagnoses between 1997 and 2006, specimens of 764 cases were reviewed on a retrospective setting. Cases with familial polyposis and ulcerative colitis were excluded from the study. The following criteria were set for diagnosis of SCRC: a) presence of 2 or more invasive carcinoma in the resected specimen, b) a distance between 2 different tumor sites more than 2 cm, c) tumors originating from normal mucosa and invading basal membrane.[1,2,8,13] This study was approved by the Research Ethics Committee, Uludag University. The hematoxylin-eosin stained slides of tumors were reexamined, and new slides were prepared when necessary. Age, gender, tumor site, and distance between tumors were noted from files. Dukes' classification was used for invasion depth and TNM classification according to the American Joint Commission on Cancer (AJCC) and accepted by Internation Union against Cancer (UICC) was used for staging.[1,8] Sections of 4 µm thickness were cut from the paraffin blocks and then were deparaffinized and rehydrated through a graded series of alcohol. A microwave antigen retrieval method was used, followed by incubation with primary monoclonal anti-p53 antibody (N1581, DAKO, Carpinteria, CA, USA). Subsequent development of the antibody reaction was carried out by the labeled strepavidin-biotin method (LSAB kit, DAKO, Carpinteria, CA, USA). The tumor cells were considered to be positive for p53 when distinct nuclear staining was identified. The p53 expression degrees were classified into 4 groups: a) (-) for negative results, b) (+) for 1-25% positivity; c) (++) for 26-50% positivity, and d) (+++) for more than 51% positivity.

Statistical Package for Social Sciences for Windows version 7.5 was used for comparing the results using Chi-square and Pearson correlation tests where appropriate. A p value of less than 0.05 was taken as significant.

Results. There were 28 cases with SCRC of colon and rectum. Nine cases were female and 19 cases were male (female to male ratio was 1:2). The mean age was 58.40±12.52 years with a range between 29 and 82. Most of the cases were within the 5th and the 6th decades (**Figure 1**). In 24 cases there were SCRC in 2 different sites, while there were 3 different sites in 2 cases, and 4 different sites in the remaining 2 cases (**Figure 2**). Most of the carcinomas were more than 5 cm away from each other. Three carcinomas were separated by 6-10 cm, 7 were separated 11-20 cm and 13 were separated by more than 20 cm. Only 5 carcinomas were separated by <5 cm. Most of the SCRCs were located in the rectum and sigmoid (n=5), rectum (n=3), and sigmoid and ascending colon (n=3) (**Table 1**). Associated benign adenomatous polyps, mixed villous and adenomatous polyps, or villous polyps were present in 14 of the 28 cases of SCRC (50%). In 5 cases, single adenomatous polyps were found, while in 9 cases there were multiple

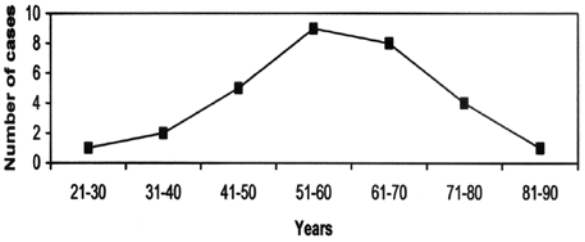

Figure 1 - Number of cases per decades.

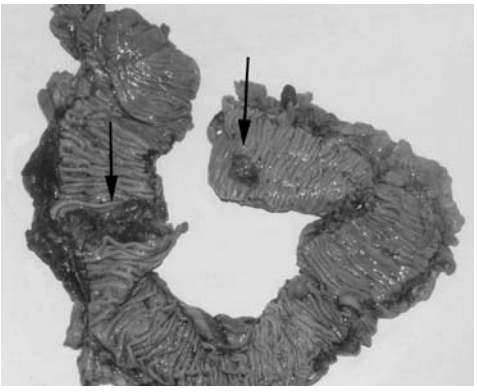

Figure 2 - Synchronous carcinomas in total colectomy specimen. Arrows indicating tumors.

Table 1 - Locations of synchronous colon and rectum adenocarcinomas.

Locations	No. of cases
Rectum	3
Rectum + sigmoid	5
Rectum + ascending colon + transverse colon	1
Rectum + cecum	2
Sigmoid + sigmoid	1
Sigmoid + rectum + sigmoid	1
Sigmoid + ascending colon	3
Sigmoid + transverse colon	2
Sigmoid + ascending colon + transverse colon + transverse colon	1
Sigmoid + ileum	1
Sigmoid + cecum	1
Ascending colon + transverse colon + descending colon + ileocecal valve	1
Ascending colon + cecum	1
Transverse colon + transverse colon	1
Transverse colon + descending colon	1
Descending colon + descending colon	2
Cecum + ileocecal valve	1

Table 2 - Depth of invasion of synchronous colon and rectum adenocarcinomas (according to Dukes' classification).

Classification	No. of cases
A + B	6
A + A	1
A + C	4
B + B	3
B + C	3
C + C	3
D + A	2
D + C	1
D + D	1
B + B + A	1
C + C + A	1
C + A + A + A	1
C + C + B + B	1
A, B, C and D - stages	

adenomatous polyps numbering between 3 and 18. Of the 62 tumors in 28 cases, 43 were moderately differentiated, 16 were poorly differentiated, and 3 were well-differentiated adenocarcinoma (**Figure 3a**). Most of the SCRCs in our study were advanced cancers according to the Duke's classification. In 6 SCRC cases with 2 lesions, depth of invasion was stage A in one and stage B in one case. In 3 cases, the lesions were both stage B. The distribution of the depths of invasion in the remainder of these cases is seen in **Table 2**. There was statistically significant relationship between p53 expression and differentiation status (p=0.001) implicating well-differentiated tumors was more likely to express p53 (**Figure 3b**). Also a statistically significant relationship was found between p53 expression and invasion depth (p=0.03). This situation was interpreted as the deeper the invasion gets, the more the p53 was expressed. Among adenocarcinoma, there was a statistically significant relationship between p53 expression and age (p=0.02), but there was no significant correlation of p53 expression with gender. Likewise there was no significant relationship between p53 expression and coexistence of benign adenomatous polyps. No statistically significant relation was found between p53 expression and prognosis, although cases with higher p53 expression seemed to have a worse prognosis. Forty of 62 colorectal carcinomas showed immunohistochemical positivity for p53. Six cases showed a discordant pattern of p53 mutation among individual lesions indicating polyclonal origin (**Table 3**). Gender, age, tumor-nodes-metastasis (TNM) stages and life span in SCRC cases are listed in **Table 4**.

Discussion. Synchronous colon and rectum adenocarcinoma is not rare with a reported incidence between 1.5-7.5% in large series.[1-4,14] In our study, there were 28 cases of SCRC in 764 cases of primary colorectal adenocarcinoma (3.6%). In various studies, SCRCs and single colorectal carcinomas (CRC) were

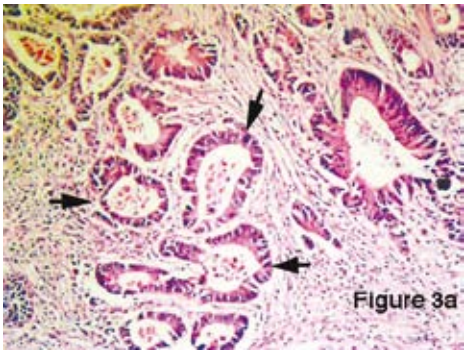

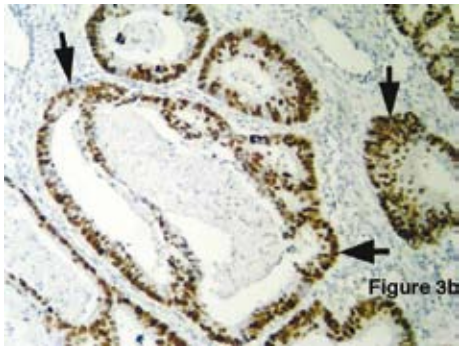

Figure 3 - Histopathological results showing **a)** Well-differentiated adenocarcinoma, hematoxylin-eosin stain, x200. **b)** Nuclear p53 expression in adenocarcinoma cells, p53, x200.

Table 3 - Discordance of p53 expression among individual lesions.

Case number	Age (years)	Gender	Tumor number	Depth of invasion	Degree of differentiation	IHC p53
1	74	Female	1	B	Moderate	1+
			2	B	Moderate	-
2	54	Male	1	C	Moderate	-
			2	C	Moderate	3+
3	56	Female	1	D	Poor	-
			2	D	Poor	3+
4	60	Females	1	C	Moderate	-
			2	C	Moderate	-
			3	A	Moderate	3+
5	62	Male	1	B	Moderate	3+
			2	B	Moderate	-
			3	A	Moderate	-
6	55	Male	1	C	Poor	1+
			2	A	Poor	-
			3	A	Moderate	-
			4	A	Moderate	1+

IHC - immunohistochemistry, A, B, C and D - stages

Table 4 - Staging and survival in synchronous colon and rectum adenocarcinomas cases.

Gender/Age	TNM/UICC Staging				Survival length
	Index cancer	Second cancer	Third cancer	Fourth cancer	
Female/55	T2N1M0	T2N0M0			58 months
Male/55	T3N2M0	T2N0M0	T1N0M0	T1N0M0	55 months
Male/69	T3N1M0	T2N0M0			UF
Male/72	T3N0M0	T1N0M0			53 months
Female/60	T2N0M0	T1N0M0			53 months
Male/82	T3N1M0	T3N0M0			51 months
Female/56	T4N2M0	T4N0M0			42 months (ex)
Male/65	T3N1M0	T2N0M0			72 months
Male/68	T4N2M1	T3N0M0			36 months (ex)
Male/39	T2N1M0	T2N1M0			84 months
Male/70	T3N1M0	T3N0M0			22 months (ex)
Male/56	T4N1M0	T4N1M0			84 months
Female/29	T3N0M0	T2N0M0			UF
Male/54	T3N1M0	T2N1M0			22 months(ex)
Male/65	T4N0M0	T4N0M0			94 months(ex)
Male/44	T4N1M0	T3N1M0	T4N0M0	T4N0M0	UF
Male/49	T3N2M0	T3N2M0			96 months(ex)
Male/55	T4N0M0	T4N0M0			28 months(ex)
Female/38	T2N0M0	T3N0M0			108 months
Female/53	T4N2M1	T1N0M0			111 months
Male/69	T2N0Mo	T3N0M0			70 months
Female/41	T3N0M0	T2N0M0			50 months
Male/77	T3N0M1	T1N0M1			45 months
Male/62	T3N0M0	T3N0M0	T1N0M0		39 months
Male/59	T4N1M0	T1N1M0			25 months
Female/60	T3N1M0	T3N1M0	T1N0M0		9 months
Female/74	T3N0M0	T3N0M0			3 months
Male/59	T3N0M0	T2N0M0			3 months

UF - unable to follow for cases dropped out of follow-up, T - tumor size, N - lymph node involvement, M - presence of metastasis and other cancer stagings

compared and patients with SCRCs were found to be older and to have worse prognosis.[6,15] Several studies showed no significant difference in survival, age and gender incidence between multiple and single CRC.[1,4] Arai et al[3] reported that carcinogenesis increases with age, and when hereditary CRCs are not taken into consideration, multiple CRCs are more frequent in the elderly. In our study, the cases were mostly in the 5th and the 6th decades of life, and the most affected sites were rectosigmoid region and ascending colon, respectively. The distance between the tumor sites is important in such adenocarcinomas, which can be very far apart in some cases. This implicates both the surgeons and endoscopist shall be extremely careful in planning treatment.[1] In a substantial number of reports, the distance between the 2 tumors is found to be over 5 cm, and 60-89% of cases had tumors in the same or adjacent surgical segment.[1,3,5] In our study, approximately 80% of cases, the distance between the 2 tumor sites was 5 cm and/or more. Preoperative detection of the lesions may well change the planned surgery.[5,13,14,16] However, colonoscopy and double-contrast barium enema do not seem to be enough to detect all the synchronous lesions.[8] Some suggest that palpation of the whole colon and rectum intraoperatively is extremely important.[8,13] In our series, the carcinomas were also frequently located outside the segment of the bowel that was resected in order to remove the apparent primary cancer. We believe that the surgeon should be aware of the significant possibility that his patient may have more than one simultaneously occurring serious neoplasm. Most of the SCRCs in our study were advanced cancers according to the Duke's classification. In 14 cases, the lesions were both stage B, or B and C. Neoplastic benign polyps are reported to be even more frequent in patients with SCRC.[2,4-8,13,14,16] The incidence of adenomatous polyps ranges from 12-62% of patients with a single CRC and from 40-75% of patients with SCRC.[1,2,4,6-8,16] In our study, 14 of 28 cases had coexisting adenomatous polyps (50%). The high frequency of benign polyps with single and/or multiple cancers further strengthens the concept that most, if not all, epithelial cancers of the large bowel arise from preexisting benign neoplastic polyps.[1,2,5,7,10,17] It is believed that the entire colorectal mucosa is unstable and has a high possibility for malignant change in patients with multiple primaries.[4] This, reported by many researchers, will provide accurate information concerning the presence of simultaneously occurring colorectal neoplasms.[13,16] In sporadic CRCs, the carcinogenesis is via the adenoma-carcinoma sequence, which involves the sequential accumulations of multiple mutations in oncogenes such as K-ras, and tumor suppressor genes including APC, p53 and deleted in colorectal carcinoma (DCC).[10,18] Mutation and deletion of the p53 gene is one of the most common alterations in human cancers. It was identified in up to 75% of colorectal carcinomas as well as in lung and breast cancer.[9,17] The mutant p53 gene, unlike the original, is not capable of suppressing tumoral growth. On the contrary, it further promotes tumoral growth and spread. Presence of mutant p53 is an accepted sign of aggressiveness and poor prognosis.[9,10,17] In our study statistically significant relationships between p53 expression and differentiation degree and the depth of invasion were found. This maybe interpreted as lower p53 expression was found in worse differentiated tumors, and higher p53 expression was found in deeper invading tumors. We were not able to reveal a statistically significant relationship between p53 expression and poor prognosis, although higher p53 seemed to be found in cases with worse prognosis. Synchronous tumors arising within a single organ may represent tumors of polyclonal or monoclonal origin, the latter indicating lateral spread from a single source, resulting in tumors with the same genetic alterations.[11,12,18] With the recent advances in molecular biology, it is possible to test the hypothesis of multicentricity at a genetic level.[11] In our study, we used immunohistochemical techniques to define the mutation pattern of p53 in multiple lesions of SCRC. Forty of 62 colorectal carcinomas showed immunohistochemical positivity for p53. However, 6 cases showed a discordant pattern of p53 mutation among individual lesions indicating polyclonal origin. Our results suggest that SCRC may be of polyclonal rather than monoclonal origin.

Synchronous colon and rectum adenocarcinoma is not rare. The incidence was as 3.6 % in our series. We believe that further studies with larger series are needed for p53 to prove useful in predicting prognosis of SCRCs and assessing the polyclonal origin of SCRC at a genetic level.

References

1. Lasser A. Synchronous primary adenocarcinomas of the colon and rectum. ***Dis Colon Rectum*** 1978; 21: 20-22.
2. Langevin JM, Nivatvongs S. The True Incidence of Synchronous Cancer of the Large Bowel. ***Am J Surg*** 1984; 147: 330-333.
3. Arai T, Sawabe M, Takubo K, Kanazawa K, Esaki Y. Multiple colorectal cancers in the elderly: a retrospective study of both surgical and autopsy cases. ***J Gastroenterol*** 2001; 36: 748-752.
4. Papadopoulos V, Michalopoulos A, Basdanis G, Papapolychroniadis K, Paramythiotis D, Fotiadis P, et al. Synchronous and metachronous colorectal carcinoma. ***Tech Coloproctol*** 2004; 8 Suppl 1: s97-s100.
5. Piñol V, Andreu M, Castells A, Payá A, Bessa X, Jover R, et al. Synchronous colorectal neoplasms in patients with colorectal cancer: predisposing individual and familial factors. ***Dis Colon Rectum*** 2004; 47: 1192-1200. Epub 2004 May 28.
6. Welch JP. Multiple Colorectal Tumors An Appraisal of Natural History and Therapeutic Options. ***Am J Surg*** 1981; 142: 274-280.

7. Avots-Avotins K. Multifocal Carcinoma of the Colon. ***Surg Clin North Am*** 1986; 66: 793-800.
8. Nikoloudis N, Saliangas K, Economou A, Andreadis E, Siminou S, Manna I, et al. Synchronous colorectal cancer. ***Tech Coloproctol*** 2004; 8 Suppl 1: s177-s179.
9. Rashid A, Houlihan PS, Booker S, Petersen GM, Giardiello FM, Hamilton SR. Phenotypic and molecular characteristics of hyperplastic polyposis. ***Gastroenterology*** 2000; 119: 323-332.
10. Liang JT, Chang KJ, Chen JC, Lee CC, Cheng YM, Hsu HC, et al. Clinicopathologic and carcinogenetic appraisal of DNA replication error in sporadic T3N0M0 stage colorectal cancer after curative resection. ***Hepatogastroenterology*** 1999; 46: 883-890.
11. Kang GH, Kim CJ, Kim WH, Kang YK, Kim HO, Kim YI. Genetic evidence for the multicentric origin of synchronous multiple gastric carcinoma. ***Lab Invest*** 1997; 76: 407-417.
12. Eguchi K, Yao T, Konomoto T, Hayashi K, Fujishima M, Tsuneyoshi M. Discordance of p53 mutations of synchronous colorectal carcinomas. ***Mod Pathol*** 2000; 13: 131-139.
13. Pagana TJ, Ledesma EJ, Mittelman A, Nava HR. The Use of Colonoscopy in the Study of Synchronous Colorectal Neoplasms. ***Cancer*** 1984; 53: 356-359.
14. Filograna MA, Ugenti I, Lattarulo S, Pezzolla A, Ferrarese F, Fabiano G. Large Bowel Multiple Tumours. ***Chir Ital*** 2007; 59: 207-216.
15. Devitt JE, Roth-Moyo LA, Brown FN: The Significance of Multiple Adenocarcinomas of the Colon and Rectum. ***Ann Surg*** 1969; 169: 364-367.
16. Kim MS, Park YJ. Detection and Treatment of Synchronous Lesions in Colorectal Cancer: The Clinical implication of Perioperative Colonoscopy. ***World J Gastroenterol*** 2007; 13: 4108-4111.
17. Sedivy R, Wolf B, Kalipciyan M, Steger GG, Karner-Hanusch J, Mader RM. Genetic analysis of multiple synchronous lesions of the colon adenoma-carcinoma sequence. ***Br J Cancer*** 2000; 82: 1276-1282.
18. Darmon E, Cleary KR, Wargovich MJ. Immunohistochemical Analysis of p53 Overexpression in Human Colonic Tumors. ***Cancer Detect Prev*** 1994; 18: 187-195.

Authorship Entitlement

Excerpts from the Uniform Requirements for
Manuscripts Submitted to Biomedical Journals
updated November 2003.
Available from www.icmje.org

The international Committee of Medical Journal Editors has recommended the following criteria for authorship; these criteria are still appropriate for those journals that distinguish authors from other contributors.

Authorship credit should be based on 1) substantial contributions to conception and design, or acquisition of data, or analysis and interpretation of data; 2) intellectual content; and 3) final approval of the version to be published. Authors should meet conditions 1, 2, and 3.

Acquisition of funding, collection of data, or general supervision of the research group, alone, does not justify authorship.

Author should be prepared to explain the order in which authors are listed.