

Oval window perilymph fistula caused by accidental stapedectomy during ear toilet

Sami E. Alharethy, MBBS, KSUF

ABSTRACT

على الرغم من المخاطر الكبيرة لتعرض المصاب لضعف سمع حسي عصبي مزمن في حالات ناسور النافذة البيضوية. في هذه الحالة بقي الناسور لمدة ستة أسابيع قبل عملية الترقيع ورغم ذلك تحسن وضع السمع بعد العملية. ننشر هنا حالة نادرة نتجت عن الاستئصال الخاطئ لعظمة الركاب أثناء عملية تنظيف الأذن. عانى المريض من ضعف سمع عصبي حسي، ودوار، وطنين. تحسنت جميعها بعد عملية إصلاح الناسور.

Acquired perilymphatic fistulae can be the result of direct or indirect trauma to the temporal bone, barotraumas, infections or a complication of stapedectomy surgery. We report a case of accidental stapedectomy causing a perilymphatic fistula in an ear with inactive chronic noncholesteatomatous otitis media. This patient had an oval window perilymphatic fistula for 6 weeks prior to surgery without significant permanent sensorineural hearing loss.

Saudi Med J 2008; Vol. 29 (6): 910-912

From the Department of Otolaryngology, King Saud University and King Abdulaziz University Hospital, Riyadh, Kingdom of Saudi Arabia.

Received 2nd January 2008. Accepted 1st May 2008.

Address correspondence and reprint request to: Dr. Sami E. Alharethy, Department of Otolaryngology, King Saud University and King Abdulaziz University Hospital, Riyadh, Kingdom of Saudi Arabia. Tel. +966 (1) 4786100. Fax. +966 (1) 4775791. E-mail: harthi2000@hotmail.com

Direct trauma to the middle ear and ossicles can happen with ear suction and inadvertent use of instruments to clean the ear. We report a case of iatrogenic stapedectomy, which occurred during ear toilet. Although there is a fear of having a permanent sensorineural hearing loss in cases of perilymphatic fistula and chronic suppurative otitis media, this patient had the surgical repair of the fistula 6 weeks following the accident and had no significant permanent sensorineural hearing loss.

Case Report. A 55-year-old gentleman who had a long history of bilateral hearing loss, left intermittent ear discharge, and occasional bilateral tinnitus was seen in a private hospital by an ear, nose and throat (ENT) surgeon. He was complaining of left ear continuous tinnitus for one week, not associated with ear discharge, change in hearing, or vertigo. After left ear suction and ear instrumentation he immediately heard a sudden loud sound (such as someone screaming suddenly in his ear). The tinnitus became louder, with deterioration of hearing. After 3 hours he developed severe vertigo and disequilibrium, associated with nausea, and vomiting. He was managed with antibiotics and vasodilators. The severe vertigo lasted for 3 days. Over 6 weeks the severity of vertigo nausea and vomiting decreased, and attacks of vertigo during head movement accompanied by severe disequilibrium (he could drive his car, could go to his work, and could walk without an assistant), left severe tinnitus and non progressive left ear hearing loss with no ear discharge continued. He visited many ENT doctors, and antibiotics, vasodilators, and steroids were given but without any improvement. The patient was referred to our hospital for further management. On examination, he was found to have severe unsteadiness (on a wheelchair) with no nystagmus. Otoscopic examination showed a dry left subtotal perforation with the complete absence of the stapes, but no perilymph leakage was obvious at the oval window region (Figure 1). Fistula test using the pneumatic otoscope was negative and facial nerve function was normal. Pure tone audiogram showed left mixed hearing loss. Air bone gap (ABG) average at 500, 1000, 2000, and 4000 Kilo Hertz (Hz) was 26.25 decibels (dB) with bone conduction dip of 35 dB at 2000 Kilo Hertz (Hz) (Figure 2). He was diagnosed as left ear iatrogenic stapedectomy with perilymphatic fistula in an ear with inactive chronic suppurative otitis media. He was admitted and instructed for bed rest, head elevation, limited activity with no straining or heavy lifting and was started on intravenous cefuroxime.

He was then taken to the operating room and middle ear exploration through a post auricular incision

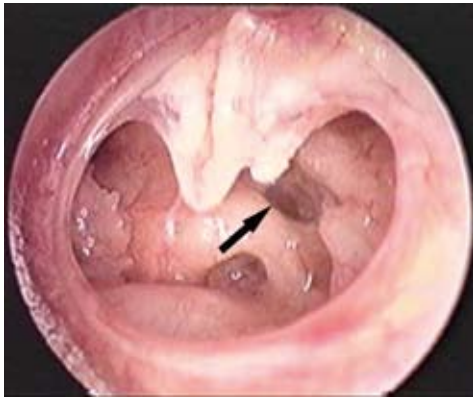


Figure 1 - Left ear endoscopic examination showing a subtotal perforation with complete absence of the stapes.

revealed an absent stapes and a perilymphatic leakage were found around the oval window with a fractured lenticular process of incus and mobile incudomalleolar joint. The tympanic membrane was repaired with underlay temporalis fascia graft, and the oval window was sealed with temporalis fascia graft. The ossicular chain was reconstructed as in classical stapedectomy with 4.5 mm Teflon loop prosthesis between the oval window graft and the remnant of the long process of incus. On the second day after surgery, he experienced a dramatic improvement in unsteadiness and was able to walk without assistance. Two months after surgery he was still having mild vertigo on head movement with no unsteadiness or tinnitus. Otoloscopic examination showed intact tympanic membrane. The pure tone audiogram average at 500, 1000, 2000, and 4000 kHz showed improvement of bone conduction and an ABG of 17.5 dB (Figure 3).

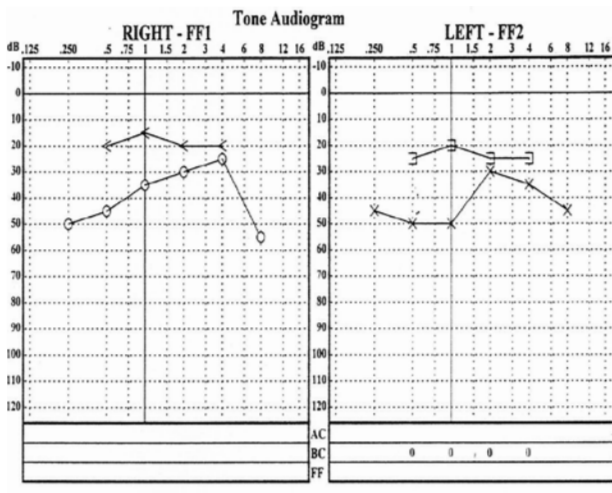


Figure 3 - Postoperative pure tone audiogram.

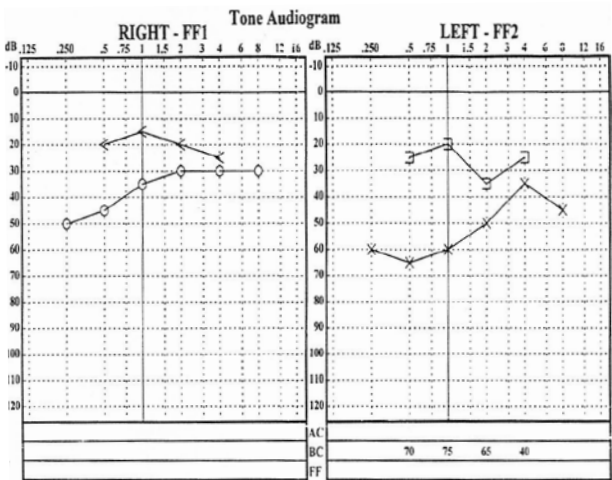


Figure 2 - Preoperative pure tone audiogram.

Discussion. Acquired perilymphatic fistulae can be the result of direct or indirect trauma to the temporal bone, barotrauma, infections or a complication of stapedectomy surgery.¹⁻³ Perilymphatic fistula should be suspected if there is a history of sudden vestibular symptoms following middle ear trauma.⁴ Whether to operate or not and when to operate in patients with suspected perilymphatic fistula is still a controversial issue.⁵ Kojima et al⁴ concluded that when vertigo and hearing loss are present immediately after trauma, the causal relationship is obvious and early surgical intervention should be carried out. In this report case there was an obvious cause with a clear fistula at the oval window site, for which the decision was to perform an immediate surgery. Silverstain et al⁵ recommended exploration of the middle ear within 24 hours of injury to avoid a possible severe permanent sensorineural hearing loss. Surprisingly in this ear with chronic suppurative otitis media, the vestibule was exposed for a period of 6 weeks without any permanent sensorineural hearing loss. In a retrospective study of traumatic tympanic membrane perforations, Griffen⁶ advised early exploration in cases with severe vertigo. Halvey et al⁷ concluded that in all patients with sudden vestibular and/or acoustic symptoms, they must be considered to have a perilymphatic fistula until proven otherwise by surgery. However, when the causal relationship between trauma and vertigo and/or hearing loss is suspected, some surgeons would wait for conservative management for approximately 2 weeks before surgical intervention.^{8,9} Although surgical repair of perilymphatic fistula is more effective in improving the vestibular symptoms, the prognosis for hearing is not always as good.⁹⁻¹² Following surgery our patient had a dramatic improvement of the vestibular symptoms and his hearing had some improvement.

Acknowledgment. *The author thanks Professor Yousry Elsayed and Dr. Munahi Al-Qabtani for critical review of the manuscript.*

References

1. Goodhill V. Sudden deafness and round window rupture. *Laryngoscope* 1971; 81: 1462-1474.
2. Healy GB, Friedman JM, Strong MS. Vestibular and auditory findings of perilymph fistula: A review of 40 cases. *Trans Am Acad Ophthalmol Otolaryngol* 1976; 82: 44-49.
3. Goodhill V. Sudden deafness and labyrinthine window rupture. *Ann Otol Rhinol Laryngol* 1973; 82: 2-12.
4. Kojima H, Tanaka Y, Mori E, Uchimizu H, Moriyama H. Penetrating vestibular injury due to a twig entering via the external auditory meatus. *Am J Otolaryngol* 2006; 27: 418-421.
5. Silverstain H. penetrating wounds of the tympanic membrane and ossicular chain. *Trans Am Acad Ophthalmol Otolaryngol* 1973; 7: 1125-1135.
6. Griffen WL. A retrospective study of traumatic tympanic perforation in a clinical practice. *Laryngoscope* 1979; 89: 261-282.
7. Halvey A, Sade J. The perilymphatic fistula. *Am J Otol* 1983; 5: 109-112.
8. Vanderstock L, Vermeersch H, De Vel E. Traumatic luxation of the stapes. *J Laryngol Otol* 1983; 97: 533-537.
9. Dudley J, Glenn D. Perilymphatic fistula: A New Hampshire Experience. *Am J Otol* 1988; 9: 184-196.
10. Grundfast KM, Bluestone CD. Sudden or fluctuating hearing loss and vertigo in children due to perilymph fistula. *Ann Otol Rhinol Laryngol* 1978; 87: 761-771.
11. Seltzer S, McCabe BF. Perilymph fistula: the Iowa experience. *Laryngoscope* 1986; 96: 37-49.
12. Singleton GT. Diagnosis and treatment of perilymph fistula without hearing loss. *Otolaryngol Head Neck Surg* 1986; 94: 426-429.

Illustrations, Figures, Photographs

Four copies of all figures or photographs should be included with the submitted manuscript. Figures submitted electronically should be in JPEG or TIFF format with a 300 dpi minimum resolution and in grayscale or CMYK (not RGB). Printed submissions should be on high-contrast glossy paper, and must be unmounted and untrimmed, with a preferred size between 4 x 5 inches and 5 x 7 inches (10 x 13 cm and 13 x 18 cm). The figure number, name of first author and an arrow indicating "top" should be typed on a gummed label and affixed to the back of each illustration. If arrows are used these should appear in a different color to the background color. Titles and detailed explanations belong in the legends, which should be submitted on a separate sheet, and not on the illustrations themselves. Written informed consent for publication must accompany any photograph in which the subject can be identified. Written copyright permission, from the publishers, must accompany any illustration that has been previously published. Photographs will be accepted at the discretion of the Editorial Board.