Uncommon locations of hydatid cyst

Nebil Bal, MD, Nazım E. Kocer, MD, Rabia Arpaci, MD, Ali Ezer, MD, Fazilet Kayaselcuk, MD.

ABSTRACT

الأهداف: من أجل توثيق الإصابة بالكيس المائي في منطقة كوكوروفا المستوطنة في تركيا، نتيجة لمواقع الإصابة لديهم في الجسم، ومناقشة الملامح السريرية والشكلية للحالات مع مواضع الإصابة النادرة.

الطريقة: أجريت دراسة على 153 حالة تم تشخيصها بالإصابة بالكيس المائي في مركزين طبيين مختلفين بمنطقة أدانا (منطقة كوكوروفا) – تركيا، في الفترة ما بين عام 2000م وحتى 2006م. تمت إعادة تقييم الحالات ذات المواضع النادرة على ضوء النتائج السريرية والمخبرية، والملامح النسيجية المرضية. تم توثيق مواضع الإصابة لهذه الحالات وتمت مناقشة الحالات ذات المواضع النادرة.

النتائج: كانت الكبد أكثر المناطق إصابة بواقع 63 حالة، تلتها الرئتين بواقع 54 حالة. من المواضع غير الشائعة الطحال (عدد=4)، والعظام (عدد= 1)، والمبيض (عدد=1)، والغدة الكظرية (عدد=1)، والقلب (عدد=1)، والمساريق (عدد=2)، وخلف الصفاق (عدد=2)، والنسيج تحت الجلد (عدد=4)، والثدي (عدد=3)، والنسيج داخل العضلة (عدد=4).

خاتمة: يجب أخذ تشخيص الكيس المائي بعين الاعتبار لدى المرضى المصابين بكتلة كيسية، والذين يعيشون أو كانوا يعيشون في منطقة جغرافية ذات خطورة عالية من داء الكيسات العدارية أو الذين قد زاروا منطقة مستوطنة.

Objective: To document the hydatid cyst cases in the endemic Çukurova region of Turkey, by their involvement sites in the body, and discuss the clinical and morphological features of the cases with rare localization.

Methods: Archival materials of 153 hydatid cyst cases that were diagnosed in 2 different medical centers in Adana, Turkey (Çukurova region) between the years 2000-2006 were included in the study. Cases with rare localizations were reevaluated in terms of clinical and laboratory findings, and histopathological features. Involvement sites of the cases were documented, and cases with rare localizations are discussed.

Results: The liver was the most common localization with 63 cases followed by lungs with 54 cases. Uncommon locations were spleen (n=4), bone (n=3), intraarterial (n=1), ovary (n=1), adrenal (n=1), heart (n=1), mesenteric (n=2), retroperitoneal (n=2), subcutaneous tissue (n=4), breast (n=3), intramuscular tissue (n=4).

Conclusion: The diagnosis of hydatic cyst should be considered in patients with a cystic mass, who live or have lived in a geographic region that has a high risk for *Echinococcus granulosus,* or visited an endemic area.

Saudi Med J 2008; Vol. 29 (7): 1004-1008

From the Departments of Pathology (Bal, Kocer, Kayaselcuk), and General Surgery (Ezer), Baskent University Faculty of Medicine, Ankara, and the Pathologist (Arpaci), Tuncer Pathology Laboratory, Adana, Turkey.

Received 16th February 2008. Accepted 11th June 2008.

Address correspondence and reprint request to: Dr. Nebil Bal, Başkent Universitesi Tip Fakultesi Adana Arastirma ve Uygulama Merkezi Patoloji Bolumu, Yuregir 01250, Adana, Turkey. Tel. +90 (322) 3272727. Fax. +90 (322)3271276. E-mail: nebilbal@yahoo.com

Hydatid cyst is a common, and important public health problem with social aspects.[1] The most common cause is *Echinococcus granulosus*.[1-10] Humans acquire the disease by ingesting food which is contaminated by the feces of domestic animals, especially in endemic regions.[3,7,10] There are 4 known types of *Echinococcus*: *E. granulosus, E.multilocularis, E. oligarthus,* and *E. vogeli.* Humans are sensitive to the eggs of all of these 4 types. There is a regional distribution; in Asia *E. granulosus* and *E. multilocularis* are the widespread causes of the disease, while *E. oligarthrus* and *E. vogeli* are limited to Central and South America.[11] *Echinococcus* parasites need main and intermediate hosts to complete their life cycle. Main hosts are carnivores such as dogs, wolves, and foxes, while intermediate hosts are animals like sheep, goats, horse, and sometimes humans. Infection is caused by close contact with the infected animal itself or ingestion of a food that is contaminated with the animal's feces.[3]

The adult form of *E. granulosus* lives in the bowel of the main host and the eggs, which are responsible from the transportation of the parasite to the intermediate host, spread into the environment with the feces of the animal. Eggs, taken by the intermediate host, open in the small bowel and the released oncospheres penetrate the portal circulation. The most common sites of infection, caused by *E. granulosus*, are liver (50-70%) and lungs (20-30%).[2,4,7,10] Although rare, soft tissue, spleen, pancreas, heart, striated muscle, brain, pericardia, breast, thyroid, adrenal, ovary, bone, and subcutaneous tissue involvement have been reported.[1-17] Imaging techniques,[1,2,8,17] and serology,[2,6,7,8,17] may be used for diagnosis. Fine needle aspiration biopsy (FNAB) and histopathologic examination of the resected cysts are also important for the diagnosis.[7,17] The primary choice of treatment is surgery, particularly in parenchymal organ involvement.[1-17] Radiological imaging procedures and some serologic tests are helpful in diagnosis and in differential diagnosis.[1,2,7,8] The FNAB may be performed to confirm the diagnosis before surgical operation. Since FNAB of hydatid cyst carries the risk of anaphylaxis due to the leakage of cyst fluid into the peripheral tissue and pleural or peritoneal cavity, antiparasitic treatment prior to the FNAB is recommended.[16] The presence of cuticular membrane, scolex or hooklets is of diagnostic importance in the examination of FNABs. The primary choice of treatment is surgical.[2,6,10] Pre or postoperative medical treatment may be helpful to prevent the spread or recurrence of the disease. Immunoglobulin E (IgE) titers are high in the patients with hydatid cyst, and the IgE levels usually decrease to the normal range one or 2 years after the surgery. Increase in the IgE levels is the indicator of recurrence.[2] This retrospective study evaluates the localization of the hydatid cysts that were diagnosed in 2 different medical centers in Adana, Turkey (largest city in the Cukurova region), an endemic region for hydatid cyst, and discusses the possible ways of involvement in atypically located cases and emphasizes the clinical presentations of these unusual localizations, that may be critical for a correct and prompt diagnosis.

Methods. Archival materials of 153 hydatid cyst cases that were diagnosed in 2 different medical centers in Adana between the years 2000-2006 were included in the study. Data were obtained in a retrospective manner. All archival slides belonging to the cases that were included in the study were reexamined by 2 pathologists. Each case was reevaluated with patient history, radiologic imaging procedure results obtained from the files of the patients, and histopathological findings from the reevaluated archival slides. Involvement sites of the cases were documented, and cases with rare localizations are discussed. Ethical Committee approval for the retrospective studies namely archival materials of pathologic specimens, is not sought to in our university.

Results. Localizations of the hydatid cyst cases that were included in the study, are shown in **Table 1**. The most common site of involvement was the liver with 63 cases of solitary cysts, and a case with synchronous pelvic soft tissue and liver involvement. Lung is the second most common site of involvement with 53 cases and a case with concurrent lung, breast, and inguinal subcutaneous cysts. Subcutaneous soft tissue, spleen, striated muscle, breast, thorax, kidney, bone, retroperitonea, mesentery, posterior mediastinum, uterus serosal aspect, perirenal tissue, adrenal, renal artery, heart, and ovaries were the rare localizations in our serial. Cases with rare localizations are discussed with their specific clinical and radiological aspects.

Table 1 - The distribution of 153 hydatid cyst.

Localization	Cases	(%)
Liver	63	(41.2)
Lung	54	(35.4)
Subcutaneous soft tissue	4	(2.6)
Spleen	4	(2.6)
Striated muscle	4	(2.6)
Breast	3	(1.95)
Thorax wall	3	(1.95)
Kidney	3	(1.95)
Bone	3	(1.95)
Retroperiton	2	(1.3)
Mesenter	2	(1.3)
Posterior mediastinum	1	(0.65)
Uterus serosal aspect	1	(0.65)
Perirenal	1	(0.65)
Adrenal	1	(0.65)
Renal artery thrombus and heart	1	(0.65)
Ovary	1	(0.65)
Pelvic soft tissue and liver	1	(0.65)
Inguinal subcutaneous tissue, lung and breast	1	(0.65)
Total	**153**	**(100)**

Discussion. Hydatid cyst is a parasitic disease caused by *E. granulosus.* The disease is common in endemic regions such as the Middle East, Mediterranean Coast, New Zealand, Australia, and South America, and is an important public health problem with economical and social aspects.[1,5] Although liver and lung involvements

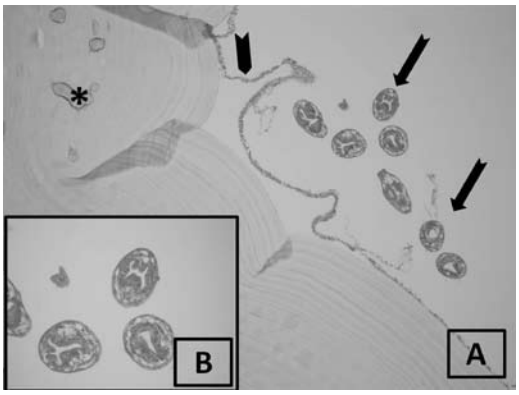

Figure 1 - A) Cuticular membrane (*) that is lined by a compressed germinal epithelium (arrow head), and numerous daughter vesicles (Arrow) (Hematoxylin and eosine x 200) **B**) Daughter vesicles (Hematoxylin and eosine x 400)

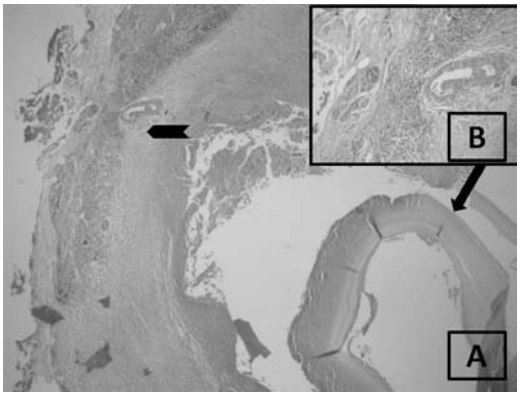

Figure 2 - A) Cuticular membrane of hydatid cyst in breast (Arrow) and breast tissue (arrow head) (Hematoxylin and eosine x 40). **B**) Normal breast tissue (Hematoxylin and eosine x 200).

are the most common, spleen, heart, pericardia, central nervous system, pancreas, bile tract, breasts, kidneys, bones, thyroid, striated muscles, and soft tissue may also be involved.[1-10] These unusual primary sites of involvement may be explained by the oncospheres by-passing the liver and lungs through precapillary anastomosis between pre and post parenchymal circulation.[8] Ultrasonography (USG), computerized tomography (CT), and magnetic resonance imaging (MRI) are helpful in the diagnosis.[1,2,8] Enzyme linked immunosorbent assay (ELISA), western-blot, hemaglutination, complement fixation, and direct fluorescence are the serologic tests that can be used in the diagnosis of hydatid cyst.[2,7,8] Sensitivity of serologic tests is between 64-87%.[2] The ELISA and western-blot have 80-100% sensitivity and 88-96% specifity.[2] Sensitivity decreases to 50-56% in lung hydatid cysts, and to 25-26% in unusual sites.[2] Although non-specific, Casoni skin test,[2,6,8] IgE titers, and peripheral eosinophilia may be used as diagnostic tests.

In the histopathologic examination, newly formed cysts are composed of a pink lamellar cuticular membrane that is lined by a compressed germinal epithelium, and may contain numerous daughter vesicles (**Figure 1**). Older cysts may be surrounded by a capsule that is composed of granulation tissue, fibrosis, and an inflammatory reaction rich in eosinophil polymorphs. Calcification may be seen in the wall of the cysts, which are no more viable.[2] Primary striated muscle involvement is rare with 3%,[2] and may occur due to direct seeding of the oncospheres or secondarily via blood circulation.[8] Thorax wall, pectoralis major, sartorius and biceps brachii are the most common sites of muscle involvement. Soft tissue seated hydatid cysts are also extremely rare.[2] Four of the 6 subcutaneous hydatid cysts in our serial were primary involvements. No other site of involvement was detected in the brain, thorax, and abdomen CTs in these 4 cases. One of the remaining 2 cases had synchronous liver, and the other had synchronous lung involvement. There were 4 (3 quadriceps, one pectoralis major) hydatid cysts with primary striated muscle localization in our study. No other cystic lesion was observed during the radiologic scanning (MRI and CT) of these patients.

Breast involvement is even rarer than the striated muscle and soft tissue involvement and comprises 0.27-0.37% of the all hydatid cyst cases. There is a female predominance. The disease can be seen at any age, but the peak is between third and fifth decades. Patients are admitted to the hospital with a palpable mass in the breast, existing for a long time. The lesion appears in mammography as a calcified mass. The differential diagnosis is between calcified fibroadenoma, simple cyst, and well-demarcated carcinomas.[4] Yüksel et al,[4] reported a breast hydatid cyst with high serum levels of carbohydrate antigen 19-9 (Ca19-9) (case level: 41 kU/L, normal: 0.0-39.0kU/L). Hydatid cyst should be considered in the differential diagnosis in cases with high Ca19-9 levels in endemic regions.[4] In our serial, all hydatid cysts in the breast had a periareolar location (**Figure 2**). In the follow up of one of these cases, an inguinal subcutaneous hydatid cyst and a lung hydatid cyst were detected 2 years after the detection of the breast primary. Atypically located hydatid cyst's appearing 2 years before the typical one was interesting in this case.

Another rare localization is heart (0.5-2%).[1,3,14] It is believed that the parasite reaches the heart via coronary arteries.[1] Patients may either remain asymptomatic for a long period or manifest with ischemic symptoms, anaphylactic shock, systemic or pulmonary emboli, coronary artery compression, conduction disturbance, cardiac tamponade, or cardiac valve problems.[3] Involvement sites of hydatid cyst in the heart are as follows: Left ventricle (50-60%), interventricular septum (10-20%), right ventricle (5-15%), pericardium

(5-8%), right and left atrium (5-8%).[3] Myxoma, fibroma, hamartoma, rhabdomyoma, and although rare, sarcomas should be considered in the differential diagnosis.[1] Rupture of cardiac cysts may cause symptoms of systemic or pulmonary emboli.[14] Our case was a 25 year-old female, who had a previous left leg amputation under the knee due to peripheric artery disease. Diagnostic procedures used to enlighten the cause of the arterial occlusive disease were not helpful. Two months after the amputation, the patient was operated with the diagnosis of right femoral and renal artery embolus. Histopathological examination of the embolectomy materials revealed cuticular membrane fragments of hydatid cyst. Radiological imaging procedures showed multiple cysts located at the ventricular apex. Lesions were excised, and the histopathological diagnosis was hydatid cyst. This primary cardiac hydatid cyst case, presenting as a peripheric artery disease is interesting. Hydatid cyst should always be considered in the differential diagnosis in acute artery occlusions in young patients, especially in endemic regions. Histopathological examination of the embolectomy material is also very important. The correct and prompt diagnosis of underlying cause is essential for preventing further complications. The spleen is one of the most common sites of involvement after liver and lungs, and its incidence within intraabdominal hydatid cysts is 0.5-4%.[5] Symptoms may be due to compression of adjacent structures such as hypertension due to compression of renal artery or due to the rupture of the cyst.[5] In our series, there were 4 hydatid cyst cases located in the spleen, and this location was sharing the third line with soft tissue and striated muscle locations in frequency ranking, after the liver and lungs. The overall incidence of bone involvement is 0.5-4%.[10] Vertebras are the most common localizations with 50%. Pelvic bones, femur, tibia, fibula, ribs, scapulae, clavicula, and tarsal bones may also be involved. Bone hydatid cysts tend to grow slower than hydatid cysts located at the other sites. Pathologic fractures may occur secondary to compression, ischemia, or osteoclastic proliferation. One of our cases was a male patient who had a previous surgery with the diagnosis of meniscus laceration. The diagnosis was determined by CT scanning. The pain did not resolve, and the patient was admitted to our hospital and a CT was performed. The CT revealed a well-demarcated cystic mass at the proximal part of the right tibia. One of our remaining 2 bone hydatid cysts was located at proximal part of right femur, and the other was located at corpus humerii. The incidence of renal involvement is 4%. Most of the cases are asymptomatic and incidentally found during radiological scanning performed for other reasons. Hydatiduria may be seen in 22% of cases. Presence of daughter vesicles in the ureter may cause renal colic and in that case grape like structures may be seen in the urine. The superior pole of the kidney is the most common localization with 37%. Ninety-two percent of the cases are unifocal, 6% are multifocal, and 2% are bilateral.[6] In our serial, 2 cases were multifocal, and one case was unifocal. No other cystic lesion was found in any other part of the body.

Adrenal hydatid cyst cases comprise 0.5% of all hydatid cyst cases. Although rare, this localization is important, as most of these lesions are clinically diagnosed as solitary adrenal tumors.[13] In our adrenal hydatid cyst case, the first lesion was detected in the patient was a cyst located peripherally in the right lobe sixth segment of the liver. The lesion was a 5x6 cm calcified cyst, radiologically compatible with inactive, stage V, cyst hydatid. Following the detection of the hydatid cyst in the liver, a systemic scan was performed and a well demarcated, 5.6 cm in diameter, cystic mass with solid component, in the right adrenal was revealed with USG. No other lesion resembling hydatid cyst was found during the systemic scan. In gross examination of the excised adrenal tissue, intracystic hemorrhage, and a solid mass of fibrin were observed. Since both cysts were detected nearly synchronously, a further comment about the primer site of involvement could be made. Metanephrine, normetanephrine, and vanilmandelic acid levels were in normal ranges. The lesion, excised with adrenal, was found to be cystic during the macroscopic sampling, and microscopical examination revealed that the lesion is a hydatid cyst. Ovarian hydatid cysts are extremely rare and usually remain silent for a long time. Their incidence is 0.2-0.9%.[15] Our case was a 36 year-old patient who had undergone left salpingo-oophorectomy due to a cystic mass in the left ovary. No other cystic lesion was found in abdomen. The brain and thyroid are other unusual locations of hydatid cyst.[7,12] However, there were no patients with those locations in our group.

In our serial, all of the hydatid cysts with rare localizations were without synchronous liver and lung involvements, except 2 cases. A systemic scan in all hydatid cyst cases, including the ones with atypical localizations, is important for the exact treatment of the disease, and to prevent the recurrences. Complications of hydatid cyst may cause organ loses or may even be life threatening.

References

1. Thameur H, Abdelmoula S, Chenik S, Bey M, Ziadi M, Mestiri T, et al. Cardiopericardial hydatid cysts. ***World J Surg*** 2001; 25: 58-67.
2. Orhan Z, Kara H, Tuzuner T, Sencan I, Alper M. Primary subcutaneous cyst hydatic disease in proximal thigh: an unusual localisation: a case report. ***BMC Musculoskelet Disord*** 2003; 4: 25.
3. Savas L, Onlen Y, Akcali C, Aslan B, Pourbagher A, Tunc T, et al. Hydatid disease with atypical localization: 4 cases report. ***Scand J Infect Dis*** 2004; 36: 613-615.

4. Yuksel BC, Ozel H, Akin T, Avsar FM, Hengirmen S. Primary hydatid cyst of the breast with elevated CA 19-9 level. ***Am J Trop Med Hyg*** 2005; 73: 368-370.
5. Celebi S, Basaranoglu M, Karaaslan H, Demir A. A splenic hydatid cyst case presented with lumbar pain. ***Intern Med*** 2006; 45: 1023-1024.
6. Zmerli S, Ayed M, Horchani A, Chami I, El Ouakdi M, Ben Slama MR. Hydatid cyst of the kidney: diagnosis and treatment. ***World J Surg*** 2001; 25: 68-74.
7. Erkilic S, Ozsarac C, Kocer NE, Bayazit YA. Hydatid cyst of the thyroid gland in a child. ***Int J Pediatr Otorhinolaryngol*** 2004; 68: 369-371.
8. Haque F, Harris SH, Khan R, Abbas SZ. Primary hydatidosis of gluteus maximus. ***J Postgrad Med*** 2006; 52: 300-301.
9. Cebollero MP, Cordoba E, Escartin J, Cantin S, Artigas JM, Esarte JM. Hydatic cyst of spleen. ***J Clin Gastroenterol*** 2001; 33: 89-90.
10. Mattern CJ, Gardner MJ, Grose A, Helfet DL. Case report: Echinococcus disease of the bone presenting as a femoral shaft nonunion. ***Clin Orthop Relat Res*** 2007; 458: 220-225.
11. Utuk AE, Simsek S, Koroglu E. (Molecular genetic characterization of genus Echinococcus.) ***Turkiye Parazitol Derg*** 2005; 29: 171-176.
12. Tuzun M, Altinors N, Arda IS, Hekimoglu B. Cerebral hydatid disease CT and MR findings. ***Clin Imaging*** 2002; 26: 353-357.
13. Mishra A, Ehtuish EF. Hydatid cyst-an unusual presentation. ***Saudi Med J*** 2006; 27: 892-893.
14. Nisanoglu V, Erdil N, Isik B, Battaloglu B, Alat I. Acute abdominal aorta embolism caused by rupture of a cardiac hydatid cyst. ***Ann Vasc Surg*** 2004; 18: 484-486.
15. Adewunmi OA, Basilingappa HM. Primary ovarian hydatid disease in the Kingdom of Saudi Arabia. ***Saudi Med J*** 2004; 25: 1697-700.
16. Niscigorska J, Sluzar T, Marczewska M, Karpinska E, Boron-Kaczmarska A, Moranska I, et al. Parasitic cysts of the liver-practical approach to diagnosis and differentiation. ***Med Sci Monit*** 2001; 7: 737-741.
17. Kiresi DA, Karabacakoglu A, Odev K, Karakose S. Uncommon locations of hydatid cysts. ***Acta Radiol*** 2003; 44: 622-636.

References

* References should be primary source and numbered in the order in which they appear in the text. At the end of the article the full list of references should follow the Vancouver style.

* Unpublished data and personal communications should be cited only in the text, not as a formal reference.

* The author is responsible for the accuracy and completeness of references and for their correct textual citation.

* When a citation is referred to in the text by name, the accompanying reference must be from the original source.

* Upon acceptance of a paper all authors must be able to provide the full paper for each reference cited upon request at any time up to publication.

* Only 1-2 up to date references should be used for each particular point in the text.

Sample references are available from:
http://www.nlm.nih.gov/bsd/uniform_requirements.html