

Over expression of vascular endothelial growth factor in correlation to Ki-67, grade, and stage of breast cancer

Esraah S. Al-Harris, MBChB, MSc, As'ad A. Al-Janabi, MSc, PhD (Path),
Kaswer M. Al-Toriahi, MBChB, FICMS (Path), Akeel A. Yasseen, MSc (UK), PhD (UK).

ABSTRACT

الأهداف: من أجل تقييم مغزى التعبير المفرط لعامل نمو البطانة الوعائية (VEGF) في سرطان الثدي عند الإنسان، واحتمالية ترابطة مع التعبير النسيجي المناعي لعامل التكاثر (Ki-67)، ودرجة التمايز، ومرحلة الانتشار.

الطريقة: اجريت هذه الدراسة في قسم علم الأمراض - جامعة الكوفة - العراق، خلال الفترة مابين نوفمبر 2006م وحتى سبتمبر 2007م. تم الحصول على 52 عينة مثبتة بالفورمالين ومطمورة بالبارافين لنساء مصابات بسرطان الثدي. شملت الدراسة مجموعة مكونة من 21 سيدة مصابة بورم الثدي الحميد للمقارنة، كذلك استخدمت 40 عينة لنسيج الثدي الطبيعي كمجموعة قياسية. تم استخدام نظام (ABC) لتحديد التعبير المناعي النسيجي لكلاً من (VEGF) و (Ki-67).

النتائج: أظهرت النتائج أن التعبير النسيجي المناعي لـ (VEGF) كان موجبا في 61.5% من أورام الثدي الخبيثة، وفي 19% من أمراض الثدي الحميدة. لم نلاحظ أي تعبير نسيجي لـ (VEGF) في نسيج الثدي الطبيعي ($p < 0.005$). لم يوجد فرق في إظهار (VEGF) بين أنواع الأنسجة المختلفة من سرطان الثدي ($p > 0.05$). إن تردد إظهار (VEGF) وشدته، مرتبط بعلاقة معنوية ايجابية مع (Ki-67)، وحجم ومرحلة الورم، والعقد اللمفاوية. إن إظهار (VEGF) قد تبين أكثر تكرارا في سرطان الثدي الموجب عنه في السالب ($p > 0.05$). كما تبين إن ظهور (VEGF) مرتبط بعلاقة معنوية ايجابية مع حجم ومرحلة الورم ولكن غير مرتبط مع العمر.

خاتمة: أن عامل نمو البطانة الوعائية يلعب دور مهم في تولد سرطان خبيث الثدي، والدليل على ذلك، دوره في عملية تكوين الأوعية الدموية وحياة الخلية. ويمكن التوجيه بأن تعطيل عامل نمو البطانة الوعائية ربما يكون هدفاً لإعاقة عملية تكوين الأوعية الدموية وبالتالي يطور فعالية العلاج المضاد للسرطان.

Objective: To assess the significance of vascular endothelial growth factor (VEGF) protein over expression in human breast cancer, and its possible correlation with cell proliferation marker (Ki-67), grade and stage of breast cancer.

Methods: We carried out this study at the Department of Pathology, Kufa University, between November 2006 and September 2007. A retrospective study was employed on paraffin-embedded blocks from 52 female patients with breast cancer. A group of 21 patients with benign breast lesions was included for comparison and 14 cases of normal breast tissue as a control group. This investigation designed to employ immunohistochemistry using Avidin-Biotin Complex (ABC) method for detection of both VEGF and Ki-67.

Results: A total of 87 samples was included. Vascular endothelial growth factor immunoeexpression was considered as positive in 61.5% of malignant and in 19% of benign breast lesions. No over expression sign has been noticed in normal breast tissue ($p < 0.005$). No significant difference in VEGF over expression among different histological types of breast cancer ($p > 0.05$). Vascular endothelial growth factor immunostaining was positively correlated with Ki-67, grade, stage, lymph node metastasis, and recurrence of breast cancer ($p < 0.05$). No such correlation has been seen when the age of the patients has been considered.

Conclusion: Vascular endothelial growth factor Vascular endothelial growth factor plays an important role in pathogenesis of breast cancer evolution, and supports the evidence of its role in angiogenesis and cell survival. This study recommended that the blocking of VEGF may be a target for blocking angiogenesis and hence improving the efficacy of anti-cancer therapy.

Saudi Med J 2008; Vol. 29 (8): 1099-1104

From the Department of Pathology and Forensic Medicine, Faculty of Medicine, Kufa University, Kufa, Iraq.

Received 13th February 2008. Accepted 1st July 2008.

Address correspondence and reprint request to: Dr. Akeel Yasseen, Professor, Department of Pathology and Forensic Medicine, Faculty of Medicine, Kufa University, Kufa, PO Box 18, Iraq. Tel. +964 7801250748. Fax. +964 (333) 60328 E-mail: a.yasseen@hotmail.com

It is well established that breast cancer is still the most common malignancy among women all over the globe.¹ However this type of malignancy has been considered as an angiogenic-dependent disease in which angiogenesis is an important process in its development, invasion and metastasis.²⁻⁴ Indeed, breast cancer angiogenesis is attributed largely to the increase in the production of VEGF by the tumor cells and to the cells within the tumor stroma.⁵ Vascular endothelial growth factor is the most potent angiogenic cytokines⁶ and it is sometimes known as VEGF-A or VPF (vascular permeability factor). The vascular permeability factor⁷ is the best studied and understood member of VEGF ligand family.⁸⁻¹⁰ Vascular endothelial growth factor - A exists in at least 6 isoforms formed from alternative splicing of VEGF mRNA.^{10,11} Vascular endothelial growth factor exerts its effect through binding to 2 related receptor tyrosine kinase (RTKs); VEGFR-1 and VEGFR-2.¹² Furthermore, VEGF also interact with a family of RTKs act as co-receptor known as neuropilin one and neuropilin 2.¹³ It has long been shown that VEGF is a well recognized stimulus of angiogenesis in various types of solid tumors; including breast cancer.¹⁴ A large number of studies demonstrate the essential role of VEGF as a prognostic marker for the aggressiveness of breast cancer.¹⁵⁻¹⁷ Vascular endothelial growth factor expression and intensity were used as indicators of significant inferior outcome in patients with early breast cancer and with co expression of several biomarkers in breast cancer.¹⁸ The present study is designed to assess the significance of VEGF protein over expression in human breast cancer, and its possible correlation with Ki-67 (cell proliferation marker), grade, stage, and recurrence of breast cancer.

Methods. This study was conducted at the Department of Pathology and Forensic Medicine, Faculty of Medicine, Kufa University from November 2006 through September 2007. Fifty-two female patients with breast cancer (41 infiltrating ductal carcinoma [IDC], 3 infiltrating lobular carcinoma [ILC], 6 medullary carcinoma, one ductal carcinoma in situ (DCIS), and one inflammatory carcinoma), were enrolled in this study. Soft tissue tumors were excluded as they did not fulfill the criteria or comply with our aim. All specimens were collected from the major hospitals and some of the private clinical laboratories in Najaf governorate, in the middle of Iraq. The present investigations has been approved by the Middle Euphrates Center For Cancer Research and patients were informed on the outcome of this work. Ages of the refereed patients were ranging from 30-70 years, with a median age of 50 years. A group of 21 patients

with benign breast lesions was included for comparison, while the control group included 14 cases of normal breast tissue. Avidin-Biotin Complex (ABC) method was employed for immunohistochemical detection of VEGF and Ki-67 according to the procedure which has been recommended by other investigators.^{8,11,14,15}

Statistical analysis. Association between immunohistochemical scorer and clinicopathological variables of tissue specimens were evaluated by χ^2 test; Chi square test at level of significance $\alpha \leq 0.05$ and correlation regression test (r at a significant level of 0.3). $p < 0.05$ was considered statistically significant.

Results. A positive VEGF immunoreaction was detected in 61.5% of malignant breast tissue, and in 19% of benign breast lesions. No positive over expression has been observed in normal breast tissues ($p < 0.001$, $p < 0.005$ and $p < 0.005$) (**Figure 1**). Vascular endothelial growth factor over-expression was well correlated to Ki-67 ($r = 0.93$, $p < 0.05$) (**Table 1**, **Figure 2**). Vascular endothelial growth factor immunohistochemical analysis in relation to grade of tumor revealed that 100% (2 out of 2) grade I were positive, 5 (55.6%) out of 9 cases of grade II were positive, 25 out of 41 (61%) cases of grade III were positive. It seems that the detection rate of VEGF is well correlated to the grade of tumor, ($r = 0.99$, $p < 0.05$) (**Table 2**). The intensity of VEGF looks to be well correlated to the grade of tumor (with positive regression $r = 0.97$), the intensity increased as the grade of the tumor increases, and a high proportion of VEGF expression was reported among those with poorly differentiated breast cancer, while less proportion of VEGF was reported among those with mild or moderate differentiated breast cancer with a significant difference ($p < 0.05$), indicating that VEGF positive breast cancers are biologically aggressive and detected more frequently in high grade than low grade (Grade III versus Grade I, II) ($p < 0.05$, $r = 0.99$). Also VEGF over-expression was detected more frequently in recurrent breast cancer; 50% of recurrent breast cancer (4 out of 8) were expressing VEGF immuneoreaction, while 36.4% of those presented for the first time (recurrence negative patients) were VEGF positive, with a significant difference between these 2 groups ($\chi^2 = 5.32$, $p < 0.05$) (**Table 3**).

Vascular endothelial growth factor over-expression was detected more frequently in node positive than in node negative breast cancers; 17 cases (68%) of node-positive breast cancer found to have positive VEGF overexpression, while only 5 cases (41.7%) of node-negative breast cancer showed VEGF overexpression, with significant and correlation between these 2 groups ($r = 0.97$, $p < 0.05$) (**Table 3**). Vascular endothelial growth factor immunohistochemical expression was

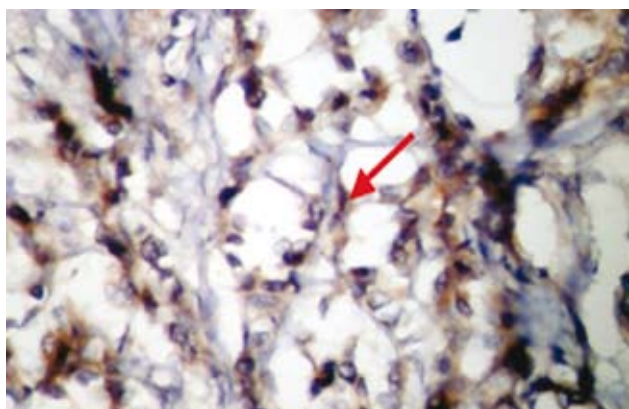


Figure 1 - Poorly differentiated infiltrating ductal carcinoma with fibro-fatty tissue invasion showing marked diffuse, score +4, strong vascular endothelial growth factor over-expression (higher power x40).

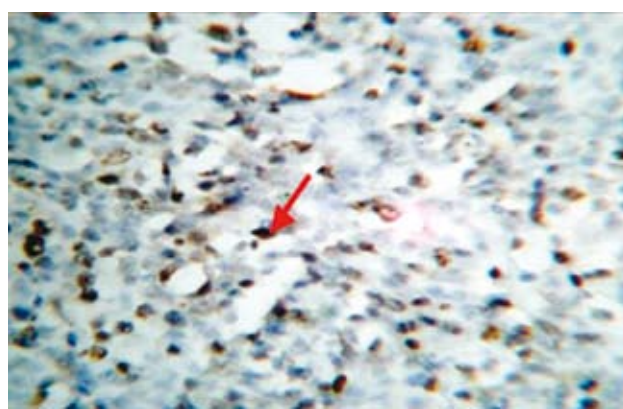


Figure 2 - Poorly differentiated infiltrating ductal carcinoma showed strong, diffuse, score+3 nuclear stain for Ki-67 protein (x40).

Table 1 - Frequency of immunoeexpression of vascular endothelial growth factor (VEGF) and Ki-67 in normal, benign, and malignant breast tissue and their correlation.

Pathological lesion	VEGF		Ki-67		P value
	Positive	Negative	Positive	Negative	
Normal n=14	0	14 (100)	0	14 (100)	NS
Benign breast lesions n=21	4 (19.0)	17 (81.0)	2 (9.5)	19 (90.5)	NS
Malignant breast lesions n=52	32 (61.5)	20 (38.5)	28 (53.9)	24 (46.2)	NS
Total	36 (41.4)	51 (58.6)	30 (34.5)	57 (65.5)	

$\chi^2=44.66$, $R=0.93$, $p<0.05$

Table 2 - The correlation of vascular endothelial growth factor (VEGF) immunohistochemical expression with grade of tumor and age of the patient.

Grade of tumor	VEGF immunostaining		Total n (%)	P value
	Positive	Negative		
I	2 (100)	0 (0)	2 (3.6)	Significant
II	5 (55.6)	4 (44.4)	9 (17.3)	Significant
III	25 (61.0)	16 (39.0)	41 (78.9)	Significant
Total	32 (61.6)	20 (38.5)	52 (100)	

$r=0.99$, $p<0.05$

reported in 100% (one out of one) of stage 0 CIS, in 42.9% (3 out of 7) of stage II, in 65.2% (15 out of 23) of stage III, and in 50% (3 out of 3) cases of stage IV. There was a significant positive correlation between VEGF overexpression and the stage of tumor ($r=0.95$) ($p<0.05$), and a higher proportion of cases was found in stage III and IV (Table 4).

Discussion. The present study was limited to the middle Euphrates area of Iraq. Any sporadic cases from elsewhere were excluded. Vascular endothelial growth

factor (VEGF-A) is a homodimeric glycoprotein that exists in at least 7 isoforms formed from alternative splicing of VEGF mRNA. The 4 main isoforms are VEGF 121, VEGF 165, VEGF 189 and VEGF 206.^{10,11} The antibody used in this study labels the VEGF-121, VEGF-165, and VEGF-189 isoforms of VEGF.^{19,20} Our result showed that 4 out of 21 (19%) of benign breast lesions were VEGF positive. Other investigators have noticed this finding as well.²¹⁻²³ The results have also clarified that 61.5% of 52 cases of breast cancer were expressing VEGF immunohistochemical cytoplasmic

Table 3 - Relation of vascular endothelial growth factor (VEGF) immunohistochemical overexpression to the recurrence of breast cancer and lymph node (LN) status.

Recurrence and LN status	VEGF immunostaining		Total n (%)	P value
	Positive	Negative		
<i>Recurrence</i>				
Positive	28 (3.6)	16 (36.4)	44 (84.6)	Significant
Negative	4 (50.0)	4 (50.0)	8 (15.8)	Significant
<i>LN status</i>				
Positive	8 (32.0)	17 (68.0)	25 (67.6)	
Negative	7 (58.3)	5 (41.7)	12 (32.4)	
r=0.99, p<0.05				

Table 4 - Vascular endothelial growth factor (VEGF) over expression in correlation to stage of breast cancer.

Stage of tumor	VEGF immunostaining		Total n (%)	P value
	Positive	Negative		
T0	1 (100)	0 (0)	1 (2.7)	Significant
II	0 (0)	0 (0)	0 (0)	Significant
III	3 (42.9)	4 (57.1)	7 (18.9)	Significant
IV	15 (65.2)	8 (34.8)	23 (62.6)	Significant
Total	3 (50.0)	3 (50.0)	6 (16.2)	
			37 (100.0)	
r=0.99, p<0.05				

staining in their histological sections (**Table 1, Figure 1**). Previous investigators have shown similar results although the predictive value was slightly variable ranging from 60.5-67.7%.²⁴⁻²⁷ However, our findings extend within the same range although technical skills might be behind this variability. Our work have demonstrated a statistically significant association between VEGF and Ki-67 overexpression in breast cancer ($p<0.05$). Furthermore, we found that Ki-67 overexpression was positively correlated to VEGF ($r=0.93, p<0.05$) (**Table 1**) as indicated by Xie et al²⁸ and not with that of Li et al,²⁹ who did not reach similar results. Such differences most probably due to technical skills, type of materials which has been used, number of patients which should be included in the study and so forth.

Furthermore, our results support more recent findings of the presence of significant positive correlation between VEGF over expression and the grade of breast cancer as grouped in **Table 2**. This finding indicates very clearly, the involvement of VEGF gene in promoting tumor angiogenesis and the extent of its role in the pathogenesis of human cancer.^{27,30} Our results also showed that the VEGF expression is not related to age of the patient with breast cancer (**Table 2**). This finding is similar to that reported by Gasparini et al, 1997 and Yi W et al, 2003; who proposed that VEGF expression

is not correlated to age of breast cancer patients.^{15, 33} On the other hand, the significant difference between recurrent and non-recurrent breast cancers which has been demonstrated in our study ($p<0.05$) (**Table 3**) may reflect the more aggressive behavior of VEGF-positive recurrent breast cancer although many investigators showed that VEGF over-expression is directly related to the recurrence of breast cancer.³¹ As presented in **Table 3**, VEGF overexpression is significantly higher in node positive breast cancer than node negative breast cancer ($p<0.05$). This finding supports our previous finding that indicates positive correlation between VEGF over expression with the grade and stage of cancer which confirm the contribution of VEGF factor in breast cancer development, evolution, and metastasis. However, other investigators have conducted similar work and have shown similar results.³³⁻³⁷ Tumors with insertions, deletions or nonsense mutations were found to have the highest degree of correlation with increased VEGF expression which gives rise to truncated proteins.⁷ This study also discussed the significant correlation in VEGF overexpression to the stage of breast cancer ($r=0.95, p<0.05$) (**Table 4**) which indicates the importance of pathological assessment and staging of breast cancer in any future study and confirms the work of other researchers who reached the same conclusion.^{23,30,32}

These data indicate that human breast cancer has the capacity to over-express VEGF gene and suggest that in some instances VEGF may directly or indirectly promote breast cancer growth. The increased VEGF expression may be a key event in the pathogenesis of human breast cancer.

In conclusion, VEGF plays an important role in pathogenesis of breast cancer evolution. We may recommend that blocking VEGF could be a target for inhibition of angiogenesis and hence improving the efficacy of anti-cancer therapy, although further analysis of the expression of angiogenic factors in clinical tumors sample might provide more information about genetic involvement in the regulation of angiogenesis.

References

- Parkin DM, Bray F, Ferlay J, Pisani P. Estimating the world cancer burden: Globocan 2000. *Int J Cancer* 2001; 94: 153-156.
- Lichtenbeld HC, Barendsz-Janson AF, van Essen H, Struijker Boudier H, Griffioen AW, Hillen HF. Angiogenic potential of malignant and non-malignant human breast tissues in an in vivo angiogenesis model. *Int J Cancer* 1998; 77: 455-459.
- Dabrosin C, Palmer K, Muller WJ, Gaudie J. Estradiol promotes growth and angiogenesis in polyoma middle T transgenic mouse mammary tumor explants. *Breast Cancer Res Treat* 2003; 78: 1-6.
- Schneider BP, Miller KD. Angiogenesis of breast cancer. *J Clin Oncol* 2005; 23: 1782-1790.
- Brown LF, Guidi AJ, Schnitt SJ, Van De Water L, Iruela-Arispe ML, Yeo TK, et al. Vascular stroma formation in carcinoma in situ, invasive carcinoma, and metastatic carcinoma of the breast. *Clin Cancer Res* 1999; 5: 1041-1056.
- Weidner N, Semple JP, Welch WR, Folkman J. Tumor angiogenesis and metastasis-correlation in invasive breast carcinoma. *N Engl J Med* 1991; 324: 1-8.
- Ferrara N, Davis ST. The biology of VEGF. *Endocr. Rev.* 1997; 18:4-25.
- Achen MG, Stacker SA. The vascular endothelial growth factor family; proteins which guide the development of the vasculature. *Int J Exp Pathol* 1998; 79: 255-265.
- Ferrara N. VEGF: an update on biological and therapeutic aspects. *Curr Opin Biotechnol* 2000; 11:617-641.
- Ferrara N. Role of vascular endothelial growth factor in regulation of physiological angiogenesis. *Am J Physiol Cell Physiol* 2001; 280: C1358-C1424.
- Ferrara N, Hans-Peter G, Jennifer LC. The biology of VEGF and its receptors. *Nature Medicine* 2003; 9: 669-676.
- Shibuya M: Structure and function of VEGF/VEGF-receptor system involved in angiogenesis. *Cell Struct Funct* 2001; 26: 25-35.
- Soker S, Fidler IJ, Neufeld G, Klagsbrun M. Characterization of novel vascular endothelial growth factor (VEGF) receptors on tumor cells that bind VEGF165 via its exon 7-encoded domain. *J Biol Chem* 1996; 271: 5761-5767.
- Neufeld G, Cohen T, Gengrinovitch S, Poltorak Z. Vascular endothelial growth factor (VEGF) and its receptors. *FASEB J* 1999; 13: 9-22.
- Gasparini G, Toi M, Gion M, Verderio P, Dittadi R, Hanatani M, et al. Prognostic significance of vascular endothelial growth factor protein in node-negative breast carcinoma. *J Natl Cancer Inst* 1997; 89: 139-147.
- Obermair A, Kucera E, Mayerhofer K, Speiser P, Seifert M, Czerwenka K, et al. Vascular endothelial growth factor (VEGF) in human breast cancer: correlation with disease-free survival. *Int J Cancer* 1997; 74: 455-458.
- Salven P, Perhoniemi V, Tykka H, Maenpaa H, Joensuu H. Serum VEGF levels in women with a benign breast tumor or breast cancer. *Breast Cancer Res Treat* 1999; 53: 161-166.
- Ragaz J, Miller K, Badve S, Dayachko Y, Dunn S, Nielsen T, Brodie A, Huntsman D, Bajdik C et al. Adverse association of expressed vascular endothelial growth factor (VEGF) Her2, Cox2, uPA, and EMSY with long-term outcome of stage I-III breast cancer (BrCA). *J Clin Oncol* 2004; 22 (Suppl 14S): 524.
- Heffelfinger SC, Miller MA, Yassin R and Gear R. Angiogenic Growth Factors in Preinvasive Breast Disease. *Clin Cancer Res* 1999; 5: 2867-2876.
- Heffelfinger SC, Yassin R, Miller MA, Lower E. Vascularity of Proliferative breast disease and carcinoma in situ correlates with Histologic features. *Clinical Cancer Res* 1996; 2: 1873-1878.
- Kranz A, Mattfeldt T, Waltenberger J. Molecular mediators of tumor angiogenesis: enhanced expression and activation of vascular endothelial growth factor receptor KDR in primary breast cancer. *Int J Cancer* 1999; 84: 293-298.
- Viacava P, Naccarato AG, Bocci G, Fanelli G, Aretini P, Lonobile A, et al. Angiogenesis and VEGF expression in pre-invasive lesions of the human breast. *J Pathol* 2004; 204: 140-146.
- Shankar R, Satyendra K. Tiwary, Rahul Khanna, Mohan Kumar, A. K. Khanna: Tumor angiogenesis: determined by vegf expression, mags scoring, doppler study, as prognostic indicator in carcinoma breast. The Internet Journal of Surgery [cited 2006]. Available from URL: <http://www.ispub.com/ostia/index.php?xmlFilePath=journals/ij/s/vol8n1/vegf.xml>
- Granato AM, Nanni O, Falcini F, Folli S, Mosconi G, De Paola F, et al. Basic fibroblast growth factor and vascular endothelial growth factor serum levels in breast cancer patients and healthy women: useful as diagnostic tools? *Breast Cancer Res* 2004; 6: R38-45. Epub 2003 Nov 25.
- Li J, Song ST, Jiang XQ, Yan LD. [Significance of microvascular density and vascular endothelial growth factor in breast cancer]. *Zhonghua Zhong Liu Za Zhi* 2003; 25: 145-148. Chinese.
- Matkowski R, Gisterek I, Suder E, Lacko A, Szelachowska J, Ramsey D, et al. Correlation between vascular endothelial growth factor and c-met expressions in breast carcinoma. *Journal of Clinical Oncology* 2006; 24: 18S (June 20 Suppl): 10621.
- Linderholm B, Tavelin B, Grankvist K, Henriksson R. Vascular endothelial growth factor is of high prognostic value in node-negative breast carcinoma. *J Clin Oncol* 1998; 16: 3121-3128.
- Xie B, Tam NN, Tsao SW, Wong YC. Co-expression of vascular endothelial growth factor (VEGF) and its receptors (flk-1 and flt-1) in hormone-induced mammary cancer in the Noble rat. *Br J Cancer* 1999; 81: 1335-1343.
- Li BJ, Zhu ZH, Wang JY, Hou JH, Zhao JM, Zhang PY, et al. [Expression correlation of Ki67 to P53, VEGF, and C-erbB-2 genes in breast cancer and their clinical significances]. *Ai Zheng* 2004; 23: 1176-1179. Chinese.
- Valcovic T, Dobrila F, Melato M, Sasso F, Rizzardi C, Jonjic N. Correlation between vascular endothelial growth factor, angiogenesis, and tumor associated macrophages in invasive ductal breast carcinoma. *Virchows Arch* 2002; 440: 583-591. Epub 2001 May 16.

29. Bolat F, Kayaselcuk F, Nursal TZ, Yagmurdu MC, Bal N, Demirhan B. Microvessel density, VEGF expression, and tumor-associated macrophages in breast tumors: correlations with prognostic parameters. *J Exp Clin Cancer Res* 2006; 25: 365-372.
30. Xu W, Wang G, Zou Y, Song J, Yang X, Wang W. Vascular endothelial growth factor expression in invasive ductal carcinoma of breast. *Chinese Journal of Cancer Research* 2007; 19: 56-59.
31. Linderholm B, Grankvist K, Wilking N, Johansson M, Tavelin B, Henriksson R. Correlation of vascular endothelial growth factor content with recurrences, survival, and first relapse site in primary node-positive breast carcinoma after adjuvant treatment. *J Clin Oncol* 2000; 18: 1423-1431.
32. Collagy G, Dimitriadis E, Harmey J, Bouchier-Hayes D, Leader M, Kay E. Immunohistochemical measurement of tumor vascular endothelial growth factor in breast cancer ,a more reliable predictor of tumor stage than Microvessel density or serum vascular endothelial growth factor. *Appl Immunohistochem Mol Morphol* 2000; 8: 104-113.
33. Yi WJ, Tang ZH, Yang ZL, Yu MY, Li YS, Chen GN. Difference in expression of VEGF, bFGF and their receptors between the young and postmenopausal women with breast cancer. *Zhonghua Zhong Liu Za Zhi* 2003; 25: 141-145.
34. Greb RR, Maier I, Wallwiener D, Kiesel L. Vascular endothelial growth factor A (VEGF-A) mRNA expression levels decrease after menopause in normal breast tissue but not in breast cancer lesions. *Br J Cancer* 1999; 81: 225-231.
35. Hu SE, Zhang YJ, Cui YM, Zhang HQ. Expression of vascular endothelial growth factor A and C in human breast cancer and their significance. *Ai Zheng* 2005; 24: 1076-1085.
36. Wang XB, Yang QX, Pei XJ. Expression of angiogenesis-related factors in invasive breast cancer and its clinical significance. *Nan Fang Yi Ke Da Xue Xue Bao* 2006; 26: 860-863.
37. Hao L, Zhang C, Qiu Y, Wang L, Luo Y, Jin M, Zhang Y, Guo TB, Matsushima K, Zhang Y. Recombination of CXCR4, VEGF, and MMP-9 predicting lymph node metastasis in human breast cancer. *Cancer Lett* 2007; 253: 34-42.

New Peer Reviewers

Join our team of expert peer reviewers for Saudi Medical Journal by registering through the website at http://www.smj.org.sa/_Authors/ and select "register now" or sending an enquiry and summarized CV to info@smj.org.sa. Note that SMJ reviewers, whose reviews are returned on time and are judged satisfactory by the Editors, may receive 1 CME credit per review, with a maximum of 5 credit per year, from the Saudi Council for Health Specialties.