Townes-Brocks syndrome

A neonate with extended spectrum and thrombocytopenia

Ramesh Y. Bhat, *MBBS, MD,* ***Supratem Sen,*** *MBBS, MD.*

ABSTRACT

تعتبر متلازمة تاونس– بروكس متلازمة تشوه نادرة وذلك حسب شكل الإبهام والأذن والكلى والشذوذ في القناة الشرجية. تم التبليغ عن الحالات الوراثية والحالات المعزولة المصابة باختلاف الجنس السريري في الأدبيات الطبية. نذكر هنا حالة فردية تعاني من سمات سريرية نمطية وبطيف متمدد، والذي لم يتم وصفه مسبقاً. كان شلل الوجه للجانب الأيسر، والانسداد الخلقي للقناة السمعية الخارجية، وتعجر اليد مع اللاتنسج للكعبرة ،وتعجر كلتا القدمين، وتمزق الجلد العجزي، من النتائج الإضافية. كانت القناة الشريانية المفتوحة المعزولة النقص القلبي الخلقي المصاحب. كما اعتُبرت قلة الصفيحات الدموية من الحالات الشاذة الأخرى التي تم توثيقها.

Townes-Brocks syndrome is a rare malformation syndrome characterized by thumb, auricular, renal, and anal anomalies. Both familial and isolated cases with clinical heterogeneity were reported in the medical literature. We present a sporadic case with typical clinical features and extended spectrum, that has previously not been described. Left sided facial palsy, external auditory canal atresia, club hand with radius aplasia, bilateral clubfoot, and sacral skin tag were the additional findings. Isolated patent ductus arteriosus was the associated congenital heart defect. Thrombocytopenia was another documented hematological abnormality.

Saudi Med J 2008; Vol. 29 (9): 1337-1339

From the Department of Pediatrics, Kasturba Medical College, Manipal University, Udupi District, Karnataka, India.

Received 6th February 2008. Accepted 7th July 2008.

Address correspondence and reprint request to: Dr. Ramesh Y. Bhat, Associate Professor, Department of Pediatrics, Kasturba Medical College, Manipal University, Manipal 576104, Udupi District, Karnataka, India. Tel. +91 (944) 8296564. Fax: +91 (820) 2571934. E-mail: docrameshbhat@yahoo.co.in

In 1972, Townes and Brocks described a family with imperforate anus, abnormalities of hands and feet, and sensorineural deafness with satyr ears.[1] The association of thumb anomalies, auricular anomalies, and anal anomalies have since been found to have autosomal dominant inheritance, and was named as Townes-Brocks syndrome (TBS). Cases reported subsequently in the medical literature describe multiple malformations and variable expression.[2-7] We report a neonate having this uncommon syndrome with extended spectrum and thrombocytopenia.

Case Report. The present case was a male infant born to a 25 year old multiparous woman. The parentage was non-consanguineous. No dysmorphology or developmental delay was noted in one elder sibling, parents, or in the family. There was no history of teratogenic drug intake or radiation exposure during pregnancy. At birth, the infant required resuscitation, but subsequently had stable cardio respiratory function. He had birth weight of 2900g, length of 45 cm, and head circumference of 35 cm. Physical examination showed following anomalies: 1) Craniofacial - facial asymmetry with facial palsy on the left side (**Figure 1a**), left auricular abnormality (lop ear) with absence of external auditory canal (**Figure 1b**), and preauricular tag and prominent tragus on right side (**Figure 1c**). 2) Limbs - radial club hand (**Figure 1d**) with single palmar crease on left side, triphalangeal thumb with preaxial polysyndactyly of right hand, and bilateral clubfoot (**Figure 1e**). 3) Anal - imperforate anus (**Figure 1f**). (4) Skin -skin tag over the sacral area (**Figure 1f**). 5) Genitourinary - glandular hypospadias.

G-banded karyotyping showed 47, XY. Antenatal sonography showed oligohydramnios and dilated fetal bowel loops. Blood investigations showed hemoglobin of 14.1g/dL (normal range: 14-18g/dL) and platelet count of 93,000/ mm^3 (normal range: 150000-400000/ mm^3). Serum creatinine was 0.8mg/dL (normal range: 0.2-0.8mg/dL). Radiograph showed absent radius in the left upper limb (**Figure 1g**). Invertogram showed a low anorectal malformation. Vertebral roentgenograms

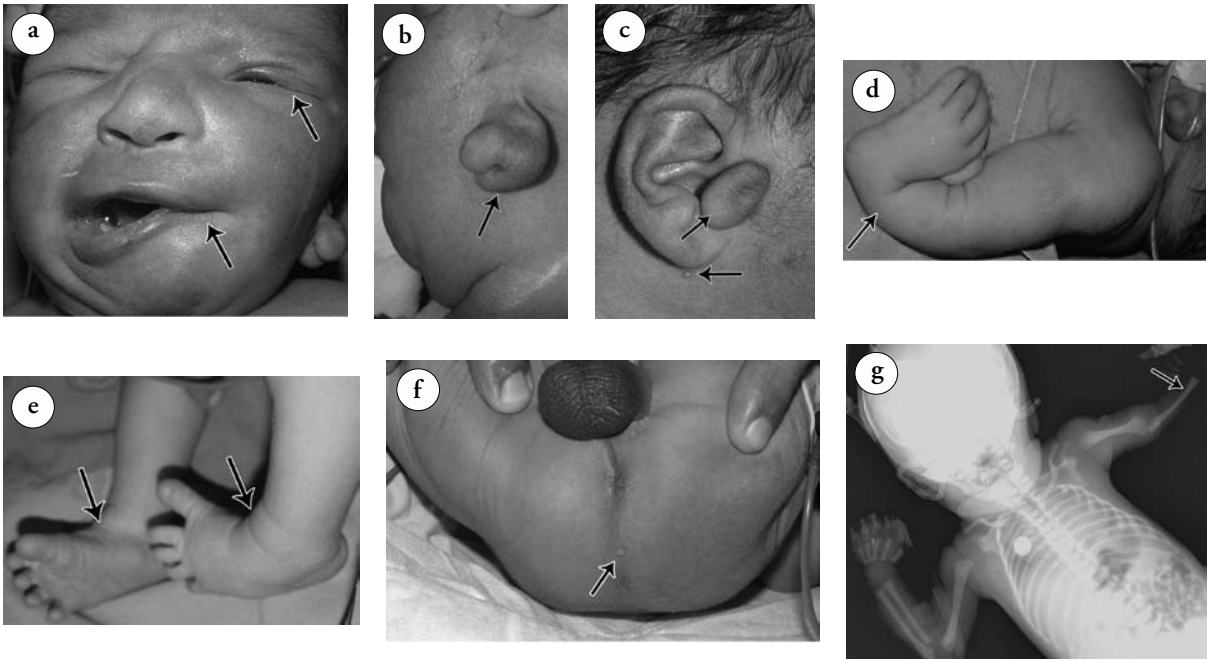

Figure 1 - Townes-Brocks syndrome: **a**) Facial palsy (left side), **b**) lop ear, absent external auditory canal (left side), **c**) large tragus and preauricular skin tag (right side), **d**) radial club hand (left side), **e**) congenital talipes equinovarus (bilateral), **f**) imperforate anus and sacral skin tag (arrow), and **g**) radiograph showing absent radius the on left side (arrow).

were normal. Abdominal ultrasound showed absence of kidney on left side. Neurosonogram ruled out gross structural malformations of brain. Echocardiography showed a small patent ductus arteriosus with a left-to-right shunt. No cytogenetic analysis of SALL1 gene was performed in this study. Colostomy was carried out to decompress the bowel. Serial plaster cast application was started for the radial club hand and corrective passive exercises were started for the club feet. The need for hearing assessment and regular follow up was informed for the infant.

Discussion. Townes-Brocks syndrome is an uncommon disorder of multiple malformations, thought to be of autosomal dominant in inheritence. Major findings include external ear anomalies, hearing loss, preaxial polydactyly and triphalangeal thumbs, imperforate anus, and renal malformations.[6] Frequent and marked variability in the severity of clinical expression causes diagnostic difficulties. The etiology proposed for TBS includes mutations in the SALL1 gene located at 16q12.1.[7,8]

Our case satisfies the typical features of thumb, auricular, anal, and renal anomalies, and hence labeled as TBS.[2,6] A formerly reported association with congenital heart disease was also observed. Atrial and ventral septal defects, tetralogy of Fallots, lethal truncus arteriosus and pulmonary atresia were reported previously.[6,9] The present case had only isolated patent ductus arteriosus. Renal abnormalities that have previously been reported include unilateral or bilateral hypoplastic or dysplastic kidneys, renal agenesis and multicystic kidney.[2,3,6] In our case left kidney was absent. Interestingly, phenotypic features were absent in other family members. Sporadic occurrences of TBS have also been reported previously.[7,10-12]

Our case is unique in its manifestation of unilateral facial nerve palsy, absent external auditory canal, unilateral radial club hand with absent radius, and sacral skin tag. These anomalies have previously not been described in TBS. Formerly described facial asymmetry includes hemifacial microsomia and absence of depressor angulii oris muscle. The club foot was observed bilaterally. Variability in clinical expression of the syndrome has been suggested earlier.[2,7-9] Even absence of anorectal malformations in father alone was described when both father and his son were diagnosed to have TBS.[13] Similarly absence of characteristic anal and hand malformations of TBS in all of the affected family members were also described.[14] It is also known that TBS encompasses many of the clinical features of vertebral defects, anal atresia, (cardiovascular anomalies), tracheoesophageal fistula with esophageal

atresia, renal and or radial anomalies, (limb anomalies) [VA (C)TER(L)] association and oculoauriculovertebral spectrum.[2,6,7] These associations include tracheo-oesophageal fistula, or vertebral anomalies as their characteristic features. Such anomalies were not seen in the present case. Further, thrombocytopenia was observed as an additional hematological abnormality in our case. Absent radius and thrombocytopenia are common in thrombocytopenia absent radii (TAR) syndrome. However, radii are absent bilaterally in TAR syndrome.[15] Again, the characteristics lop ear, absences of left kidney, and other typical features of the present case are consistent with TBS. Hence, the present case appears to be an extension of the previously described spectrum of TBS.

Affected children require immediate attention like colostomy for imperforate anus in the immediate neonatal period as in our case. They also require hearing assessment, and serial monitoring of renal function. Cardiac evaluation is also suggested. Most patients with TBS have normal intelligence, although mental retardation[6,7] has been noted in a few.

References

1. Townes PL, Brock ER. Hereditary syndrome of imperforate anus with hand, foot and ear anomalies. ***J Pediatr*** 1972; 81: 321-326.
2. Jones KL. Smith's recognizable patterns of human malformation. 6th ed. Philadelphia (PA): Elsevier Saunders; 2006. p. 290.
3. Kurnit DM, Steele MW, Pinksy L, Dibbins A. Autosomal dominant transmission of a syndrome of anal, ear, renal and radial congenital malformations. ***J Pediatr*** 1978; 93: 270-273.
4. Reid IS, Turner G. Familial anal abnormality. ***J Pediatr*** 1976; 88: 992-994.
5. Walpole IR, Hockey A. Syndrome of imperforate anus, abnormalities of hands and feet, satyr ears, and sensorineural deafness. ***J Pediatr*** 1982; 100: 250-252.
6. Powell CM, Michaelis RC. Townes-Brocks syndrome. ***J Med Genet*** 1999; 36: 89-93.
7. Townes Brocks syndrome. Online Mendelian Inheritance in Man, Johns Hopkins University: updated 2008 Feb 1 [online]. Available at: http://www.ncbi.nlm.nih.gov/ entrez/dispomim.cgi?id=107480. Accessed on 1.6.2008
8. Kohlhase J, Wischermann A, Reichenbach H, Froster U, Engel W. Mutations in the SALL1 putative transcription factor gene cause Townes-Brocks syndrome. ***Nat Genet*** 1998; 18: 81-83.
9. Monteiro de Pina-Neto J. Phenotypic variability in Townes-Brocks syndrome. ***Am J Med Genet*** 1984; 18: 147-152.
10. Parent P, Bensaid M, Le Guern H. Clinical heterogeneity of Townes-Brocks syndrome. ***Arch Pediatr*** 1995; 2: 551-554.
11. Doray B, Langer B, Stoll BC. Two cases of Townes-Brocks syndrome. ***Genet Counsel*** 1999; 10: 359-367.
12. Konig R, Schick U, Fuchs S. Townes-Brocks syndrome. ***Eur J Pediatr*** 1990; 150: 100-103.
13. de Vries-Van der Weerd MA, Willems PJ, Mandema HM, ten Kate LP. A new family with the Townes-Brocks syndrome. ***Clin Genet*** 1988; 34: 195-200.
14. Albrecht B, Liebers M, Kohlhase J. Atypical phenotype and intrafamilial variability associated with a novel SALL1 mutation. ***Am J Med Genet*** 2004; 125A: 102-104.
15. Thrombocytopenia-absent radius syndrome. Online Mendelian Inheritance in Man, Johns Hopkins University: updated 2007 Jan 17 [online]. Available at: http:www.ncbi.nlm.nih.gov/ entrez/dispomim.cgi?id=274000. Accessed on 1.6.2008

Copyright

Whenever a manuscript contains material (tables, figures, etc.) which is protected by copyright (previously published), it is the obligation of the author to obtain written permission from the holder of the copyright (usually the publisher) to reproduce the material in Saudi Medical Journal. This also applies if the material is the authors own work. Please submit copies of the material from the source in which it was first published.