

Congenital unilateral nasal aperture stenosis

Eidha F. AlJuaid, MBBS, SSC-ORL, Fahad M. Alshehri, MBBS, MD.

ABSTRACT

يعد ضيق فتحة الأنف الخلقي أحد الأسباب غير المعتادة لانسداد مجرى الهواء التنفسي بين الأطفال حديثي الولادة كما أن ظهوره في جهة واحدة (فتحة أنف واحدة) يعد من الأمور النادرة، وتعد الأشعة المقطعية (CT) من الوسائل الأساسية للتأكد من صحة التشخيص. يمكن في مثل هذه الحالات اللجوء إلى التدخل الجراحي أو العلاجي وذلك على حسب شدة الحالة ولكن غالباً ما يتم علاج الحالات التي يظهر فيها الانسداد في جهة واحدة دون الحاجة إلى الجراحة. نستعرض في هذا التقرير حالة طفل ذكر عمره 30 يوماً، وهو توأم مولود في الأسبوع 29 من الحمل ووزنه كيلو جرام واحد تقريباً، وكان منذ ولادته يعاني من صعوبة شديدة في التنفس. لقد تم عرض هذا الطفل على استشاري الأنف والأذن والحنجرة، وحينها تم وضع قنية أنفية للأوكسجين لهذا الطفل ولم يلاحظ أنه يعاني من ضيق في التنفس، ولا صرير، ولا سرعة في التنفس، غير أن هناك ضعف في صوت التنفس من فتحة الأنف اليسرى، وقد فشلت المحاولات في إدخال أنبوبة الأنف المعدنية التي كانت من مقاس 8 و 6 وظهر أن هناك انسداداً في مقدمة فتحة الأنف.

Congenital nasal aperture stenosis is an unusual cause of upper airway obstruction among neonates, and rarely presents as unilateral. Most commonly presents as choanal atresia. A CT evaluation is essential to confirm the diagnosis. Both surgical and conservative management can be applied, based on the severity of the associated clinical presentation; however, the very rare unilateral condition is usually treated conservatively. We present a case of a 30-day-old male baby (second twin, preterm 29 weeks pregnancy, and birth weight 1.070 kg) with difficult breathing since birth. The baby was referred for an ENT consultation. He was on a nasal cannula, not in respiratory distress, with no stridor, nor tachypnea. There were decreased breathing sounds in the left nostril. Nasogastric tubes size 8 French (Fr) and 6 Fr could not be introduced through the left nostril, which looked obstructed more anteriorly.

Saudi Med J 2010; Vol. 31 (9): 1057-1058

From the ENT (AlJuaid), and Radiology Departments (Alshehri), Armed Forces Hospitals, Taif, Kingdom of Saudi Arabia.

Received 29th June 2010. Accepted 16th August 2010.

Address correspondence and reprint request to: Dr. Eidha F. AlJuaid, ENT Department, Armed Forces Hospitals, PO Box 1347, Taif 21944, Kingdom of Saudi Arabia. Tel. +966 504515145. Fax. +966 (2) 7504247. E-mail: ptrc_alhada@yahoo.com

Congenital nasal piriform aperture stenosis (CNPAS) has been described as an unusual cause of neonatal upper airway obstruction.¹ Clinical presentation is very similar to other congenital anomalies including choanal atresia with respiratory distress, cyclic cyanosis, apneas, and feeding difficulties.² A bony overgrowth of the maxillary nasal processes is thought to be responsible for this deformity. Infants may experience respiratory distress at birth or within the first few months of life.³ Upper respiratory infection can be the cause of worsening breathing problems, especially among patients with already-narrowed nasal passages.⁴ This anomaly may be isolated or associated with craniofacial or central nervous system (CNS) anomalies.^{2,3} We present this case as it is a rare condition, and even uncommon to present unilaterally. The true incidence of this case is unknown.⁵ This condition can easily lead to respiratory distress if not promptly recognized and appropriately treated.³ In cases of severe respiratory distress, feeding difficulties, and when conservative methods fail, then surgery is the appropriate intervention.²

Case Report. A 30-day-old male baby (second twin, preterm 29 week pregnancy, and birth weight 1.070 kg) with difficult breathing since birth, was referred for an ENT consultation. He was not in respiratory distress, with no stridor, nor tachypnea. He was on a nasal cannula. There were decreased breathing sounds in the left nostril. A nasogastric tube (NGT) size 8 French (Fr) and 6 Fr could not be introduced through the left nostril, which looked obstructed more anteriorly. To exclude the possibility of choanal atresia or other facial anomalies, CT of the maxillofacial skeleton was requested.

On maxillofacial CT, the anterior bony aperture was narrowed secondary to medialization of the nasal processes of the maxillary bones (Figures 1 & 2). There was no evidence of choanal atresia and no abnormal airway. Clinical suspicion for CHARGE (an acronym used to describe specific congenital birth defects in children: colobomata, heart defect, atresia of the choanae, retarded growth or development, genital hypoplasia, and ear anomalies or deafness) or other airway anomalies were ruled out. He was diagnosed with unilateral left nasal aperture stenosis.

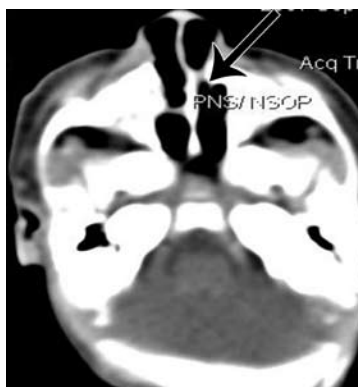


Figure 1 - Axial, bone window CT cut. There is narrowing of the anterior bony nasal aperture secondary to medialization of the nasal processes of the maxillary bones.

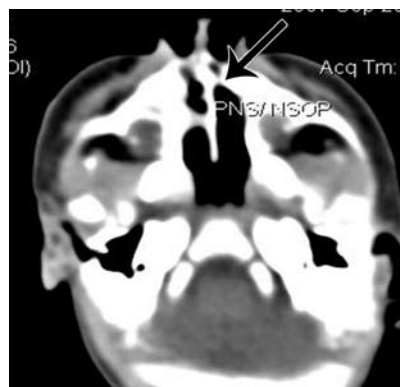


Figure 2 - Axial, bone window CT cut. There is no evidence of choanal atresia and no abnormal airway.

Conservative treatment in the form of saline solution and humidified oxygen was the treatment option in our case due to its less severe clinical presentation, and he responded very well to this treatment. The mother was instructed on noticing any of the respiratory distress manifestations such as cyanosis, apnea, or persistent feeding difficulties with inappropriate weight gain. On discharge and subsequent follow-up at the outpatient clinic, he was in good condition, breathing, and feeding well.

Discussion. The piriform aperture is the bony opening of the anterior nasal passage and the narrowest portion of the nasal cavity. It is bordered superiorly by the nasal bone, inferiorly by the nasal surface of the maxilla, and posteriorly by the horizontal plate of the palate.² Congenital nasal piriform aperture stenosis is an uncommon cause of nasal obstruction in the newborn.¹ For CNPAS to occur, there may be abnormal growth of the primary palate or bone overgrowth of the nasal process of the maxilla, which should be distinguished from choanal stenosis and atresia.⁴ The CNPAS can be manifested as respiratory distress, cyanosis, and inability or difficulty in passing a NG tube. Feeding often exacerbates respiratory distress and crying may alleviate it. Axial CT is confirmatory when congenital nasal piriform aperture stenosis is suspected. Among infants, a piriform aperture width of less than 11 mm is diagnostic. The choana may be smaller than usual, but should not be stenotic.³ Occasionally, a hypoplastic triangular hard palate with an inferior midpalatal vomerine ridge and abnormal dentition, particularly a single or fused central maxillary mega incisor, or a single large central upper incisor (mega incisor) can be identified. They are usually identified in children as midface anomalies.^{2,6} However, none of these features were identified in the current case. An MRI can be useful to rule out other associated congenital anomalies like midface masses (such as dermoid cysts,

epidermoid cysts, nasal gliomas, and encephalocèles) or holoprosencephaly, pituitary insufficiency, clinodactyly, hypotelorism, and cleft palate. The CNPS can present either as an isolated form or be associated with other anomalies. An MRI of the brain is highly recommended when intracranial defects are suspected (for example, central mega incisor).⁴ Management is based on the severity of symptoms. Intubation and ventilation may be required. Medical treatment in the form of saline solution, nasal decongestants, and humidification have shown excellent prognosis in many patients. Over time, nasal cavities grow and the obstruction is relieved,¹ however, surgical intervention should be the choice if there is no improvement 10-15 days following the medical treatment,⁷ or there are manifestations of respiratory distress (for example, cyanosis, apnea, or persistent feeding difficulties with inappropriate weight gain). Surgical management of CNPAS includes dilation and stenting or through a sub labial approach to the premaxilla depending upon the extent of stenosis.⁵

References

1. Breckpot J, Hermans R, Poorten VV, Vermeesch JR, Devriendt K. Congenital nasal piriform aperture stenosis as a rare manifestation of monosomy 1p36. *Clin Dysmorphol* 2010; 19: 95-97.
2. Vercruyse JP, Wojciechowski M, Koninckx M, Kurotova A, Claes J. Congenital nasal pyriform aperture stenosis: a rare cause of neonatal nasal obstruction. *J Pediatr Surg* 2006; 41: e5-e7.
3. Rajaram S, Bateman N, Raghavan A. Congenital nasal piriform aperture stenosis with vestibular abnormality. *Pediatr Radiol* 2008; 38: 1128-1129.
4. Lowe LH, Booth TN, Joglekar JM, Rollins NK. Midface anomalies in children. *Radiographics* 2000; 20: 907-922.
5. Tate JR, Sykes J. Congenital nasal pyriform aperture stenosis. *Otolaryngol Clin North Am* 2009; 42: 521-525.
6. Bignault A, Castillo M. Congenital nasal piriform aperture stenosis. *AJNR Am J Neuroradiol* 1994; 15: 877-878.
7. Baker KA, Pereira KD. Congenital nasal pyriform aperture stenosis. *Operative Techniques in Otolaryngology-Head and Neck Surgery* 2009; 20: 178-182.