

Medial open reduction of developmental dysplasia of the hip using the Weinstein-Ponseti approach

Cemil Erturk, MD, Mehmet A. Altay, MD, Raci Yarimpapuc, MD, Ugur E. Isikan, MD.

ABSTRACT

الأهداف: تقييم مدى فعالية وأمان الإجراء الجراحي لرد خلع الورك بعملية فتح الكسر وباستخدام طريقة وينستين بونسيري من أجل علاج الأطفال المصابين بخلل التنسج النمائي للورك.

الطريقة: أجريت هذه الدراسة الاسترجاعية في قسم تقويم العظام بكلية الطب التابعة لجامعة حران، سانليورفا، تركيا، واستمرت خلال الفترة من أبريل 1997م إلى فبراير 2009م. شملت الدراسة 35 حوضاً لحوالي 24 طفلاً (ولد واحد، و23 أنثى، متوسط العمر: 10.8 ± 2.82 عاماً). لقد قمنا بتقييم الصور الإشعاعية لأحواض المرضى قبل إجراء العملية الجراحية وذلك بواسطة نظام تونيس ومؤشر تجويف قاعدة عظمة الفخذ، وفيما بعد قُسم المرضى إلى مجموعتين: المجموعة 1 وشملت 13 مريضاً تقل أعمارهم عن 12 شهر (19 حوض)، والمجموعة 2 وشملت 11 مريضاً تزيد أعمارهم عن 12 شهر أو أكثر من ذلك (16 حوض). لقد اعتمدنا في تقييمنا السريري والإشعاعي للمرضى على معايير ماكي وسيفيرينز كلاً على حدة. فيما اعتمد تشخيص الإصابة بتنخر العظام اللاوعائي على تصنيف كالاماتشي وماك إوين.

النتائج: أشارت نتائج الدراسة إلى أن متوسط فترة المتابعة بعد إجراء العملية قد وصل إلى 5.6 ± 3.1 عاماً (يتراوح ما بين 2-12 عاماً). وقد احتاجت 5 أحواض (14.2%) إلى عملية جراحية أخرى، فيما تم تشخيص تنخر العظام اللاوعائي في 6 أحواض (17.1%). وأظهر التقييم الإشعاعي والسريري بأنه لم يكن هناك اختلافاً واضحاً في النتائج بين المجموعة 1 و2، بالإضافة إلى ذلك فقد كانت معدلات تنخر العظام اللاوعائي بعد انتهاء فترة المتابعة متشابهة بين المجموعتين.

خاتمة: أثبتت الدراسة تشابه نتائج إجراء العملية الجراحية بعد وقبل 12 شهر وذلك بعد عمل التحليل الاسترجاعي الذي قمنا فيه بالمقارنة بين النتائج، كما أننا لم نجد فرقاً بين المجموعتين. ويمكن اللجوء إلى هذه الطريقة في علاج الأطفال المصابين بخلل التنسج النمائي للورك وحتى سن 16 شهر.

Objectives: To evaluate the efficacy and safety of medial open reduction using the Weinstein-Ponseti approach to treat developmental dysplasia of the hip (DDH).

Methods: In this retrospective study, 35 hips were treated in 24 children (one boy and 23 girls, mean age 10.8 ± 2.82 months, range 6-16 months) in the Department of Orthopedic Surgery, Medical Faculty, Harran University, Sanliurfa, Turkey, between April 1997 and February 2009. We evaluated radiologically the patient's hip pre-operatively using the Tonnis grading system and acetabular index. Group 1 included 13 patients aged younger than 12 months (19 hips) and Group 2 included 11 patients aged 12 months or older (16 hips). Clinical and radiographic evaluations were made according to the McKay and Severin's criteria, respectively. Avascular necrosis (AVN) was evaluated according to the Kalamchi and Mac Ewen's classification.

Results: The average follow-up period was 5.6 ± 3.1 years (range, 2-12 years). Five hips (14.2%) required a second procedure. Avascular necrosis was observed in 6 hips (17.1%). Clinical and radiological assessments showed that the outcome was not significantly different between the 2 groups. Furthermore, after this follow up period, the rates of AVN were similar.

Conclusion: Analyzing retrospectively after comparison of this method before and after the age of 12 months, we found no difference between the 2 groups. Children with DDH can be successfully treated by this method up to 16 months.

Saudi Med J 2011; Vol. 32 (9): 901-906

From the Department of Orthopedic Surgery (Erturk, Altay, Isikan), Faculty of Medicine, Harran University Sanliurfa and the Department of Orthopaedic Surgery (Yarimpapuc), 25 Aralik State Hospital, Gaziantep, Turkey.

Received 1st April 2011. Accepted 18th July 2011.

Address correspondence and reprint request to: Dr. Cemil Erturk, Department of Orthopedic Surgery, Faculty of Medicine, Harran University, Yenisehir 63100, Sanliurfa, Turkey. Tel. +90 (532) 2130920. Fax. +90 (414) 3151181. E-mail: erturkc@yahoo.com

The medial approach for the open reduction (MAOR) of developmental dysplasia of the hip (DDH) was introduced by Ludloff in 1908 and reintroduced by Chiari (1957) and Ferguson (1973).^{1,2} However, most surgeons do not prefer this method which is difficult to perform due to the narrow exposure area.¹ In 1979, Weinstein and Ponseti applied this approach more directly anterior to the joint between the pectineus and femoral vein.^{1,3} Here, we used the approach described by Weinstein and Ponseti. To our knowledge, there are few reports in the English literature on medial open reduction performed using the Weinstein-Ponseti approach. In literature, MAOR was used between 2 and 54 months.³⁻⁷ However, there is limited information available on the comparison of MAOR before and after the age of 12 months. In this study, we present our functional and radiographic findings in children treated with medial open reduction. The aim of this paper was to compare the clinical and radiological results of the patients with DDH before and after 12 months of age.

Methods. In this retrospective study, 35 hips were treated with MAOR in 24 children (35 hips) in the Department of Orthopedic Surgery, Medical Faculty, Harran University, Şanlıurfa, Turkey, between April 1997 and February 2009. Written informed consent was obtained from all patients, and approval to use their medical records and re-evaluate each patient was given by the Local Research Ethics Committee. This study was performed according to principles of Helsinki Declaration. Patients who had a neuromuscular or teratological dislocation had been previously excluded. Only typical dislocations were included and a minimum postoperative follow-up period of 2 years was required for inclusion in this study. The sample included one boy and 23 girls and 9 right and 4 left hips; 11 patients were affected bilaterally. The average age of the children at the time of the operation was 10.8 ± 2.82 months (range: 6-16; median: 11 months). Four hips had been treated with an abduction brace; 7 with a Pavlik harness, but 24 had no previous treatment. Preliminary traction was not used in any patient. Open reduction was performed if the hip was irreducible or if the reduction could be maintained only in a safe position. All the patients were managed by the same surgeon. Each patient had a gentle attempt at closed reduction under general anesthesia. When the procedure failed to obtain a stable hip with a closed reduction, this was our indication

for an open reduction. We evaluated radiologically the hips pre-operatively by the Tonnis grading system.⁶ Preoperatively, 6 of the hips were grade IV; 27 were grade III; and 2 were grade II according to the Tonnis grading system. We divided our patients into 2 groups according to the age at which they were operated: Group 1 included 13 patients aged <12 months (19 hips) and Group 2 included 11 patients aged ≥ 12 months (16 hips). Patient data are shown in Table 1.

Surgical technique. We used the interval between the pectineus and iliopsoas, anterior to the pectineus, using the Weinstein-Ponseti approach.³ A 3-4 cm transverse incision was made parallel to and just distal to the crease in the groin. The tendon of the adductor longus was isolated, sectioned at its origin, and allowed to retract. The tissue plane between the pectineus (medially) and femoral sheath (laterally) was developed with blunt dissection. The iliopsoas tendon was visualized, isolated, and divided transversely on the lesser trochanter. We attempted to preserve the branch of the medial femoral circumflex artery that crosses over the antero-medial capsule of the hip joint. The articular capsule was performed axially as the minimal incision from the outer edge of the acetabulum. Then, an additional cut parallel to the acetabular margin and perpendicular to the first cut was made if the capsule was still tight. The ligamentum teres seemed to block reduction because of hypertrophy and was resected. The transverse acetabular ligament was divided to allow a stable reduction, but the limbus was left intact in all cases. The hypertrophic fibrous fatty tissue of the pulvinar was removed with pituitary rongeurs. An intraoperative radiograph was obtained to check the reduction. No patients received blood replacement. Patients with bilateral dislocation had both hips reduced during the same operation. A bilateral hip spica cast was applied with the hip in 100 degrees of flexion, 30 degrees of abduction, and neutral rotation. The quality of reduction was confirmed by single-section computed tomography (CT) at the recent cases. The cast was changed under sedoanesthesia at 6-week intervals with a total duration of cast immobilization of about 3 months. At this time, the patient was fitted for an abduction brace for 3 months and then only at night for an average of 6 months.

Conventional anterior-posterior (AP) pelvis radiograph was acquired immediately after surgery and at 6 weeks and AP pelvis and frog lateral radiographs were at 3, 6, and 12 months. Final clinical and radiological evaluations were performed using the medical records and radiographs prepared or taken at the time of the most recent follow-up visit (Figures 1 & 2). Radiological evaluations were performed by the specialist radiologist (AP). All patients were followed up clinically and radiologically in accordance with the modified McKay

Disclosure. Authors have no conflict of interests, and the work was not supported or funded by any drug company.

Table 1 - Data of the patients.

Case*	Gender	Age at surgery (months)	Follow-up duration years	Grade of Tonnis	McKay's criteria	Results at final visit			Subsequent surgery
						CE angle	Severin's criteria	Type of AVN	
Group 1									
1	F	10	9	2	Good	25	1		
2	F	10	9	3	Poor	0	5		Salter +DVO
3	F	11	8	3	Excellent	35	1		
4	F	7	8	3	Excellent	35	1		
5	F	7	6	3	Excellent	25	1		
(6)	F	7	6	3	Excellent	25	1		
7	F	10	3	3	Excellent	23	1		
8	F	6	5	3	Excellent	30	1		
9	M	8	3	3	Excellent	25	2	2	
(10)	M	8	3	3	Excellent	25	2	2	
11	F	7	3	4	Poor	0	5		Pemberton
(12)	F	7	3	4	Excellent	18	2	1	
13	F	11	3	3	Excellent	22	1	1	
14	F	10	3	4	Excellent	25	1		
(15)	F	10	3	4	Poor	0	4		
16	F	10	2	4	Excellent	35	1		
(17)	F	10	2	4	Poor	0	5		Pemberton
18	F	8	7	3	Excellent	25	1		
(19)	F	8	7	3	Excellent	28	1		
Group 2									
20	F	13	12	3	Excellent	30	1		
21	F	14	12	3	Excellent	32	1		
22	F	12	9	3	Excellent	22	1		
23	F	13	9	4	Excellent	22	1		
(24)	F	13	9	4	Excellent	23	1		
25	F	16	9	3	Good	0	3	1	
(26)	F	16	9	3	Poor	25	5		Pemberton
27	F	13	7	3	Excellent	20	1		
(28)	F	13	7	3	Excellent	25	1		
29	F	12	3	3	Good	25	1	1	
30	F	12	3	2	Excellent	20	1		
31	F	14	6	3	Excellent	30	1		
32	F	15	2	3	Excellent	24	1		
(33)	F	15	2	3	Excellent	22	1		
34	F	12	2	4	Good	16	3		
(35)	F	12	2	4	Good	17	3		

*For patients who had a bilateral dislocation, the second side is indicated by parentheses. CE angle - center-edge angle, AVN - avascular necrosis, DVO - Derotation varus osteotomy

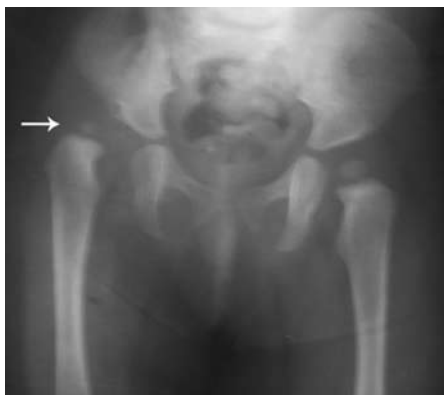

Figure 1 - Right hip dislocation in a girl of 13-months.

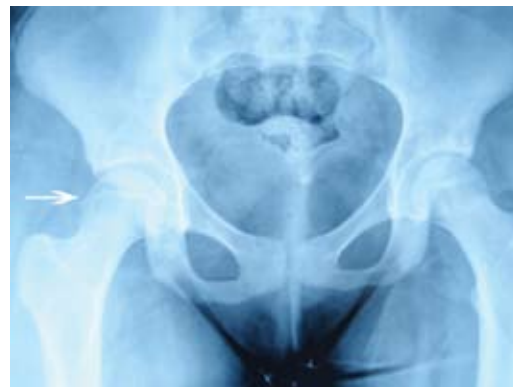


Figure 2 - Twelve years postoperative surgery in follow up. The right acetabulum and femoral head have developed normally with no evidence of avascular necrosis.

criteria⁵ and modified severin classification.¹ The acetabular index (AI) and the center-edge (CE) angle of Wiberg were measured on radiographs.¹ Grade of Avascular necrosis (AVN) in the femoral head was evaluated according to the system of Kalamchi and Mac Ewen.⁸

Statistical analysis. All statistical analyses were conducted using a SPSS Version 11.5 computer program. The Mann-Whitney U test was used to determine differences between the groups. The Fisher's exact test was used to evaluate the non-parametric values between the groups. Excellent and good results were considered as satisfactory, fair and poor as unsatisfactory. Continuity correction was used to determine differences for operated side. The correlation between unsatisfactory radiological results and the high Tonnis grade was evaluated using Kendall rank correlation coefficient. P values <0.05 were considered significant.

Results. We did not encounter any complications related to the operations. The average follow-up period was 5.6 ±3.1 years (range, 2-12; median: 6 years). There was no significant difference in terms of gender, operated side, duration of follow up, preoperative AI and Tonnis grade⁶ between the groups ($p>0,05$). The outcomes of the 2 groups are summarized in Tables 2 & 3. However, there was no significant difference between 2 groups according to Severin's radiographic criteria¹ at final follow-up ($p>0,05$). In addition, there was no significant difference between the 2 groups according to McKay's clinical criteria⁵ at final follow-up ($p>0,05$). In group 1, preoperative mean AI was measured as 40.7° ±4.79 (range, 30°-50°; median: 40°), and in group 2, the preoperative mean AI was measured as 40.3° ±4.26 (range, 35°-45°; median: 40°). In final radiological examinations in group 1, mean AI was observed to fall to 30.2° ±4.76 (range, 20°-35°; median: 30°), and mean improvement as 10.5°. In the final radiological examinations in group 2, mean AI was observed to fall to 31.1° ±3.27 (range, 25°-35°; median: 30°), and

mean improvement was 9.2°. In the final radiological examinations, Wiberg's mean CE angle was measured as 21.1° ±12.0 (range, 0°-35°; median: 25°) in group 1 and 22.0° ±7.36 (range, 0°-32°; median: 22.5°) in group 2. There were no statistical differences between 2 groups with regard to the preoperative, the final follow up AI angle and the last follow up CE angle ($p>0,05$). In total, according to the Kalamachi and MacEwan criteria,⁸ AVN was observed in 6 hips (17.1%). In group 1, AVN was observed in 4 hips (21.5%). Two of them were grade I, 2 were grade II. Whereas, in group 2, AVN was observed in 2 hips (12.5%). Two of them were grade I. No patients with AVN had subsequent surgery. There was an association between the high Tonnis grade and unsatisfactory radiological results. The number of these results was greater in the high Tonnis grade. Kendall's tau_b test was used to determine preoperative dislocation grade ($r=0.378$, $p=0.017$).

Discussion. Ludloff, in 1908, described an anteromedial approach that traversed the area between the adductor longus and the pectineus.¹ Ferguson, in 1973, modified this approach by traversing the interval posterior to the adductor longus.⁹ Both approaches utilize the area between the adductor muscles. Although the anatomic details of the medial approach are easy, the procedure itself can become difficult because the exposed area is narrow and the child is often small, such that a small amount of bleeding from these vessels will make the operation difficult.^{1,9} Hence, we used the Weinstein-Ponseti approach because we believe that the Weinstein-Ponseti approach is a valuable technique that evaluates the exposure of the psoas tendon in a superior manner to that achieved with the standard Ludloff or Ferguson medial approach. The Weinstein-Ponseti approach is more direct than the Ludloff approach and the Ferguson approach, requiring less dissection and providing direct exposure of the iliopsoas tendon. This approach also involves less bleeding.³ The branches of medial femoral circumflex artery and vein can be exposed more easily and are chosen so that the risk of

Table 2 - Clinical results of the 2 groups.

Results	Group 1 n (%)	Group 2
Excellent	14 (73.7)	11 (68.7)
Good	1 (5.3)	4 (25.0)
Fair	0	0
Poor	4 (21.0)	1 (6.3)
Satisfactory*	15 (78.9)	15 (93.7)
Unsatisfactory*	4 (21.1)	1 (6.3)

*There was no significant difference between the 2 groups ($p>0.05$) McKay's clinical criteria⁵

Table 3 - Radiological results of the 2 groups.

Results	Group 1 n (%)	Group 2
Excellent	12 (63.1)	12 (75.0)
Good	3 (15.8)	(
Fair	0	3 (18.75)
Poor	4 (21.0)	1 (6.25)
Satisfactory	15 (78.9)	12 (75.0)
Unsatisfactory	4 (21.1)	4 (25.0)

*There was no significant difference between the 2 groups ($p>0.05$) according to Severin's radiographic criteria.¹

injury is minimal. We did not observe vascular injuries in any case. However, the most important disadvantage of this approach is that being initiated near femoral vessels. Excision of the ligamentum teres and removal of fibrous fatty tissue is controversial. Removal of the ligamentum teres significantly increases exposure and allows deeper reduction of the femoral head.^{1,3} Although some authors have proposed that the ligamentum teres can be excised if hypertrophied, the pulvinar cannot be disturbed.^{10,11} We think that removal of the ligamentum teres significantly increases the degree of exposure and allows a deeper reduction of the femoral head. Therefore, we excised the ligamentum teres in each of our cases and removed the pulvinar from all hips, but we did not resect the limbus in any cases. Two major disadvantages of the medial approach are the risk of AVN and residual subluxation or redislocation.^{3,9,11,12} Avascular necrosis rates of 0-67% have been reported after MAOR.^{1,2,13} The true prevalence is difficult to estimate from the recent reports due to several factors, including various methods of initial treatment and operative approaches, level of dislocation, presence or absence of the femoral ossific nucleus. The different definitions used to describe growth disturbances, inadequate durations of follow-up, and the multifactorial etiology of these disturbances.^{1,2,4,10-12} We found 6 hips (17.1%) with AVN. The definitive number of AVN in this small series remains uncertain, owing to the relatively short follow-up, considering that AVN may become apparent after as long as 10 years. Zamzam et al³ found highly significant the need for acetabuloplasty in children older than 12 months. Therefore, they advocated to delay the operation for a few months in those aged 12-16 months. Additionally, Okano et al⁵ reported the patients treated by the medial approach for DDH at more than 17 months of age had unacceptable results. Sener et al⁴ found 70.6% of hips who were older than 18 months required additional surgery. Our study similar to the report of Sener et al,⁴ but they performed this method in children after 18 months of age. Additionally, they made through a longitudinal incision between adductor longus and gracilis, whereas we performed antero-medial Weinstein-Ponseti approach. Di Mascio et al⁷ reported 8% of hips reduced by the medial approach required subsequent surgery in children between 2 and 11 months. We found residual dysplasia in 5 hips (14.2%). In contrast, Bicimoglu et al⁶ reported that patients between 3 and 18 months of age at the time of operation had 91% acceptable radiographic outcome. We also found 78.9% in group 1 and 93.7% in group 2 yielded satisfactory (excellent or good) clinical results, whereas 78.9% in group 1 and 75.0% in group 2 yielded satisfactory radiological results. Thus, in our series, satisfactory results were

obtained in patients who were older than 12 months, but the number of patients was small. Although, several authors^{3,7,9} suggest MAOR in children younger than 12 months, we found good results in aged 12-16 months. Therefore, we advocate the antero-medial open reduction of the hip as a treatment option in children younger than 16 months with DDH. Baki et al¹² performed a single-stage open reduction through a medial approach combined with an innominate osteotomy to reduce the incidence of residual dysplasia. In their series, no hips required secondary procedures for resubluxation or redislocation. However, most of their cases had low dislocation. Recently, the combined excellent and good results in previous studies that proposed open reduction through the medial approach ranged between 73% and 98%.^{3,11,12} In our series, satisfactory clinical results were obtained in 85.7% of hips, of which 71.4% were excellent. Satisfactory radiological results were seen in 77.1% of hips, of which 68.6% were excellent. Our outcomes are similar to previous studies.^{3,10,11,13} In most studies, unsuccessful results have been obtained with high rates of dislocation and AI of more than 45 degrees in patients.¹⁰ We did not find a correlation between the initial AI and the occurrence of residual dysplasia, but there was a relationship between the high Tonnis grade and unsatisfactory clinical and radiological results in our study.

The limitations of this study include the limited number of cases in both groups, and being retrospective. Prospective randomized controlled trials with larger sample sizes are needed to support our findings.

In summary, we recommend the medial open reduction using the approach described by Weinstein and Ponseti for dislocations in infants under 16 months of age with DDH. We found no difference between before and after the age of 12 months, neither clinically nor radiologically. Our clinical results in both groups were definitely better than our radiological results. This approach is safe, easy to perform and provides the surgeon excellent visualization, all patients ultimately had cosmetically acceptable scars. Therefore, we believe that this method can be used safely up to 16 months. Additionally, larger prospective series, with longer follow-up is mandatory to support these results.

Acknowledgment. *We would like to thank Dr. Ahmet Peker for his assistance in reviewing the radiological evaluations and Dr. Ibrahim Koruk for assisting us in the statistical analyses.*

References

1. Herring JA. Developmental Dysplasia of the Hip. In: Herring JA, editor. Tachdjian's Pediatric Orthopaedics, 4th ed. Vol 1. Philadelphia (PA): WB Saunders; 2008. p. 637 -770.

2. Beaty JH. Congenital and developmental anomalies of the hip and pelvis. In: Canale ST, Beaty JH, editors. Campbell's operative orthopaedics. 11th ed. Philadelphia (PA): Mosby; 2008. p. 1180-1229.
3. Zamzam MM, Khosshal KI, Abak AA, Bakarman KA, AlSiddiky AM, AlZain KO et al. One-stage bilateral open reduction through a medial approach in developmental dysplasia of the hip. *J Bone Joint Surg Br* 2009; 91: 113-118.
4. Sener M, Baki C, Aydin H, Yildiz M, Saruhan S. [The results of open reduction through a medial approach for developmental dysplasia of the hip in children above 18 months of age]. *Acta Orthop Traumatol Turc* 2004; 38: 247-251. Turkish.
5. Okano K, Yamada K, Takahashi K, Enomoto H, Osaki M, Shindo H. Long-term outcome of Ludloff's medial approach for open reduction of developmental dislocation of the hip in relation to the age at operation. *Int Orthop* 2009; 33: 1391-1396.
6. Bicimoglu A, Aguş H, Omeroglu H, Tumer Y. Posteromedial limited surgery in developmental dysplasia of the hip. *Clin Orthop Relat Res* 2008; 466: 847-855.
7. Di Mascio L, Carey-Smith R, Tucker K. Open reduction of developmental hip dysplasia using a medial approach: a review of 24 hips. *Acta Orthop Belg* 2008; 74: 343-348.
8. Kalamchi A, MacEwen GD. Avascular necrosis following treatment of congenital dislocation of the hip. *J Bone Joint Surg Am* 1980; 62: 876-888.
9. Konigsberg DE, Karol LA, Colby S, O'Brien S. Results of medial open reduction of the hip in infants with developmental dislocation of the hip. *J Pediatr Orthop* 2003; 23: 1-9.
10. Tumer Y, Bicimoglu A, Agus H. Surgical treatment of hip dysplasia through the medial approach. *Acta Orthop Traumatol Turc* 2007; 41 Suppl 1: 31-36.
11. Ucar DH, Isiklar ZU, Stanitski CL, Kandemir U, Tumer Y. Open reduction through a medial approach in developmental dislocation of the hip: a follow-up study to skeletal maturity. *J Pediatr Orthop* 2004; 24: 493-500.
12. Baki C, Sener M, Aydin H, Yildiz M, Saruhan S. Single-stage open reduction through a medial approach and innominate osteotomy in developmental dysplasia of the hip. *J Bone Joint Surg Br* 2005; 87: 380-383.
13. Kiely N, Younis U, Day JB, Meadows TM. The ferguson medial approach for open reduction of developmental dysplasia of the hip. A clinical and radiological review of 49 hips. *J Bone Joint Surg Br* 2004; 86: 430-433.

Related topics

Moosa NK, Kumar PT, Mahmoodi SM. Incidence of developmental dysplasia of the hip in Dubai. *Saudi Med J* 2009; 30: 952-955.

Zamzam MM. Congenital osteofibrous dysplasia of the tibia, associated with pseudoarthrosis of the ipsilateral fibula. *Saudi Med J* 2008; 29: 1507-1509.

Gazzaz FB. Molecular testing of human papillomavirus in cervical specimens. *Saudi Med J* 2007; 28: 1810-1818.

Moussa M, Alomran A. Acetabular dysplasia in adult hips of a Saudi population. A possible relation to coxarthrosis. *Saudi Med J* 2007; 28: 1059-1061.