

Successful repair of a contained rupture of mycotic aortic aneurysm in an 8-year-old child using polytetrafluoroethylene graft

Khalid A. Brekeit, FRCS, RACS Vasc (Fel).

ABSTRACT

نحن نسجل حالة طفل بعمر ثماني سنوات أصيب بتمزق في الشريان الأبهر البطني الجرثومي المتكيس نتيجة لإصابته ببكتيريا المكورات العنقودية السلبية المخثرة وتم ترميمه بنجاح باستخدام توصيلة اصطناعية من نوع الاثيلين الفلوري الرباعي جورتكس بين الشريان الأورطي البطني والشريانان الحرقفيان. لقد كان المريض يعاني من التهاب الشغاف القلبي ببكتيريا المكورات العنقودية السلبية المخثرة والتي أدت إلى تلف الصمام المايترالي والذي تم ترميمه بواسطة جراحة القلب عن طريق استبدال الصمام بصمام اصطناعي ميكانيكي. في مرحلة ما بعد جراحة القلب كان يشتكي المريض من آلام في البطن والظهر بشكل متقطع. حتى ازدادت الأعراض وجاء الألم بشكل مفاجئ وقوي. أجري للمريض في وقتها أشعة صوتية والتي أظهرت إصابة بتكيس بالشريان الأبهر البطني مما استدعى عمل أشعة مقطعية بالصبغة الملونة والتي أكدت إصابة الشريان الأبهر البطني بالتكيس مع تمزق خلفي متضمن كبير. مما استدعى أخذ المريض لغرفة العمليات على الفور وأجريت له عملية ترميم بإزالة أنسجة الشريان الأبهر البطني التالفة والاستعاضة عنها بشريان اصطناعي جورتكس (PTFE) مع تغطيته بأنسجة الأومنتم. لقد تحمل المريض العملية بشكل جيد وأعطي مضادات حيوية لعلاج جرثومة بكتيريا المكورات العنقودية السلبية والتي أثبتت دراسة مزرعة للأنسجة المأخوذة من جدار الشريان الأبهر البطني وجودها. إن وجود العلاقة الوثيقة التي تربط بين التهاب الشغاف القلبي وإصابة الشريان الأبهر (الأورطي) البطني بتكيس أم الدم الجرثومي يجعله من الأولويات في التشخيص المرضي عند إصابة المريض به، وجعله بالذهن عند معاناة الطفل المصاب به واحتمالية حدوث تكيس بالشريان الأبهر البطني يؤدي لسرعة اتخاذ الإجراء العلاجي المناسب للمحافظة على حياة المريض. ووجد أنه باستخدام الشريان الاصطناعي الجورتكس (PTFE) ولفه بالأومنتم في مثل هذه الحالات الطارئة حيث لا يوجد بديل طبيعي (بيولوجي) ممكن أن يكون آمن وأن يسعف حياة المريض.

This study reports on a contained rupture of mycotic abdominal aortic aneurysm secondary to coagulase

negative staph successfully repaired with aorto biliary polytetrafluoroethylene (PTFE) Gor-Tex graft. An 8-year-old Saudi male patient was found to have infective endocarditis by coagulase negative staph with mitral valve (MV) leaflet damage, which was repaired with mechanical MV. Post-cardiac surgery, he complained of intermittent abdominal and back pain, until he became more symptomatic and had a sudden abdominal pain. Ultrasound showed abdominal aortic aneurysm (AAA), as well as the CT scan showed contained posterior rupture of AAA. He was operated immediately and the aorta was repaired with bifurcated PTFE Gor-Tex graft. He tolerated the operation, and he was given antibiotic coverage according to sensitivity. Tissue culture of the aorta confirmed coagulase negative staph. The strong relation between infective endocarditis and mycotic aneurysm should make a high index of suspicion of developing abdominal aortic aneurysm in children. Utilizing the PTFE graft with an omental patch is safe and life saving.

Saudi Med J 2012; Vol. 33 (7): 787-790

From the Department of Surgery, College of Medicine, Al-Imam University, Riyadh, Kingdom of Saudi Arabia.

Received 1st November 2011. Accepted 20th May 2012

Address correspondence and reprint request to: Assistant Professor Khalid Abdulrahman Brekeit, Consultant Vascular Surgeon, Department of Surgery, College of Medicine, Al-Imam University, 7544 Othman Bin Afan Road, AlNada, Riyadh 4233-13317, Kingdom of Saudi Arabia. Tel. 966 (1) 2037134. E-mail: brekeit@gmail.com

Disclosure. The author declares no conflict of interests, and the work was not supported or funded by any drug company.

Abdominal aortic aneurysm (AAA) is an extremely rare disease in children. Different etiologies can lead to aneurysmal dilatation of the aorta like mycotic vasculitis (for example; Takayasu's arteritis), connective tissue diseases (for example; Marfan's syndrome, Ehlers-Danlos syndrome, tuberous sclerosis), and traumatic false aneurysms.¹ In pediatric population, mycotic aneurysm formation usually arises from vascular injury due to invasive arterial catheters, with concomitant bacterial sepsis. Bacterial infection is formally considered to be one of the common causes of aortic aneurysm in children secondary to infected endocarditis,² which became very rare after development of the antibiotics. William Osler coined the phrase mycotic aneurysm in 1885, to denote a vascular aneurysm associated with a bacterial infection, which later on became a specific nomination for infected aortic aneurysm secondary to infective endocarditis.³ Our aim in this study is to report a rare case of ruptured mycotic aortic aneurysm in a child secondary to infective endocarditis who survived the emergency laparotomy and abdominal aortic repair with polytetrafluoroethylene (PTFE) Gor-Tex graft.

Case Report. An 8-year-old Saudi male patient presented with infective endocarditis of the mitral valve (MV), and history of Stevens-Johnson syndrome following upper respiratory tract infections (URTI). He was operated by mechanical MV replacement for a damaged MV leaflet following infective endocarditis, one month and 20 days prior to AAA rupture. During the post-operative period, he received 6 weeks of antibiotic for coagulase negative *Staphylococcus aureus* isolated from a valve tissue culture. He was referred previously for vascular surgery for the presence of left sided brachial artery pseudo-aneurysm, and was planned to have surgical repair after being cured from infective endocarditis and complete recovery of cardiac status, although he ran a relatively smooth post-cardiac surgery course, however, he was complaining of infrequent attacks of abdominal and back pain. Just before the surgical repair of brachial artery, he had severe bouts of sudden abdominal pain with vomiting. Ultrasound showed AAA confirmed by CT scan, which showed contained posterior ruptured of AAA (Figures 1, 2, and 3). The patient was taken for surgical repair immediately (Figure 4), and midline laparotomy was performed. The small bowel was found bluish in color due to the huge aneurysm compression, then it was shifted to the right side of the abdomen, and the aorta was dissected until it was controlled proximally, and both common iliac arteries were dissected with difficulty, as they were stuck to the wall of the aneurysm until both were controlled,

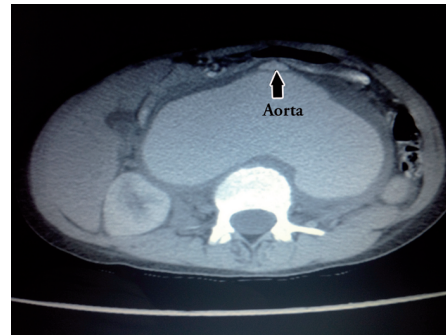


Figure 1 - Abdominal aorta (arrow) with posterior contained rupture.

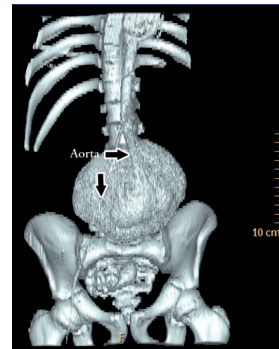


Figure 2 - Aorta (arrows) with contained rupture in 3-dimensional image.

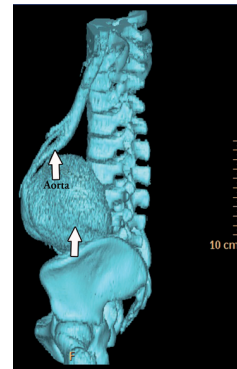


Figure 3 - The aorta pushed away from the vertebra (arrows).

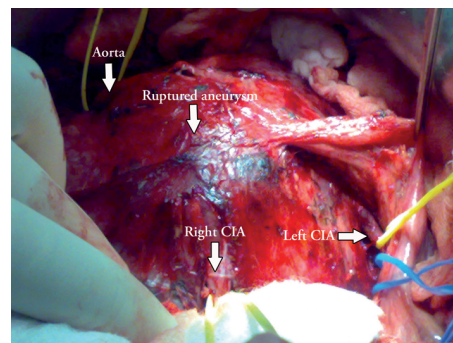


Figure 4 - Laparotomy showing the huge contained ruptured aneurysm, abdominal aorta, and both common iliac arteries (CIA) (arrows).

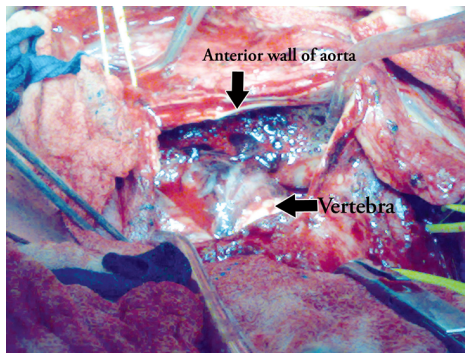


Figure 5 - Posterior wall of the aorta completely disrupted with vertebral body exposed.

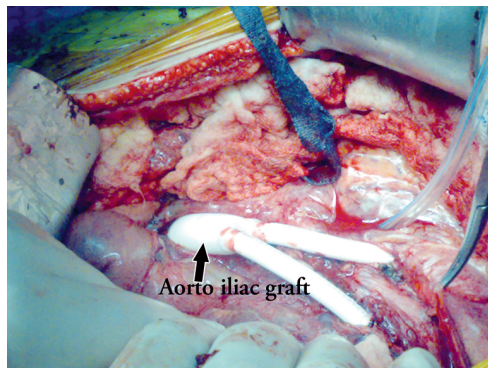


Figure 6 - The aorto-bi-iliac Gor-Tex graft (arrow) with drain at the posterior wall after its closure.

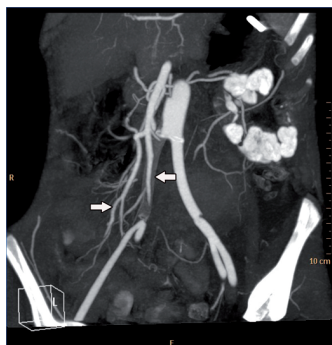


Figure 7 - Post-operation CT-angio, showing the occluded right limb of the graft (arrows) with large collateral filling of the right common iliac artery, external iliac artery, and internal iliac artery.

and then the aorta was excised (Figure 5) until the body of lumbar vertebra was exposed. The aorta was repaired with bifurcated 14-7 Gor-Tex PTFE graft and wrapped with momentum patch, and the posterior abdominal wall was closed to cover the exposed vertebral body, leaving a drain at the posterior abdominal wall (Figure 6). The patient tolerated the operation and was given antibiotic coverage according to sensitivity. Again, tissue

culture of the aorta confirmed coagulase negative staph. First day post-operation, he developed hypotension associated with absent peripheral pulses and coldness of lower limb extremities. Clinical examination revealed weak femoral pulses, the left femoral pulse was palpable, but the rest was detected only by Doppler machine, which was triphasic at left limb and monophasic at right side. Patient's echo showed impaired ventricular function with ejection factor of less than 10%. He was in cardiogenic shock and treated as such. After the patient improved from the shock-state, he showed good peripheral pulses at left femoral artery but weak right side. A CT-angio was performed on the third post-operative day, which showed completely occluded right limb of the graft with very good collateral filling the distal part to common iliac artery (CIA), external iliac artery (EIA), and internal iliac artery (IIA) (Figure 7).

As the patient's cardiac status did not allow for further intervention, he was treated conservatively with supportive measures and anti-coagulant. The patient's clinical condition improved over time, maintained adequate blood supply on both sides, and had palpable distal right femoral pulses. He recovered very well, and discharged home in fairly good condition.

Discussion. The risk of developing infective endocarditis has a relation to a pre-existing cardiac lesion.⁴ In our patient, the infective endocarditis affected the MV and destroyed its leaflet, which required replacement with mechanical valves. The infected valves lead to the spread of septic micro emboli, which implanted into the abdominal aortic wall, and lead to development of mycotic aortic aneurysm.

Mycotic aneurysm of the aorta is a life threatening disease, and the mortality become higher when it ruptures. The mortality is very high not only because of higher rupture rate but also due to sepsis.⁵ In the literature, only few cases had been reported to have survived the disease. The first survival case reported and successfully managed was reported on January 1989 by Hollingworth et al⁶ and Mohyuddin and Karjoo⁷. Abdominal aortic aneurysm is very rare in children, and can be missed easily. A higher suspicion is required to prevent inadvertent rupture. So, any patient with history of rheumatic heart disease, infected endocarditis, and staphylococcal sepsis should be considered as a higher risk patient for aortic mycotic aneurysm.³

The ultrasound is a very useful imaging modality for diagnosing the AAA in children. However, a CT-angiogram is required to accurately identify the size and extent of the aneurysm, it may predict risk of rupture, and can detect the sign of leak. In addition,

it may identify a sign of infection or associated abscess. Magnetic resonance angiography is rapidly developing as an additional 3- and 4-dimensional method to assess aortic aneurysmal disease.⁸ Even MRI is emerging as the diagnostic test of choice for the evaluation of vascular anomalies in children. However, patients with pacemakers and certain ferromagnetic appliances cannot be studied. In our patient, MRI could not be carried out for unforeseen reasons. Ultrasound carried out at the time of severe abdominal pain detected hugely dilated aneurysm, but the CT scan demonstrated the rupture and the exact site and size of the aneurysm. Esper et al⁹ reported the first successful repair of mycotic aneurysm using Gore-Tex graft in a newborn, as well they demonstrate that blood supply to his left leg came from the large collateral from the right iliac artery. In our patient, due to the emergency situation and the only available graft was the Gore-Tex bifurcated graft, it was successfully implanted replacing the distal aorta and aorto-iliac bifurcation, even though the right limb of the graft occluded after an episode of cardiogenic shock in the immediate post-operative day. The flow to the right limb improved with general improvement of cardiac condition, but largely through development of good size collaterals as demonstrated in the post-operative CT scan. No further intervention was required at that time. The graft was wrapped with omentum to prevent direct contact between the graft, and the bowel to prevent possibility of developing aortoenteric fistula, and to help protect the graft from the possibility of potentially infected surrounding tissue.

In conclusion, the strong relation between infective endocarditis and developing mycotic aneurysm should make a high index of suspicion of developing AAA in

children. This will prompt the diagnosis and the operative treatment at the proper time. Although ultrasound is a very good tool for initial diagnosis, other modalities like MRI or CT scan is mandatory for planning the operative treatment. Using the PTFE graft with omentum patch is safe and life saving. Collateral at iliac artery area are well-developed making the intervention to be delayed until the required time, or indicated symptoms.

References

1. Millar AJ, Gilbert RD, Brown RA, Immelman EJ, Burkimsher DA, Cywes S. Abdominal aortic aneurysms in children. *J Pediatr Surg* 1996; 31: 1624-1628.
2. Bergsland J, Kawaguchi A, Roland JM, Pieroni DR, Subramaniam S. Mycotic aortic aneurysm in children. *Ann Thorac Surg* 1984; 37: 314-318.
3. Herman TE, Siegel MJ. Mycotic pseudoaneurysm of abdominal aorta in premature infant. *J Perinatol* 2001; 21: 410-411.
4. Hess J, Bink-Boelkens MTH, Dankert J. Mycotic aneurysm at site of formerly ligated ductus arteriosus caused by infective endocarditis. *Br Heart J* 1982; 47: 103-105.
5. Chen IM, Chang HH, Hsu CP, Lai ST, Shih CC. Ten-Year experience with surgical repair of mycotic aortic aneurysms. *J Chin Med Assoc* 2005; 68: 265-271.
6. Hollingworth J, Palmer KS, Simms MH. Ruptured mycotic aneurysm of the abdominal aorta in childhood. *Eur J Vasc Surg* 1992; 6: 665-667.
7. Mohyuddin Z, Karjoo M. Successful management of ruptured mycotic abdominal aortic aneurysm in a child. *Int Surg* 1989; 74: 61-63.
8. Saloner D, van Tyen R, Anderson CM, Caputo GR. (2007) Magnetic Resonance Imaging. In: White RA, Hollier LH, editors. *Vascular Surgery: Basic Science and Clinical Correlations*. 2nd ed. Massachusetts (USA): Blackwell Publishing; 2007. p. 369-380.
9. Esper E, Krabill KA, St Cyr JA, Patton C, Foker JE. Repair of multiple mycotic aortic aneurysms in a newborn. *J Pediatr Surgery* 1993; 28:1553-1556.

Related Articles

Brekeit KA, Baig MA, Al-Massod AA, Dahduli SA. Management of infected abdominal aortic aneurysm associated with vertebral destruction due to chronic leak. *Saudi Med J* 2010; 31: 1371-1374.

Liu G, Huang Y, Lu XW, Lu M, Huang XT, Li WM, et al. Optimization of the model of abdominal aortic aneurysm by co-incubation of calcium chloride and collagenase in rats. *Saudi Med J* 2009; 30: 1049-1053.

Parvizi R, Maghamipour N, Safaei N, Hassanzadeh S. Survey of operative outcome for aortic dissection. *Saudi Med J* 2007; 28: 752-754.