Clinical application of entire gastrointestinal barium meal combined with multi-temporal abdominal films in patients with intestinal neuronal dysplasia type B

Xiao-Yun Li, MD, PhD, Xiao-Gang Li, MD, PhD, Ming-Guo Du, MD, PhD, Zhi-Dan Chen, MD, PhD, Zheng-Gui Tao, MD, PhD, Xiao-Feng Liao, MD, PhD.

ABSTRACT

الأهداف: دراسة تجربتنا وتقييم إجراء وجبة باريوم المعدية المعوية كاملة بالاشتراك مع شريط تصويري للبطن على فترات متعددة عند تشخيص المرضى الذين يعانون من خلل عصيوني معوي نوع B (IND type B).

الطريقة: أجريت هذه الدراسة خلال الفترة من يوليو م2007 إلى اكتوبر 2012م, اشتملت الدراسة على 36 مريض يعانون من أعراض الامساك منذ فترة طويلة في قسم الجراحة العامة، المستشفى المركزي اكسيانجيانج، مقاطعة هوبي،الصين. خضعوا جميعا لاختبارات حقنة الباريوم وقياس الضغط الشرجي المستقيمي وتم الاشباه INDنوع B وتم اثبات ذلك بتحديد الغشاء المخاطي استيل كولينسترا. كما أتم جميعهم وجبة الباريوم المعدية المعوية كاملة مع الشريط التصويري للبطن على فترات متعددة أخذت بعدها النتائج وتم تحليلها استرجاعيا.

النتائج: بعد اتمام وجبة الباريوم المعدية المعوية والشريط التصويري للبطن على فترات متعددة تم تشخيص 30 حالة من أصل 36 حالة بالأمراض العصبونية المعوية. وبعد ذلك تم علاجهم بالجراحة المناسبة. التشخيص المرضي التالي للجراحة كان IND (type B)، بينما لم يكن التشخيص واضح في المرضى الستة مرضى الآخرين في هذه المجموعة بعد الاختبار وتم علاجهم بطريقة معالجة تحفظية.

خاتمة: وجبة الباريوم المعوية الكاملة بالاشتراك مع الشريط التصويري للبطن على فترات متعددة كان لها نتيجة ايجابية في التمكن من اختبار قدرات النقل المعدية المعوية وايجاد تغيرات فيزيولوجية و مرضية في وقت واحد. وهذا يعطي دليل هام عند تشخيص المرضى المصابين بالخلل العصبوني المعوي.

Objectives: To report and evaluate the application of entire gastrointestinal barium meal combined with multi-temporal abdominal films in the diagnosis of patients with intestinal neuronal dysplasia type B (IND type B).

Methods: Thirty-six patients with symptoms of long-standing constipation were enrolled in this study. The study took place at the Department of General Surgery, Xiangyang Central Hospital, Hubei Province, China from July 2007 to October 2012. All of them had already been subjected to barium enema and anorectal manometry and were suspected to be IND type B, but were not confirmed by mucous membrane acetylcholinesterase determination. All underwent entire gastrointestinal barium meal combined with multi-temporal abdominal films. The data was collected and then analyzed retrospectively.

Results: After entire gastrointestinal barium meal combined with multi-temporal abdominal films, 30 out of 36 cases in this group were diagnosed with intestinal neuronal diseases, and then treated with appropriate surgical treatment. The postoperative pathological diagnosis was IND type B. The other 6 patients in this group still could not be diagnosed explicitly after the test; thus, we treated them with conservative treatment.

Conclusion: Entire gastrointestinal barium meal combined with multi-temporal abdominal films has the advantage of being able to test the gastrointestinal transfer capabilities, and to find physiological and pathological changes simultaneously. It could provide important proof for the diagnosis of patients with intestinal neuronal dysplasia type B.

Saudi Med J 2013; Vol. 34 (1): 46-53

From the Department of General Surgery, Xiangyang Central Hospital, Hubei Province, China.

Received 22nd October 2012. Accepted 27th November 2012.

Address correspondence and reprint request to: Dr. Ming-Guo Du, Department of General Surgery, Xiangyang Central Hospital, Hubei Province, China. Tel. +86 (710) 3525837. Fax. +86 (710) 3512850. E-mail: avenxy@gmail.com

Intestinal neuronal dysplasia (IND) is a disease of the sub-mucosal plexus of the intestine manifesting chronic intestinal obstruction or severe chronic constipation and clinically resembles Hirschsprung disease (HD), despite the presence of ganglion cells in rectal suction biopsies.[1] The histological characteristics are hyperganglionosis, giant ganglia, and ectopic ganglion cells. Intestinal neuronal dysplasia used to be named Hirschsprung disease allied disorder (HDAD), HD related disease, pseudo-HD, special forms of HD, HD like-disease and so on.[2] In 1995, Dr. Scharli and Dr. Meier-Ruge drew the standard terminology for abnormal distribution of intestinal neuronal dysplasia and renamed it IND.[3] This can be divided into 2 types. In this paper, we mainly discuss the diagnosis of patients with IND type B, including HD, HDAD, and HD complicated with HDAD. It can be found at the ages of 6 months to 6 years old or later, has the characteristics of chronic constipation and gradually developed megacolon.[4] Whether IND is a congenital malformation, or an acquired secondary condition related to some gastrointestinal problem has not been very clear until recently.[5] The treatment of it has no unified concept, but in most intestinal neuronal dysplasia cases, conservative treatments such as laxatives and enema are not sufficient; most of the patients require surgical treatments.[6] There are various surgical methods for IND, and the resection scope ranges from internal sphincter myectomy to total or subtotal colectomy, resection of the affected segment has been the key point for successful treatment.[7] Therefore, a confirmative diagnosis and clear scope of lesion are very important in designing the operative plan. The ultimate clinical diagnosis of IND type B should be the rectal suction biopsies display the presence of ganglion cells as well as normal acetylcholinesterase activity.[8] However, for many patients who are highly suspected with IND, but rectal biopsy does not confirm the diagnosis, it is very difficult for them to choose proper treatment methods.[9] Entire gastrointestinal barium meal is an effective method for diagnosis in small intestine diseases,[10] and has not been previously reported in the diagnosis of IND. Entire gastrointestinal barium meal can reflect the gastrointestinal transfer capabilities, and combined with multi-temporal abdominal films, the time and the place of barium detentions in the gastrointestinal could be found. It can test the gastrointestinal transfer capability, and find physiological and pathological changes simultaneously. In this paper, we report our experience with using this method in the diagnosis of patients with symptoms of long-standing constipation, highly suspected to be HD or HDAD but were not confirmed by rectal biopsy and mucous membrane acetylcholinesterase determination.

Disclosure. Authors have no conflict of interests, and the work was not supported or funded by any drug company.

Methods. This is a retrospective study designed to investigate the clinical value of entire gastrointestinal barium meal combined with multi-temporal abdominal films in patients with intestinal neuronal dysplasia type B. Thirty-six consecutive patients with long-standing constipation at the Department of General Surgery, Xiangyang Central Hospital, Hubei Province, China between July 2007 and October 2012 were included in this study. The experiment was performed according to the Principles of the Helsinki Declaration and under the ethical approval by the Ethical Committee of Xiangyang Central Hospital.

Patients with symptoms of long-standing constipation and previously subjected to tests such as barium enema, fiber endoscopic or anorectal manometry, and were suspected to be IND type B, but not confirmed by rectal biopsy and mucous membrane acetylcholinesterase determination were included in the study. Patients definitely diagnosed with IND type B, or complicated with severe cardiopulmonary disease were excluded from the study. Demographic characteristics of patients in our series included a median age of 10 years (range = 2.67-55 years). The male to female ratio was 24:12. There were 17 cases whose age ranged from 2 years and 8 months to 6 years; 9 cases whose age ranged from >6 to 14 years, and 10 cases whose age ranged from >14 to 55 years. All patients had the clinical symptoms of long-standing severe constipation, 14 cases had been diagnosed with intestinal obstruction, and there were no symptoms of bloody stool in this group. Seven cases had been subjected to surgical treatments for the diagnosis of intestinal obstruction, redundant colon or HD, but severe constipation was still existed. Before undergoing entire gastrointestinal barium meal combined with multi-temporal abdominal films, all the patients in this group were subjected to barium enema, fiber endoscopic, or anorectal manometry. The results showed suspected HD or HDAD, but rectal biopsy and mucous membrane acetylcholinesterase determination did not confirm the diagnosis.

Protocol for entire gastrointestinal barium meal combined with multi-temporal abdominal films. Before examination, the patients were told to follow a normal diet, the gastrointestinal motility medicine and laxatives

were stopped, and all methods of manual assisted defecation including enema were also stopped. After an effective defecation, entire gastrointestinal barium meal combined with multi-temporal abdominal films was performed. For the patients whose age were ≥18 years, 200 grams of barium paste (Shandong Pharmaceutical Company, Shandong, China) was administered. One hundred grams of barium paste was administered to the patients whose age was ≥10 years, but younger than 18 years, and 75 grams of barium paste was administered to the patients whose age was <10 years. Patients who were too young to be administered barium paste via the oral route should be placed gastric tube. Multi-temporal abdominal films were performed at 6 hours, 12 hours, 24 hours, 48 hours, and 72 hours after barium meal. The morphology of paste presenting when it stayed in the intestine was observed under x-ray fluoroscopy, the time when paste entered into the small intestine and various colon segments via the stomach was recorded. When barium paste moved into the recta, an anorectal lateral film was taken. The patients were told to record the time when the barium was first evacuated and last evacuated.

Judgment of outcomes and statistics. The time when the barium paste arrived at the terminal ileum and cecum, ascending colon and transverse colon, as well as how long the barium stayed in the descending and sigmoid colon and rectum of each patient was recorded separately. Diagnosis on the outcomes was reached by consensus of 2 radiologists and 2 general surgeries in accordance with the films. Prolonged retention time of barium in any segment of the intestine, or the findings of backward motion of barium, shrinking, and morphological changes of the intestine (such as the value of rectal diameter/sigmoid colon diameters in frontal examination) was the baseline for suspicious lesions. This indicated that this segment of intestine or beyond this segment chould be the lesion.

Statistical analysis was performed by the Statistical Pacakge for Social Sciences System Version 12.0 (SPSS Inc., Chicago, IL, USA). Outcomes of x-ray and pathological examination were compared by correlation and regression analysis. Statistical significance was calculated at a *p*-value of <0.05.

Results. Thirty out of 36 cases in this group were found with the phenomenon of prolonged retention time of barium in any segment of the intestine, or backward motion of barium, shrinking and morphological changes of intestine, and this segment of intestine or beyond this segment was considered suspicious for lesions. All the 30 patients underwent surgical treatment based on the above findings, and all of them recovered smoothly; the symptoms of constipation improved significantly, as confirmed by one month to 5 years follow-up. The patients were divided into 8 groups according to their postoperative pathological examination. Group A: common type HD, Group B: short-type HD, Group C: long-type HD, Group D: total colon HD, Group E: total digestive tract HD complicated with HDAD, Group F: total colon jumping-type HD complicated with HDAD, Group G: descending and sigmoid colon HD, and Group H: common HD complicated with HDAD. Correlation and regression analysis indicated that, for patients who were subjected to surgical treatment, there was a positive correlation between pathological type and positive outcomes of entire gastrointestinal barium meal combined with multi-temporal abdominal films ($p<0.01$, 95% confidence interval was 0.865 versus 0.237, **Table 1**). For the other 6 cases, there was no prolonged retention time of barium in any segment of the intestine, or backward motion of barium, shrinking,

Table 1 - Transmission time for each segment of the intestine in 36 cases with a suspected diagnosis of intestinal neuronal dysplasia (IND) type B (arrival and retention time, hours).

Classification	Number of cases	Transmission time				
		Ileocecus	Ascending colon	Transverse colon	Descending and sigmoid colon	Rectum
A	13	<6	<6	<24 (retention >24)	>24	>48
B	6	<6	<6	<24 (retention <24)	>24	>48
C	2	<6	<6	<24 (retention >48)	>48	>72
D	1	<6 (retention >24)	<24 (retention >48)	<24 (retention >48)	>48	>72
E	1	<6 (retention >24)	<24 (retention >48)	<24 (retention >48)	>48	>72
F	1	< 6	<24 (retention >48)	<24 (retention >48)	>48	>72
G	5	< 6	<6	<24	>48	<24
H	1	< 6	<6	<24	>48	>48
Undiagnosed	6	< 6	<6	<24	<24	<48
Correlation coefficient		0.494	0.494	0.930	-0.075	0.910
P-value		0.002	0.002	0.000	0.665	0.000

The times in this table were recorded continuously from barium meal adminsitrations. In the first column, A - common type Hirschsprung disease (HD), B - short-type HD, C - long-type HD, D - total colon HD, E - total digestive tract HD complicated with Hirschsprung disease allied disorder (HDAD), F - total colon jumping-type HD complicated with HDAD, G - descending and sigmoid colon HD, H - common HD complicated with HDAD. For the 30 patients who were subjected to surgical treatment and the final diagnoses were HD, HDAD or HD complicated with HDAD, there was a positive correlation between pathological type and positive outcomes of entire gastrointestinal barium meal combined with multi-temporal abdominal films

Figure 1 - Entire gastrointestinal barium meal of a case of jumping-type Hirschsprung disease complicated with Hirschsprung disease allied disorder in total colon. The barium arrived at the ascending colon 6 hours after meal administration, but was detained in the total colon 48 hours after meal, especially in the left hemicolon.

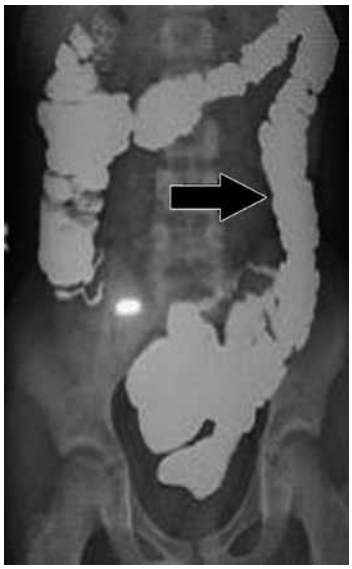

Figure 2 - Entire gastrointestinal barium meal of case one. Six hours after meal administration, the barium was distributed symmetrically in the total colon and upper part of the recta.

and morphological changes of intestine; hence, the diagnosis of HD or HDAD was eliminated. They were treated with conservative treatment and were followed-up from 1-5 years and the symptoms improved significantly. The risks related to surgical treatment and complications were avoided. The findings on the abnormal morphological changes of the intestine and

Figure 3 - Entire gastrointestinal barium meal of case one. Twelve hours after meal administration, most of the barium moved into the left colon and recta.

retention of barium in a section for more than 24 hours were considered valuable (**Figure 1**). The examination provides an important reference for diagnosis and choice of treatment for HD and HDAD. Eight cases of redundant transverse and sigmoid colon were found in this group. We found one case of HD complicated with HDAD in total colon and one case of the so called "jumping type" of HD complicated with HDAD in total colon. In these cases, extreme expansions of the terminal ileum observed except retention of barium in the corresponding section. Another case in this group was HDAD in the total digestive tract complicated with achalasia and superior mesenteric artery syndrome. This patient underwent side-to-side gastrojejunostomy and total colectomy and recovered smoothly.

Typical cases report. A 6-year-old boy in this group who had symptoms of severe constipation was found to have an atypical stenosis of the distal rectum when using barium enema, and anorectal manometry showed that the anal resting pressure was a little higher than normal. The suspected diagnosis was HDAD, but rectal biopsy and mucous membrane acetylcholinesterase determination could not confirm this. Conservative treatment including administrated of gastrointestinal motility medicine and lustramentum had been given for more than one year, and the symptoms of severe constipation still existed. It was very difficult to make a decision whether or not to perform a surgical treatment for the boy. He underwent the test of entire gastrointestinal barium meal combined with multi-temporal abdominal films. After 6 hours of meal, the barium was distributed symmetrically in the total

Figure 4 - Entire gastrointestinal barium meal of case one. Twenty-four hours after meal administration, barium returned to the right colon and was distributed symmetrically in the entire colon and upper part of the recta again.

Figure 5 - Entire gastrointestinal barium meal of case one. Forty-eight hours after meal administration, the barium was still retained in the redundant sigmoid colon and upper rectum.

colon and upper part of the rectum. After 12 hours, most of the barium had moved into the left colon and recta, but returned to the right colon and distributed symmetrically in the entire colon and upper part of the recta again due to obstruction of the sigmoid colon and upper rectum. After 48 hours of meal administration of the barium was still retained in the redundant sigmoid colon and upper rectum (**Figures 2-5**). Therefore, he was diagnosed with HDAD based on the above finding and he underwent laparoscopy assisted radical drag-out surgery via the anal opening route. Postoperative pathological examination confirmed the diagnosis of HDAD. The boy was followed up for 3 years, and the symptoms improved significantly. The time difference for barium staying in the sigmoid colon and the upper rectum between the methods of ordinary barium enema and entire gastrointestinal barium meal was 24 hours.

Another case was a 6-years-old boy with severe constipation from 2 years old, and defecation could only be maintained by saline enema. When he was 4 years old, he visited a hospital in China and was tested by barium enema, anorectal manometry, and mucous membrane acetylcholinesterase determination. The results were normal. However, their symptoms were so severe that he had to undergo surgical treatment. Exploratory laparotomy was performed and terminal ileum expansion was the only pathological finding. Terminal ileum and ascending colon side-to-side anastomosis was performed based on the diagnosis of ileocecal valve stenosis. Nevertheless, after operation, the symptoms of constipation and abdominal distension became more serious, even saline enema could not maintain normal defecation. Finally, he presented to our hospital, we performed gastrointestinal barium meal combined with multi-temporal abdominal films, and barium was found in an extremely dilated terminal ileum after 6 hours of barium meal, and narrow colon and recta 24 hours after barium meal. After 72 hours of meal, the barium was still retained in the colon and recta. He was diagnosed with HDAD in the total colon based on the above findings and underwent total colectomy and ileal- lower rectum end-to-end anastomosis (so called "heart shaped anastomosis"). Pathological examination confirmed the diagnosis of HDAD in the total colon. The symptoms of constipation and abdominal distention improved significantly after 2 years follow-up.

Discussion. Regardless of HD, HDAD or HD complicated with HDAD, if unusual constipation of IND involves the entire alimentary tract or so called "diffuse type", it is very difficult to diagnose it and choose the proper treatment category.[11] For patients with this kind of constipation, the definition of when barium arrives and how long it retains in the ileocecus

is the key point. To take the movement of the colon into account (peristalsis, sectional advance, bags advance, group advance),[12] barium paste would be a better reagent for the test because it is closer to chyme or turd. In normal cases, barium paste can be found in the ileocecus 1.5-6 hours after barium meal, in fewer cases more than 8 hours; it can reach the hepatic flexure of colon in 3-6 hours, and 6-9 hours in splenic flexure of colon (in some case it can reach the sigmoid colon and rectum in 6 hours after meal). Most of the barium will be defecated from the colon within 24 hours after meal.[13] If prolonged transmission time or double time of barium retention in a segment, or abnormal intestinal morphology was found, this section of intestine would be suspicious lesion.[14]

Based on the theories listed above, the entire gastrointestinal barium meal combined with multi-temporal abdominal films would be a better method for the patients who cannot be definitely diagnosed with IND by existing methods. Short-type and common-type HD has the characteristics of delayed meconium expulsion when patients are born; symptoms of constipation and ventosity could be alleviated by anal dilatation or local medication.[15] Typical stenotic segments, transitional segments, and dilated segments could easily be found via examination with barium enema. An efficient outcome of treatment can be achieved by resection of proximal dilatation and hypertrophy of the intestine or by pass surgery.[16] However, for patients complicated with HDAD, this kind of strategy will be insufficient. All the segments of the intestine involving barium retention for a long time or not easily evacuated should be excised.[17] Carefully reviewed of the processes of diagnosis and treatment of the 2 typical cases listed above, and we found that the entire gastrointestinal barium meal combined with multi-temporal abdominal films could precisely indicate the location of lesion, and provide an important basis for the selection of operation approach. Compared with barium enema, it also had the advantage of avoiding stimulation to colon not by administration of enemata and lustramentum. It can be said that the entire gastrointestinal barium meal combined with multi-temporal abdominal films would be a better method for detection of the location of lesions for patients with IND B type. When the lesions of intestinal segment cannot be determined, entire gastrointestinal barium meal combined with multi-temporal abdominal films should be performed to exclude the diagnosis of HDAD, and to provide the basis for the projection and selection of operation strategy. At the same time, it can also decrease the possibility of insufficient curative effect and relapse, and decrease the risk of several operations.

Compared with the existing method of oral barium strip colonic transit study,[18] entire gastrointestinal barium meal combined with multi-temporal abdominal films also has obvious advantages. A 19-year-old male patient in this group with long-standing severe constipation underwent oral barium strip colonic transit study. The result showed 20 barium strips mainly gathered from the left side of the abdomen (the region of descending and sigmoid colon) after 48 hours of test, and did not indicate clearly the precise lesion. While the entire gastrointestinal barium meal combined with multi-temporal abdominal films clearly indicated the lesion was beyond the transverse colon by the films at 6, 12, 24, and 48 hours after barium meal. The changes of morphology and function in the intestine provide a more important and more intuitive basis for projection and selection of operation strategy. Except for common and short-types of HD, exiting methods for diagnosis of IND type B are not always satisfaction,[19] especially for patients complicated with HDAD. Biopsy for the total intestinal wall is the gold standard for diagnosis of IND type B,[20] but in practice, it is unrealistic or at least needs discussion. Sometimes it is very difficult to diagnose IND type B depending on preoperative biopsy or intra-operative rapid frozen section.[21] However, for patients suspected with HD, there will be one-third or more of them were complicated with HDAD.[22] The diagnosis and choice of treatment methods for this sort of patient would be difficult. Eleven cases in this group who had already been subjected to tests such as barium enema, fiber endoscopic or anorectal manometry, were suspected of HD or HDAD were not confirmed by rectal biopsy and mucous membrane acetylcholinesterase determination. While the entire gastrointestinal barium meal combined with multi-temporal abdominal films discovered that barium was retained in the ileocecus and ascending colon for more than 24 hours and in the transverse colon for more than 48 hours, combined with barium enema, they were diagnosed directly with HDAD in accordance with diagnostic criteria of HDAD. In these cases, the rectal biopsy was not necessary.[23] These facts explain the importance of entire gastrointestinal barium meal combined with multi-temporal abdominal films in diagnosis of IND type B.

Six cases in this group could not be diagnosed with IND type B according to the gastrointestinal barium meal test combined with multi-temporal abdominal

films. This kind of constipation always have a bearing on internal rectal prolapse, mixed hemorrhoids, anal fissure, anal vein dilation, encysted rectum, perineal puborectalis relaxation, retardation of puborectalis, redundant colon and so on, usually could be improved by conservative therapy.[24] By the means of entire gastrointestinal barium meal, the risks related to surgical treatment and complications were avoided.

In recent years, many papers on slow transit constipation were published in China, but most of them were ambiguous with deficiency of correct histological classification. Due to the lack of a clear understanding of the actual extent of lesions, unsuccessful surgical treatments can hardly be avoided.[25] After painful frustrations, surgeries almost reached consensus that slow transit mainly distributed beyond transverse colon, and the best surgical strategy for slow transit constipation was sub-total-colectomy and descending colon-rectum anastomosis (the best location of anastomotic stoma was at lower segment rectum), or total-colectomy and ileum-rectal anastomosis (the best location of anastomotic stoma was at middle of the rectum).[26] This strategy was in accordance with the predilection site and principle treatment of IND type B. Due to the characteristics of catholicity and time phase, entire gastrointestinal barium meal combined with multi-temporal abdominal films has the advantage of being able to test the gastrointestinal transfer capabilities and to find physiological and pathological changes simultaneously. It could help to understand the extent of lesions more comprehensively, provide important proof for the diagnosis of the patients with IND type B; at least, it could be a supplement in diagnosis for those difficult to diagnose. On the other hand, it could provide substantial help for the choice of surgical strategy. This method was significant for the patients possibly complicated with HDAD, or in the investigation of total alimentary HD and HDAD.

This paper reported our experience on the diagnosis of patients with IND type B, but the limitation was that it was single central experience; the next stage of this study would be the application for a clinical trial, asking for cooperation from other centers and looking for more evidence to form a consensus for the diagnosis of IND type B.

Acknowledgment. *Gratitude should be given to Xiangyang Central Hospital, Hubei Province, China for assistance in finishing the subject research by providing scientific funds and to Dr. Wanbi Wang, Department of Radiology, Xiangyang Central Hospital of Hubei Province, China for assistance in the x-ray diagnosis.*

References

1. Montedonico S, Acevedo S, Fadda B. Clinical aspects of intestinal neuronal dysplasia. ***J Pediatr Surg*** 2002; 37: 1772-1774.
2. Kapur RP. Neuronal dysplasia: a controversial pathological correlate of intestinal pseudo obstruction. ***Am J Med Genet A*** 2003; 122: 287-293.
3. Puri P. Intestinal neuronal dysplasia. ***Semin Pediatr Surg*** 2003; 12: 259-264.
4. Tomita R, Munakata K, Howard ER, Fujisaki S. Histological studies on Hirschsprung's disease and its allied disorders in childhood. ***Hepatogastroenterology*** 2004; 51: 1042-1044.
5. Peng SS, Lee WT, Hsui WM. An unusual cause of abdominal distension in a 4-year-old boy. Neuronal intestinal dysplasia. ***Gastroenterology*** 2011; 141: e3-e4
6. Tang ST, Yang Y, Wang GB, Tong QS, Mao YZ, Wang Y, et al. Laparoscopic extensive colectomy with transanal Soave pull-through for intestinal neuronal dysplasia in 17 children. ***World J Pediatr*** 2010; 6: 50-54.
7. Choe EK, Park SH, Park KJ. Colonic pseudo-obstruction with distinct transitional zone in adult constipation patients: pathological analysis and results of surgical treatment. ***Am Surg*** 2011; 77: 736-742.
8. Montedonico S, Cáceres P, Muñoz N, Yáñez H, Ramírez R, Fadda B. Histochemical staining for intestinal dysganglionosis: over 30 years experience with more than 1,500 biopsies. ***Pediatr Surg Int*** 2011; 27: 479-486.
9. Sánchez-Mejías A, Fernández RM, Antiñolo G, Borrego S. A new experimental approach is required in the molecular analysis of intestinal neuronal dysplasiatype B patients. ***Exp Ther Med*** 2010: 1: 999-1003.
10. Grigoleit HG, Grigoleit P. Gastrointestinal clinical pharmacology of peppermint oil. ***Phytomedicine*** 2005; 12: 607-611.
11. Tomita R, Howard ER. Clinical studies on anorectal myectomy for chronically constipated patients with outlet obstruction in childhood. ***Hepatogastroenterology*** 2008; 55: 1600-1605.
12. de Oliveira EP, Burini RC. The impact of physical exercise on the gastrointestinal tract. ***Curr Opin Clin Nutr Metab Care*** 2009; 12: 533-538.
13. Mariani G, Boni G, Barreca M, Bellini M, Fattori B, AlSharif A, et al. Radionuclide gastroesophageal motor studies. ***J Nucl Med*** 2004; 45: 1004-1028.
14. Sharma MP, Bhatia V. Abdominal tuberculosis. ***Indian J Med Res*** 2004; 120: 305-315.
15. Lisi G, Illiceto MT, Rossi C, Broto JM, Jil-Vernet JM, Lelli Chiesa P. Anal canal duplication: a retrospective analysis of 12 cases from two European pediatric surgical departments. ***Pediatr Surg Int*** 2006; 22: 967-973.
16. Kanamori Y, Hashizume K, Sugiyama M, Tomonaga T, Terawaki K, Osawa K. Type B intestinal neuronal dysplasia. ***Pediatr Int*** 2005; 47: 338-340.
17. Keshtgar AS, Ward HC, Clayden GS, de Sousa NM. Investigations for incontinence and constipation after surgery for Hirschsprung's disease in children. ***Pediatr Surg Int*** 2003; 19: 4-8.

18. Schimpl G, Uray E, Ratschek M, Höllwarth ME. Constipation and intestinal neuronal dysplasia type B: a clinical follow-up study. ***J Pediatr Gastroenterol Nutr*** 2004; 38: 308-311.
19. Meier-Ruge WA, Ammann K, Bruder E, Holschneider AM, Schärli AF, Schmittenbecher PP, et al. Updated results on intestinal neuronal dysplasia (IND B). ***Eur J Pediatr Surg*** 2004; 14: 384-391.
20. Meier-Ruge WA, Bruder E, Kapur RP. Intestinal neuronal dysplasia type B: one giant ganglion is not good enough. ***Pediatr Dev Pathol*** 2006; 9: 444-452.
21. Babu MK, Kini U, Das K, Alladi A, D'Cruz AJ. A modified technique for the diagnosis of Hirschsprung disease from rectal biopsies. ***Natl Med J India*** 2003; 16: 245-228.
22. Puri P, Shinkai T. Pathogenesis of Hirschsprung's disease and its variants: recent progress. ***Semin Pediatr Surg*** 2004; 13: 18-24.
23. Pini-Prato A, Martucciello G, Jasonni V. Rectal suction biopsy in the diagnosis of intestinal dysganglionoses: 5-year experience with Solo-RBT in 389 patients. ***J Pediatr Surg*** 2006; 41: 1043-1048.
24. Pennant M, Orlando R, Barton P, Bayliss S, Routh K, Meads C. Prucalopride for the treatment of women with chronic constipation in whom standard laxative regimens have failed to provide adequate relief. ***Health Technol Assess*** 2011; 15 Suppl 1: 43-50.
25. Langer JC. Persistent obstructive symptoms after surgery for Hirschsprung's disease: development of a diagnostic and therapeutic algorithm. ***J Pediatr Surg*** 2004; 39: 1458-1462.
26. Han EC, Oh HK, Ha HK, Choe EK, Moon SH, Ryoo SB, et al. Favorable surgical treatment outcomes for chronic constipation with features of colonic pseudo-obstruction. ***World J Gastroenterol*** 2012; 18: 4441-4446.

Related Articles

Abu-Daff NS, Abu-Daff SN, Rubayaan A, Abu-Shaaban A. Laparoscopy in the treatment of a giant true epiphrenic diverticulum with migration of the gastrointestinal anastomosis staples. ***Saudi Med J*** 2011; 32: 1127-1132.

Venkatraman B, Rehman HA, Abdul-Wahab A.High resolution computed tomography appearances of late sequelae of barium aspiration in an asymptomatic young child. ***Saudi Med J*** 2005; 26: 665-667.

Abdul-Rahman MM, Al-Waali MM, Al-Naaimi AS. Analysis of small bowel tumors. ***Saudi Med J*** 2004; 25: 1900-1905.